

**Article XI.—THE SKULL OF *ZIPHIUS CAVIROSTRIS***

BY JOHN D. KERNAN

PLATES XX TO XXXII

For the opportunity of making this study of the skull of *Ziphius*, I am indebted to the authorities of The American Museum of Natural History. My heartfelt thanks are due also to Professor H. von W. Schulte, of the Department of Anatomy of Columbia University, for much valuable advice and assistance.

As is known, Cuvier was the first to describe the skull of this animal, to which he gave the name of *Ziphius cavirostris*. At the time, he was under the impression that he was describing a fossil skull. This error was later corrected by Gervais, who, in 1850, identified a fresh skull, found that year, as of the same species as the original type specimen. Since that time numerous descriptions have been published by European, American, and Australian observers. The skulls serving as material for the various papers have been assigned to nearly as many species as they number. The tendency, as the material became better known, has been to reduce the number of species. European authorities early agreed that there was but one. True, writing in 1910 with a large amount of material at his disposal, came to the same conclusion. According to him, the differences found in the several specimens were only such as could be accounted for by the variations in age and sex. The question of species, therefore, will not be touched upon by me.

The two skulls in my possession, one disarticulated, lend themselves especially to a study of the individual bones, the character of their articulations, and their relations to the cranial cavity.

Accordingly, I shall endeavor to take up, for the most part, only these points. Comparisons with skulls elsewhere described will not be made although the literature will be cited as far as possible, enabling anyone interested to make them for himself.

The smaller of the two skulls, American Museum Collection No. 80016, is that of a foetus at term, sex unknown. Its measurements are given in the table with those of the older skull. It is easily disarticulated, allowing study of each bone by itself.

The older skull, American Museum Collection No. 80015, is that of a young adult female. As we should expect, it possesses those marks given

by True as distinguishing the female skull namely: small prenarial depression and slight mesistrostral ossification.

*Table of Measurements*

	Large	Small
Total length of skull	854 mm.	435 mm.
Length of rostrum	475	215
Height from vertex to inferior border of pterygoids	420	200
Length from tip of rostrum to post border of pterygoids	680	310
Length from tip of rostrum to anterior end of nasals	655	300
Breadth between centers of orbits	440	200
Breadth between zygomas	462	240
Breadth between temporal fossæ	275	
Breadth of rostrum at base	290	90
Breadth of rostrum at middle	108	49
Breadth of premaxillæ at middle of same	57	24
Depth of rostrum at middle	66	24
Breadth of premaxillæ at front of nares	157	67
Greatest breadth of anterior nares	62	27
Length of temporal fossæ	130	
Breadth of temporal fossæ	70	
Length of orbit	110	64
Length from anterior end of orbit to maxillary notch	85	35
Length of tympanic bulla	53	50
Breadth of tympanic bulla	40	40
Length of mandible		36.5
Length of symphysis		75
Depth of mandible at coronoid		75

#### NORMA VERTICALIS

We may conveniently accept the two regions usually described in connection with this skull, the rostral and the cranial.

Three areas can be distinguished on the dorsum of the rostrum: a central depressed area, the mesorostral gutter, flanked on either side by elevations which taper distally.

The mesorostral gutter extends the full length of the rostrum. Its distal one-third is made up entirely by the premaxillæ. These bones meet mesally at the depth of the floor in a linear suture. They spread laterad on either side, and then extend dorsad to form the concave walls of the groove ending above in sharp overhanging margins. At the junction of the distal and mesal thirds of the rostrum, the vomer appears in the floor of the mesorostral gutter, thrusting a sharp apex between the premaxillæ. From this point caudad, the vomer takes up an increasingly extensive area in the

floor of the groove and eventually gains a position in the walls. It articulates on each side with the corresponding premaxilla, the surfaces of the bones passing smoothly into one another. This articulation between vomer and premaxillæ has its caudal limit at the premaxillary foramina. From this point to the mesethmoid, which limits the groove caudally, slender processes of the maxillæ appear in the wall between the vomer and the premaxillæ.

The floor, then, of the mesorostral gutter is made up distally by the premaxillæ, proximally by the vomer. The walls are formed distally by the premaxillæ, proximally by the maxillæ and vomer.

It has been mentioned above that the dorsal margins of the mesorostral groove are formed by sharp, overhanging edges of the premaxillæ. These are practically parallel from the tip of the rostrum as far caudad as the premaxillary foramina. Thence caudad the right premaxilla expands mesad to the extent that its border crosses the midline and closely approaches the left bone. From this point the two continue their course toward the nasal cavities, still having a sinistral inclination. In this region the mesorostral groove is roofed in, chiefly by the right premaxilla. It should be particularly noted that the mesethmoid does not rise to the level of the premaxillæ. Therefore, in the absence of the cartilage the nares communicate freely with one another and the mesorostral groove dorsorostrad to the mesethmoid. This condition is considerably altered in the adult skull.

The lateral elevated regions of this surface of the rostrum are constituted entirely by the maxillæ and premaxillæ. At its extremity and thence a short distance caudad only, the premaxillæ appear. The maxillæ then join them on each side and eventually make up the greater part of the surface, since they grow broader approaching the base; whereas the premaxillæ retain a nearly uniform breadth. The broad base of the rostrum is due to the great lateral expansion of the maxillæ. Between maxilla and premaxilla is formed a linear suture which lies at the bottom of a shallow concavity originating in the reciprocal inclination of the dorsal surfaces of the two bones. This groove leads caudad to a large maxillary foramen which transmits vessels and branches of the fifth cranial nerve. It then expands, to become continuous with the great facial fossa.

The borders of this region are both well-marked. The mesal corresponds to that sharp margin of the premaxilla which overhangs the mesorostral gutter. The lateral is excavated its whole length by an alveolar gutter, which is continuous from premaxilla to maxilla. As the maxilla begins to expand it shows on its margin a prominence, called the maxillary tuberosity, rostrad to which is a depression, the antorbital notch.

Inspection of the adult skull shows in this region a number of marked

differences from the foetal. The component bones are, as might be expected, already synostosed, though the sutures are not yet wholly obliterated. The rostrum shows a more elegant outline, tapering more gradually from base to apex. This may be the effect of a loss in the foetal skull of a certain amount of the tips of the premaxillæ which are not perfect. On the other hand, the rostrum may show, in its shorter and heavier appearance, the effect of sex, as this is characteristic of the male as contrasted with the female, assuming the foetal skull to be that of a male. In the adult, the maxillary tuberosities are more prominent, the antorbital notches deeper, and the antorbital expansion more marked.

The bottom of the mesorostral gutter is occupied by a fusiform crest of bone which has its distal limit at the extremity of the vomer and reaches caudad almost to the mesethmoid. Each extremity is a low, sharp ridge which rises out of the surface of the vomer. In the middle of its course the process forms a broad mass which attains almost the level of the premaxillæ. At the sides it nowhere extends beyond the limits of the vomer and it appears to have no relation to any other bone, so that, as far as the mesorostral ossification in this skull is concerned, it has come from the vomer, not from the mesethmoid (Berardius), nor the premaxillæ (Forbes), nor the prefrontals (Owen).

In skulls of adult males of *Ziphius* the mesethmoid ossification is much more extensive than in this female. It fills the mesorostral groove from the tip almost to the base, rendering the rostrum very massive and powerful.

The cranial portion of the skull is quadrilateral in form. Its rostral limit is the line already mentioned. Its caudal limit is at the foramen magnum. It is bisected by the great transverse crest of the skull.

Rostral to the transverse crest we may describe a mesal and two lateral areas.

The mesal region is somewhat elevated, as a whole, and markedly so at its lateral margins. Passing caudad, it rises to an almost vertical position. On each side is the expanded dorsal surface of the premaxilla, that of the right much broader. The left is completely occupied by a longitudinal groove, missing in the right bone and its lateral margin is elevated to such an extent as to cause the surface to be almost vertical. Between these two surfaces is a large, single, narial opening, deep in the recesses of which can be seen the rough dorsal border of the mesethmoid. The narial opening is overhung caudad by the apices of the conjoined nasal bones, together forming a triangular pyramid which, morticed between the summits of the premaxillæ, rests its base against the frontals. The smooth triangular dorsal surface of the two nasal bones forms the summit of the skull.

The lateral areas are occupied by the great facial fossæ made up exclu-



sively of the dorsal surfaces of the maxillæ. The lateral limits are the borders of the maxillæ. The mesal limits are afforded by the premaxillæ, which here rise to a higher level, and by the facial crests of the maxillæ themselves, which appear near the dorsal tip of the fossæ. These areas are deeply concave in both transverse and longitudinal extensions, the concavity being more marked in the adult. Rostrally, there is a broad ridge which runs rostrocaudad from the maxillary prominence. A large canal, which joins the infraorbital system, opens near the center. Mesal to the maxillary prominence, the large infraorbital canal has its opening.

Comparison shows that these regions of the central elevated section in the cranium are much the same in the two skulls, though slight differences may be noted. The facial fossa, owing to the greater prominence of the maxillary tuberosities and the thickening of the bodies of the premaxillæ, are much deeper in the adult. Also, the transverse ridge occupies a more vertical position, since the maxillæ and the premaxillæ turn dorsad more sharply. In this, the foetal skull resembles other odontocetes, such as *Mesoplodon*, and the adult skull is more specialized. In the transverse ridge itself the suture between frontals and supraoccipital is obliterated with advance in age. That between the maxilla and frontals still persists. The nasals present a quadrilateral rather than a triangular outline on their upper aspect, the portion overhanging the nares being less sharply angulated. Caudad to the transverse crest, there are no changes to be noted except the closure of the fontanelles.

The mesethmoid ossification in the older animal has extended rostrad to the level of the maxillary foramina where it fills the mesorostral groove, appearing in the gap between the premaxillæ. Thus there is no communication of the nares and mesorostral groove, as found in the younger skull. From this extremity of the mesethmoid there is continued caudad a sharp crest of bone which rises to a thickened protuberance at the rostral border of the nares. Thence a sharp concave margin, the upper edge of the septum, sweeps ventrad, then dorsad, to reach the salient suture of the nasal bones, which forms with it a continuous line. The whole sharp ridge, from the point where it leaves the mesethmoid to its junction with the internasal crest, appears to be formed by a growth dorsad and rostrad of the lateral wings of the mesethmoid, which are designated "ectethmoids" in the description of that bone. It is to be noted that the septum gains sufficient height by the formation of this ridge to completely separate the bony nostrils.

The great transverse crest of the skull has for its main support the continuous line of the frontals, which extend dorsad from their orbital processes to meet in the midline. This central core is reinforced both rostrally and caudally. On the rostral aspect, the maxillæ extend as a thin border almost

to the midline. Between them, the right premaxilla and the solid buttress of the nasals rest against the frontals. The caudal support is afforded by the parietals at the sides and the supraoccipital mesally. In all probability, the parietals extend much closer to the midline than the disarticulated bones indicate. The mesal part of the parietals, however, adheres rather to the supraoccipital than to the parietals and can hardly be separated therefrom.

The significance of the differences between the foetal and the adult skull lies in this, that the most marked peculiarities appear to be postnatal effects. Thus the deep interlocking between the maxillæ and the frontals, which serves to secure the rostrum to the cranium, becomes much more marked with age. Moreover, the transverse crest, which may be conceived of as the result of the pressure of the vertebral column overcoming the resistance of the water as the animal swims, is very much more prominent in the adult, showing that this resistance acts after birth to compress the skull caudo-rostrally.

#### NORMA BASALIS

The distal extremity of the rostrum is made up entirely by the premaxillæ. They articulate with one another in the midline, and are limited laterad by the oblique maxillo-premaxillary sutures. Caudad, they separate to allow a slender process of the vomer to appear and the caudal termination of each is a pointed projection which lies between vomer mesad and maxilla laterad. The slender surface of the vomer, which appears between the premaxillæ, is continued caudad between the maxillæ till shut off by the meeting of those bones in the midline.

The maxillæ appear extensively in this region. They reach toward the tip of the rostrum pointed extensions which between them enclose the premaxillæ. Thence their surface broadens until they spread the whole breadth of the rostrum. Caudad to this area, they are overlain by the palate bones, which in turn support the pterygoids. The mesal borders take an oblique course toward the midline, resting successively on premaxillæ, vomer, and opposite maxillæ. At the caudal extremity of the intermaxillary suture, a small area of the vomer appears.

The lateral borders of the maxillæ establish the margins of the rostrum and have already been described. Beneath each maxillary tuberosity a shallow canal gives passage to the facial nerve. The surfaces of each premaxilla and maxilla are marked by a continuous furrow which deepens caudad and finally disappears beneath the overlying palate bone. This furrow marks the course of the posterior palatine canal.

The palate bones present, at the base of the rostrum, hook-shaped areas

which turn about the rostral tips of the pterygoids. In the foetal skull, they reach only slightly mesal to the pterygoids. In the adult, on the contrary, they attain almost the midline and touch the vomer. Their lateral region lies between the pterygoid mesad, which rests upon it, and the maxilla and lachrymal laterad, which it in turn overlies, the three being arranged like shingles. The caudal extremity is a thick, concave margin which surrounds the rostral end of the sphenomaxillary fossa.

Caudad to the rostrum, it is convenient to recognize mesal and lateral areas. In the mesal are the pterygoid shelf, the posterior nares, and the base of the skull. In the lateral areas are the orbits, pterygoid fossæ, temporal arches, glenoid fossæ, otic and paraoccipital regions.

In the midline the pterygoids form an elevated ledge which has a surface continuous with that of the rostrum anteriorly, but terminates in a sharp margin posteriorly where it forms the ventral circumference of the nares. This surface rostrad presents a reentrant angle in the midline. Caudad, it becomes level transversely and extends laterad on the ventrad aspect of each hamular process. The posterior naris is a single opening bordered ventrad by the pterygoids, dorsad by the smoothly concave terminal sheet of the vomer, and on each side by the deeply notched pterygoid. Caudad to the posterior nares is a deeply concave area, limited on each side by the basioccipital processes of the basioccipital which represents the base of the cranium formed by the basioccipital and basisphenoid. In the foetal skull, the exoccipital and basioccipital are not yet united, whereas in the adult the component parts of the occipital region have completely synostosed.

The orbit, as far as the bony structures are concerned, has merely a roof, unless, indeed, the slender shaft of the jugal can be considered as representing the floor. The roof most anteriorly, is formed by a narrow rim of the jugal, that portion of the ventral surface caudad to the origin of the zygomatic process. Succeeding this is the triangular, slightly concave surface of the lachrymal, placed with its tip mesad, its base laterad. The surface of this bone is marked by a groove which terminates in a blind canal leading toward the nasal cavity, though not reaching it. It is much less distinguishable in the adult skull than in the foetal. The frontal completes the orbital roof with a broad concave surface which dips under the ala orbitalis mesad, forms the entire rim of the orbit laterad, and is continuous with the ventral surface of the anti- and postorbital processes. This surface is demarcated by an elevated margin from the temporal fossa. As stated above, the bony walls and floor of the orbit have here disappeared. Of the structures forming them in the ordinary mammalian skull, the maxillary tuberosity and orbital plate of the ethmoid are entirely lacking. The lachrymal, which appears prominently in the inner wall of the orbit in many

mammals, has shifted to the roof, as has the jugal, which ordinarily assists in forming the lower portion of the rim. Moreover, owing to the loss of the inner wall of the orbit, the lachrymal and the pterygoid, ordinarily widely separated, are here in contact.

The cause of these variations from the conditions found in mammals is the suppression of the ethmoidal region of the nasal passages. This is easily to be understood when it is recalled that the maxilla owes its large expansion in the floor of the orbit to the invasion of its substance by an ethmoidal cell, and that the orbital plate is the ectal wall of the ethmoidal labyrinth.

At the junction of the orbital roof and the lateral surface of the pterygoid is an oblong recess the circumference of which is formed by the lachrymal and frontal dorsad, the palate rostrad, the frontal caudad and the pterygoid ventrad. In the mesal wall of this recess appears most caudally the tip of the ala orbitalis, perforated by the optic foramen. Ventrad to the tip of the ala orbitalis is a space bounded below by the pterygoid. This slit-like space gives passage to the nerves of the orbit and to the maxillary nerve.

Rostrad to the tip of the ala orbitalis, the area under description has for its mesal wall pterygoid and palate. This portion corresponds to the sphenomaxillary fossa of the human skull. From it leads rostrad a large canal for the maxillary nerve and artery, mesad a double canal to the nasal cavity, the sphenopalatine, and laterad a large canal which opens in the facial fossa. In the adult skull, owing to a dorsal extension of the border of the pterygoid, the region of the ala orbitalis appears shut off from the sphenomaxillary fossa. Mesal to the upward extension still lies a passage for the maxillary nerve. In the foetal skull the tip of the ala orbitalis is seen in the inner wall of the fossa only. On the other hand, in the adult it has undergone lateral growth and appears in the roof of the orbit dorsal to the pterygoid.

The pterygoid fossa occupies the entire lateral surface of the pterygoid bone. It is triangular, deepest ventrad and bifurcated caudally, owing to the notch in the caudal border of the bone. In the adult skull the dorso-caudal angle is considerably extended by the further growth of the bone in this direction, almost concealing the ala temporalis which in the younger skull is largely exposed.

The temporal arch is formed by the zygomatic process of the squamosal and the postorbital process of the frontal. The remainder of the lower boundary of the temporal fossa is made up of frontal and squamosal, respectively craniad and caudad, and the parietal and lateral border of the ala temporalis mesad. Ventrad to the temporal arch, as described above, the slender shaft of the jugal, reaching almost to the pregenoid process\*of

the squamosal, forms a second arch laterad to the temporal muscle, the zygomatic.

The glenoid fossa is described in connection with the os squamosum. It is essentially the same in foetal and in adult skulls, except for the greater massiveness of the bone in the latter.

The otic region comprises an area bounded mesad by the caudal end of the pterygoid and the basioccipital process of the basioccipital, laterad by the mesal border of the glenoid fossa and the paraoccipital process of the exoccipital, and craniad by the caudal border of the ala temporalis. It undergoes such considerable changes in growth as to merit close examination. In the foetal skull, between glenoid and pterygoid fossæ, a quadrilateral area of the ala temporalis is exposed. In the adult skull this is almost completely covered in by extension toward one another of the shelving edges of pterygoid and squamosum. Beneath the thin edge of the pterygoid are three openings which in the younger skull are entirely exposed. The one of these nearest the midline is that for the internal carotid artery. In the adult, merely its entrance beneath pterygoid is visible, this bone covering the opening into basisphenoid. Mesad to this opening, the pterygoid overlaps the basioccipital process of the basioccipital to a considerable degree. Laterad to the carotid opening, the pterygoid stretches caudad and actually establishes contact with the squamosum. Beneath this margin, small canals pass craniad, ventral to the root of the ala temporalis. One of these serves for the passage of the great superficial petrosal nerve. Succeeding to the point of contact of pterygoid and squamosum, just mentioned, there is a marked recession of the pterygoid border giving access to the foramen ovale. Laterad to this, the pterygoid and squamosum are again almost in contact, only a narrow strip of the ala temporalis intervening.

Examination of the younger skull shows, caudad to the ala temporalis, a large opening into the interior of the skull. The anterior portion of this opening is a deep notch in the caudal border of the alisphenoid, constituting the foramen ovale.

The posterior portion is a common opening for the cranial nerves from the seventh to the eleventh, and the jugular foramen. The larger part is occupied by the periotic, which in the young skull thus has access to the ental aspect of the skull. Its bed is formed laterad by squamosal and exoccipital, mesad by basioccipital.

In the adult skull the opening described, except for canals for the nerves, has been filled in. This had been brought about by the caudad growth of both commissura alii cochlearis and ala temporalis. The two meet and thus separate the foramen ovale from the common opening. A process

from the exoccipital extends mesad to reach the commissura ali cochlearis and divides off the canal for the seventh and the eighth nerves from that for the ninth, tenth, and eleventh caudad to it. The result of this development of bone is that the periotic is entirely shut out from the skull cavity. Into the roof of its bed enter processes from commissura ali cochlearis, ala temporalis and exoccipital. As it lies in position, it is partially overlapped laterally by a shelf of the squamosal, the processes falciformis, and held in position by a slender, crescentic process of that bone which springs from the rostral tip of that process.

The paracondyloid process in the younger skull reaches the same ventral level as the basal process of the basioccipital, from which it is separated by a deep notch at the bottom of which is the hypoglossal foramen. The exoccipital process of the squamosal fits smoothly against its cranial border. In the adult skull, this process is greatly thickened and stands out in such a manner as to lead to the formation of a notch between it and the paracondyloid process. Into this notch fits a rather massive piece of bone, the tympanomastoid, which fills it and rounds out the contour of the paracondyloid region. The tympanomastoid is also present in the young skull but only slightly developed.

#### NORMA LATERALIS

This view reveals especially well the manner in which the rostrum is braced against vertical strains. This is accomplished by buttresses both above and below the longitudinal axis. The first is chiefly made up of the massive premaxillæ which reach to the transverse cranial crest. The second, lighter than the first, is composed of the pterygoids which fill the gap between the base of the rostrum and the basioccipital processes of the basioccipital.

The lateral aspect of the rostrum is formed, to a great extent, by the maxilla, though the distal section shows only the premaxilla, which rises above the former nearly its whole length disappearing as the caudal extremity is approached. The margin of these two bones show a continuous alveolar gutter, much more distant in the smaller skull, as it is filled with porous bone in the adult. The articulation of palate and maxilla, and pterygoid and palate, are well seen at the rostral base. There are no essential differences between the two skulls in respect to these structures. An excellent view of the pterygoid is gained from this direction.

The prominence of the maxillary tuberosities in the older skull should be especially noted. It is the enlargement of these which forms the most distinguishing mark of the *Hyperoodon* skull and *Ziphius* is the nearest to

*Hyperoodon* in this respect of the ziphioids. The greatly increased depth of the facial fossa brought about by age will at once be noted.

The frontal is tripartite on this aspect, showing preorbital and postorbital and ascending processes. Behind the ascending branch of the frontal, the deep temporal fossa and, in its depth, the squamoparietal suture are seen. This suture is much more irregular in the grown skull. The squamosum shows three divisions: squamous, glenoid, and exoccipital. The latter is, in the young skull, a thin hook-like process; on the other hand, much more massive in the old, wherein it assists in forming a notch for the reception of the tympanomastoid. Between the glenoid and exoccipital processes is a well-marked notch for the passage of the external auditory meatus.

#### NORMA OCCIPITALIS

On occipital view the skull takes the form of a massive arch which supports itself on the tympanomastoid and paraoccipital processes. The inner contour of the arch is formed by the basioccipital processes of the basioccipital, united across the midline by the body of that bone. In the space outlined by these structures is seen the posterior nares, walled rostrad by the pterygoids. Laterad to the nares are the pterygoid notches. In the center of the arch, close to the ventral margin, is the foramen magnum. This opening is circular except for the presence of two projecting nodules of bone along the dorsal border.

On either side of the foramen magnum are the condyles. These are semielliptical masses of bone placed with their long axes passing lateromesad and ventrad. Their lateral margins are markedly convex; their mesal margins, slightly concave. In the foetal skull, a raised area on the basioccipital, only slightly demarcated from those portions of the condyles born on the exoccipitals, joins them into a single horseshoe-shaped articular surface. This is of interest as the same condition is found in the chondrocrania of certain other mammals (*Talpa*; E. Fischer). All trace of the central area has disappeared in the adult.

Dorsad to the foramen magnum, a vertical crest leads nearly to the summit of the skull. This is joined on either side, near its termination, by crescentic lines which lead to the margin of the temporal fossa. These lines bound slightly depressed areas for the attachment of muscles.

The circumference of the arch marks the outline dorsally of the great transverse crest of the cranium. Midway along the outer border, a great gap in the contour appears, which marks the site of the temporal fossa. This is bridged over by the frontal bone and its postorbital process. Ventrad

to the temporal fossa, massive projections on either side are formed by the squamosals and their zygomatic processes. From their apices, the bone falls away to the level of the paracondyloid processes. Three bones are involved in the formation of the pedestals of the arch described. Rostrad is the exoccipital process of the squamosal. Caudad appears the massive paraoccipital process of the exoccipital. The deep notch which lies between the extremities of these two is filled in by the tympanomastoid. This process, small and flattened in the young skull, becomes massive and rough in the adult.

#### INTERIOR OF THE SKULL

*Cranial Floor.*—The floor of the cranial cavity is distinguished by its great proportional breadth. To bring this about, structures ordinarily found in the side wall of the mammalian skull, as in man, have been turned down into a horizontal position. There is, in addition, an actual caudo-rostral shortening, owing to the almost complete suppression of the anterior cranial fossa. Those parts which in the human skull form the floor of this fossa, the mesethmoid, cribriform plate, and the orbital plates of the frontals, are in the skull of *Ziphius* transferred to the rostral wall. Of the structures ordinarily found there, only the alæ orbitales remain in the floor.

The main mass of the cranial base is made up of the fused basioccipital and basisphenoid, which occupy the midline. The basioccipital is wedged-shaped caudally, its apex reaching the foramen magnum. On either side of it are narrow ledges of the exoccipitals, which here have a horizontal position. Immediately rostrad, it occupies the full width of the cranial floor, its body being extended to each side by the basal processes. It should be noted that the basioccipital occupies fully half of the caudo-rostral extension.

In the sphenoidal region, the width established caudally is fully maintained by the basisphenoid, to which are fused, on each side, the processes alares and their caudal prolongations, the processes alæ cochleares. Laterad to these still is a large gap which represents the confluent posterior and middle lacerated foramina.

Rostrad to a line drawn through the carotid foramina, the transverse measurement receives an increase by the addition of the alisphenoids. These structures spread out laterad and all the region mesad to the groove for the middle meningeal artery lies in the base of the skull. Laterad to the groove mentioned, they are overlain by a sheet of the parietal.

The presphenoid and the alæ orbitales, the latter separated from the alisphenoids by the sphenoidal fissure, complete the cranial base rostrad.



Contrary to the condition found in most mammals, the basioccipital slopes dorsoventrad for a considerable distance rostrad to the foramen magnum. This is owing to the fact that a great part of the bone here develops in an epichordal position. The sloping area is succeeded by a horizontal portion to which follows the short upward rise of the presphenoid. Thus the cranial floor is concave caudorostrad. Transversely, it is horizontal throughout.

In the occipital region, on either side, can be seen the ental openings of the hypoglossal foramina. Further craniad, in the midline, is the orifice of a small canal which passes completely through the bone, bifurcating ectad so as to present two opening places, one to each side of the midline. A considerable portion of the occipital region and the whole basisphenoidal region are bordered by the confluent lacerated foramina. These can be seen to be divided into three by two paired protrusions from the lateral and mesal borders. They transmit, in addition to large vessels, the vagus group of cranial nerves, the seventh and eighth, and the inferior maxillary branch of the fifth nerve. The secondary opening for the seventh and eighth nerves is peculiar, among mammals, to cetacea. The closure of lacerated foramina in the adult has already been described in connection with the norma basalis.

The dorsum sellæ is a scarcely distinguishable ridge. The sella turcica is a very shallow fossa. In its concavity is the ental orifice of the hypophysial canal which still completely perforates the bone. In the same transverse plane as this, laterad to it, are the carotid foramina with grooves leading from them rostromesad. The intersphenoidal suture is still rather widely open. It is separated from the sphenoidal fissure on each side by only a small bar of bone.

The groove for the optic chiasm is narrow, but of unusual lateral extension, owing to the great width of the alæ hypochiasmaticæ.

*Caudal Wall of the Cranial Cavity.*— The caudal wall of the cranial cavity is formed by the exoccipitals in conjunction with the supraoccipital. There are three openings in this wall. In the midline, ventrally, is the hexagonal foramen magnum. In the circumference of this lie (above) the exoccipital, (below) the basioccipital, and (to either side) the exoccipitals. Dorsolateral to the foramen magnum are the paired lateral occipital fontanelles. These are bounded by the exoccipital, supraoccipital, and, rostrad, by the parietal bones. The foramen magnum is framed by an arched ridge, described in connection with the separate bones, which gives attachment to the tentorium. From its summit extends a great median crest which is formed through ossification of the falx cerebri. The ridges and the crest should be particularly noted, as they have much to do with reinforcing the skull against anteroposterior pressure. They bound broad shallow fossæ which lodge cerebellum and the occipital lobes of the cerebrum.

*Anterior Wall of the Cranial Cavity.*—The rostral wall of the skull is, in the main, composed of the great vertical sheet of the frontal bones. Each presents a uniformly concave, semicircular surface with a curved dorso-lateral and sinuous ventromesal margin, which rises lateromesad. The two surfaces meet mesally to form a narrow isthmus and the frontal fontanelle ventrad. These two bones are like a pair of saddle bags joined by their strap. The great notch which lies between them is partially filled in by the mesethmoid and structures closely related thereto, and may be said to be homologous to the ethmoidal notch of the human skull. It will be noted, however, that this opening extends far beyond what may be considered the limits of the ethmoidal notch, and is better designated as the frontal fontanelle.

In the adult skull, as may be ascertained by inspection through the foramen magnum, the frontal fontanelle and the ethmoidal notch are completely filled in by a smooth surfaced sheet of bone. Two small openings are present, canals which open by three mouths in the nasal passages. These are for the nasal branches of the fifth nerve.

Laterally the frontals extend to the ventral limit of the wall a rather broad process which articulates with the tip of the alisphenoid. Mesal to this, the border of each presents a deep notch which receives the tip of the ala orbitalis. Proceeding mesad are seen small areas of the pterygoids, then the extremities of the sphenoidal turbinates overlapped by a second salient of the frontal margins. The mid-space is occupied by the mesethmoid, which rises vertically and is flanked by the ectethmoids.

Between the sphenoidal turbinate and the ala orbitalis is a fissure which represents the posterior ethmoidal foramen of the human skull. On each side of the mesethmoid is a small fissure which may allow passage for the nasal nerves from the cranial cavity to the nasal passages.

Ventrad to the mesethmoid and ectethmoids, a narrow strip of pre-sphenoid is turned dorsad and forms the ventral limit of the wall in this region.

The notable thing in connection with this wall of the skull is the presence in it of pterygoids, sphenoidal turbinates, mesethmoid, and ectethmoids. These are all structures which in other mammalian skulls appear in the floor of the anterior fossa. The impulse for their shift from the floor to the rostral wall undoubtedly comes from the suppression of the ethmoidal region of the nasal cavities and the turning dorsad of their external orifices.

*Lateral Wall of the Cranial Cavity.*—The lateral wall of the cranial cavity is formed, in the main, by one bone, the considerably compressed parietal. This is a most striking indication of the great caudorostrad compression of the skull. Caudally, a small portion of the exoccipital appears. Rostrally,

the side wall ends at the parietofrontal suture. The tip of the lateral occipital fontanelle appears above the exoccipital in the notch between it and the parietal. Dorsal to the parietal, the supraoccipital completes the side wall. On the ectal aspect of the parietal lies the squamosal, completely shut out of the cranial cavity. It aids in reinforcing this wall against pressure. Another structure ordinarily found in the side wall of the mammalian skull, the alisphenoid, has been, as I have mentioned, transferred to the floor, so that two structures added to the reptilian brain-case to form that of the mammal are secondarily shifted in this highly developed mammal, one entirely out of the brain-case, the other to the floor.

The impulse to the broadening of the brain-case is probably to be found in the suppression of the ethmoidal region. This leads to the disappearance of the anterior cranial fossa and a consequent compression of the brain caudorostrad, which forces it to seek lateral expansion.

#### NASAL PASSAGES

The nasal passages take a crescentic course from the anterior to the posterior nares, the convexity of the curve being rostrad. The external orifice is much deflected to the left; whereas the internal is perfectly symmetrical.

The anterior nares in the younger skull form a single orifice, owing to the incompleteness of the mesethmoidal ossification and the absence of the cartilage. In the fully developed skull, the nares are separated almost to the level of the premaxilla by a sharp dorsal margin of the nasal septum formed by the upward growth of the vomer and ectethmoids. In both young and old, the lateral boundaries of nasal openings are formed by the premaxilla and, in both, the nasal bones overhang them caudally. The septum in either skull is made up of the mesethmoid with an encasement of vomer and ectethmoid. In the young skull, this encasement is only partial; in the fully developed skull, on the other hand, the encasement is complete, as already described.

The outer wall of each nasal passage is formed ectoentad by premaxilla, a broad surface of maxilla, a narrow strip of palate and then by a section of pterygoid as broad as the others taken together. These elements are distinct in the young skull but completely amalgamated in the older and their boundaries can not be distinguished.

The rostral wall is established by the turn mesad of the maxillæ, palates, and the pterygoids to meet the septum. Ventrad to the level of the septum, in the common nasopharyngeal passage, the rostral wall is made up entirely by the pterygoids meeting in the midline.

The caudal wall differs considerably in the two skulls. In both, the nasals appear overhanging the external orifices. In the young skull, ventrad to the nasals, is a large gap which allows free communication between the nasal cavities and the interior of the cranium. This is homologous, in part at least, to the ethmoidal notch of the human frontal bone. Laterad to the notch, a roughened margin of the frontal bone appears in the wall. Ventrad to the notch, the ectethmoidal plates and the sphenoidal turbinates are present, and, finally, the horizontal sheet of the vomer. In the adult skull, except for certain openings to be mentioned later, the whole caudal wall of each nasal passage appears as a smooth sheet of bone. This is doubtless brought about by the fusing of vomer, sphenoidal turbinate, and ectethmoid and by their dorsal extension concomitant with the upward growth of the septum. It is probable that the frontal also helps to fill in the gap of the frontal fontanelle, so that finally the nasal cavity is separated from brain cavity by a double layer of bone, the frontal composing one layer, and the fused vomer, sphenoidal turbinal, and ectethmoid the second.

The terminal portion of the narial passages is undivided and approaches the horizontal in direction. The roof is formed by the horizontal portion of the vomer and a small strip of each pterygoid. Outer wall and floor are formed by the pterygoids.

Through the outer wall of each nasal passage, two small canals lead to the sphenomaxillary fossa. These are the sphenopalatine openings and they are found alike in both skulls. One is entirely enclosed in the palate bone; the other lies between palatè and lachrymal ectally, and palate and tip of sphenoidal turbinate entally.

It has been mentioned that the large frontal fontanelle communicating with the brain cavity in the young skull is closed in the adult. At the site of this orifice, three small canals may be seen in the adult skull. They have a common opening entally and transmit the nasal branches of the ophthalmic. In this same region is a structure not present in the foetal skull, a crescent of bone secured by its tips to the dorsal wall and so forming a projecting loop. This may be a vestigial turbinate.

Three classes of forces may be thought of as acting upon the skull of cetaceans: water pressure; the vertical and lateral twists and strains upon the prolonged rostrum; and those incident to propulsion, due to the resistance of the water in front and the thrust of the vertebral column upon the condyles behind.

Response to water pressure takes the form of a general thickening of the cranial walls. This is most manifest where the bones are most directly exposed to the pressure along the transverse crest, and at the extremities of that structure. On the other hand, in the basal region, where the overlying

soft parts are thick, the bone has a tendency to be thinner. In the occipital region, however, the ridges which mark the ental surfaces of the bones undoubtedly are reinforcements against compression.

For convenience, the skull of *Ziphius* has been described as consisting of the rostrum and the cranium proper, the line of division being drawn tangent to the rostral borders of the maxillary tuberosities. It is well to note, however, that structurally such a division is arbitrary. The rostrum expands at its base in both the vertical and the transverse diameters. The transverse expansion, effected by the broadening of the maxillæ, reaches its extreme in the region of the maxillary tuberosities, so that their rostral borders, indeed, furnish a valid line of demarcation between rostrum and cranium in the transverse plane. On the other hand, the vertical expansion, formed on the dorsal aspect of the skull by the premaxillæ, on the ventral aspect by the broad pterygoids, extends much further caudad to the occipital region. Thus, in this plane, it is difficult to settle on a point where the rostrum ends and cranium begins.

The former is, in reality, merely the apical portion of a pyramidal mass which rests its base against a ring formed by the supraoccipitalis, parietals, and the basisphenoid. The junction of the occipital ring and the base of the rostrum results in the formation of the great transverse crest of the cranium. From the crest, both caudad and rostrad, the bone falls away toward the foramen magnum on the one hand and rostrum on the other, so establishing the caudal and rostral walls of the cranial cavity. It is the wide expansion of the rostrum at its base which results, in spite of the great length of the structure, in the firmest security against all manner of strains.

In the vertical plane, forces are transmitted from the rostrum to the occipital ring chiefly through the frontal portions of the premaxillæ. The chief strength is not gained through direct contact, for only the right premaxilla reaches the crest of the frontal and that by a narrow process. Between the premaxillæ and the frontals are interpolated the massive nasal bones, and it is by them that thrusts are in the main supported. The surfaces of contact between nasals and premaxillæ are broad and the articulations very firm.

In union with the premaxillæ, the maxillæ also turn dorsad and reach the transverse crest. This portion of the maxilla, however, is merely a thin sheet of bone and can contribute no great strength in this direction.

On the ventral aspect of the skull, the lines of the transmission of force lie through the pterygoids. These bones have a broad articulation with the base of the rostrum, chiefly with the palates which are interposed between them and the maxillæ. They form, also, a small direct articulation with the maxillæ and have a very slight contact with the vomer. The union,

then, is one of great strength. Caudally, the pterygoids reach the bases of the basioccipital processes in the occipital region.

The ventral brace thus formed is much less firm than the dorsal, since the pterygoids are less massive than the premaxillæ and the structure of the bone is less dense. Moreover, dorsal strains are transmitted through a continuous line of bone, whereas the ventral strains must pass through three articulations. We may conclude then that strains in this direction are not so severe as those in the opposite. However, in the adult skull, provision for greater firmness is made by the growth laterad of the borders of the pterygoids, which thus secure a very firm hold on the base of the skull.

Lateral strains are provided against by the expansion of the base of the rostrum in the transverse plane. This is effected, as already stated, by the spreading out of the maxillæ. Through them, forces reach the occipital ring along two lines. One is an inner, along the lateral cranial wall, formed chiefly by the parietals, which articulate directly with the exoccipitals. There is, in addition, an outer line of transmission through the postorbital processes of the frontals to the jugal processes of the squamosals and hence to the exoccipitals. That the lines of greatest strain lie through the lateral margins of the bones is at once evident from their formation. Mesally, both the maxillæ and the frontals are thin sheets which lie in contact and form a firm articulation preventing displacements, indeed, but offering no great resistance to compression. Their lateral margins, on the other hand, are thicker. The frontals form the massive orbital processes. These thrust forward strong preorbital processes which are locked to the maxillæ by the lachrymals. Lighter postorbital processes reach the jugal processes of the squamosals, which interlock with the exoccipitals.

Additional security is given to the rostrum by the character of the articulations of the bones forming it with those of the cranium. On the dorsal aspect, the chief of these is that between maxilla and frontal. Both of these bones expand into broad sheets, deeply concave rostrally, the maxilla fitting into the concavity of the frontal. The premaxillæ fit over the mesal margins of the maxillæ and secure this border to the nasal and frontal.

On the ventral aspect, the pterygoid has a broad contact with the base of the rostrum and spreads over the base of the cranium to the basioccipital.

Two characteristics, then, distinguish these articulations: their breadth and a certain amount of interlocking.

The response to the forces incident to propulsion manifests itself in the formation of the great transverse crest of the skull. The condyles lie above the plane of the cranial base. Consequently forces acting through them would tend to compress the vertex of the skull, provided there were at the same time firm resistance from in front, such as the water provides when the

animal is swimming; hence the compression of the dorsal areas of the frontal and parietal bones and the piling up of the supraoccipital on the one hand, and the premaxillæ, the maxillæ, and frontals on the other, into the transverse crest.

This structure is the central architectural feature of the ziphioid skull. It consists of massive lateral piers connected by a more slender arch. The manner in which the rostrum braces itself against the lateral piers and crest of the arch has already been described. The resistance of the water is undoubtedly transmitted to the transverse crest along the same lines as the forces which tend to twist and bend the rostrum.

It remains to examine the manner in which the thrusts upon the condyles are transmitted to the transverse crest. Upon the ental surface of the occipital region, three ridges are seen to meet at a point just dorsal to the foramen magnum. The dorsal of these is single and extends to the apex of the transverse crest. The ventral are paired and symmetrical. Their distal extremities terminate in the lateral masses already described, so that the portions of the transverse crest supporting the greatest strains from the rostrum are the very ones to be most strongly reinforced from behind.

Forces are likewise transmitted from the condyles through the basioccipital processes along the line of the pterygoids to the rostrum. These ventral lines of transmission are slighter than the dorsal and are of less importance, as would be expected from the dorsal position of the condyles.

#### BONES OF THE ROSTRUM

The bones entering into the formation of the rostrum are the maxillæ, the premaxillæ, the vomer, pterygoids, and the palates. The main mass is composed of the three first mentioned, the two latter pair lying in the base on the ventral aspect.

*The Maxillæ.*—The maxillæ, owing to the marked sinistral deviation of the nasal passages at their external orifices, are asymmetrical. In the rostral region, the right bone is broader and more massive; in the frontal, it is of greater breadth and more marked curvature, with more extensive articular surfaces. The rostral portion has three surfaces. The dorsal of these has been sufficiently described in connection with the dorsum of the rostrum. The lateral surface appears largely on the venter of the rostrum. A portion near the base, it will be remembered, is covered by the palate and pterygoid. Between the articular area and the border of the bone, a small furrow leads over the lateral border, affording passage to the facial vessels and nerve. The articular surface is grooved by the posterior palatine canal.

The mesal surface presents a series of depressions separated by ridges. The most dorsal of the ridges is a round margin, more prominent in the left bone, which lies along the line of the articulation with the premaxilla. Distally, on the left side, it is interrupted by a groove which leads into the premaxillary canal. On the right side, the border itself is complete, the groove being replaced by a canal which burrows under it.

Immediately ventrad to the marginal ridge is the articular surface for the premaxilla, which extends the whole length of the bone. The caudal two-thirds is concave. The rostral one-third is divided by a longitudinal crest, which marks the surface relief of the alveolar gutter. This crest fits into a depression of the premaxilla. Dorsal and ventral to it are longitudinal concavities which receive corresponding elevations of the opposing bone, the two thus firmly interlocking.

The premaxillary surface is limited below by a high, sharp ridge which juts out at a right angle. This is designated as the vomerine shelf. It leaves the center of the border of the bone at an acute angle and is continued caudad as the mesal margin of the frontal portion. Its shelf-like character is more marked on the right bone. Ventral to this ledge, the articular area for the vomer occupies a triangular space with its apex at the center of the ventral border, its base at the caudal limit of the rostrum. It is deeply concave, owing to limiting crests dorsad and ventrad. The surface aspect is longitudinally striated and grooved by furrows which form canals in the articulated state.

The inferior border of the maxilla at its apex is smooth and rounded. Passing caudad, it becomes an exceedingly sharp margin which so closely embraces the vomer as to make the suture difficult to ascertain. Caudally, this crest is continued on to the ventral surface of the frontal portion, gradually becoming lower.

As it joins the cranium, the maxilla lies at first vertical with its surfaces facing mesad and laterad. Passing caudad, the bone rotates on a longitudinal axis and undergoes that great transverse broadening to which the expansion of the rostral base is due. The horizontal sheet then curls upward till it becomes vertical and enters into the rostral face of the skull. The border which embraces the external circumference of the frontal sheet begins rostrally at the maxillary tuberosity. From this point, a rough margin encloses nearly the half of a circle and meets the internal border at the dorsal limit of the premaxillary articulation. The internal margin which joins the ends of the half circle is a continuation of the vomerine shelf. Near its dorsal termination, it becomes lower and is replaced by a high ridge which rolls laterad, designated as the facial crest. Over the convexity of this crest fits the premaxilla to form an interlocking articula-



tion. The surface thus delimited appears on the dorsorostral wall of the cranium and is sufficiently described in connection with that region.

The caudoventral surface of the frontal sheet has the same borders as those described for the rostradorsal. It presents also a like change in its plane, the most rostral portion facing laterad, the caudal portion caudo-ventrad.

The vertical portion of the surface is largely taken up by the articular surface for the palate. It is grooved centrally for the posterior palatine canal. Its lower margin is continued on to the caudoventral surface of the body as a ridge which unites with the margin of the vomerine crest. Mesal to this ridge, the ventral surface of the vomerine crest presents itself with a rough area rostrally for articulation with the mesorostral cartilage. Caudal to this, clearly demarcated from it, is a broad, smooth surface which forms part of the rostral wall of the nasal fossa.

Lateral to the dividing ridge, three bones articulate with the crescent-shaped surface. Rostrally at the tip of the crescent is a small triangular area for the jugal. Caudal to this is a lozenge-shaped area for the lachrymal. These two are scarcely delimited one from the other. They are overlapped mesally by a sharp ledge passing from the maxillary prominence to the lateral aspect of the infraorbital canal. The surface for the lachrymal is grooved for a canal, completed by the articulation which leads from the rostradorsal surface to the infraorbital foramen.

The remainder of this surface articulates with the frontal. It is, in the main, smooth but presents shallow grooves for vessels which are completed canals in the articulated state.

*The Premaxillæ.*—The premaxillæ present to an even greater degree the asymmetry of the maxillæ. The rostral processes are much the same on the two sides. Of the bodies, however, the right is broader and shows more extensive surfaces of articulation. Indeed, it may be said that it is in the flaring of the mesal border of the right premaxilla that the deviation of the nares to the left is most clearly expressed.

The lateral surface of the rostral process is divided by a high ridge into articular and non-articular areas. This ridge is the external relief of a canal passing the full length of the interior of the bone. Ventral thereto, there is a deep longitudinal depression bounded below in its turn by a marginal crest. The depression receives an elevation of the maxilla about which the ridges lock. Dorsal to the articular surface is a smooth elongated area which appears on the dorsal surface of the rostrum.

The mesal surface of the rostral process of the premaxilla presents a smooth concave surface with elevated margins. Of these, the upper is free. The lower, for the caudal three-fourths of its extent, articulates with the

vomer. For the proximal one-fourth, it articulates with its fellow on the opposite side. By these articulations is formed a smooth-walled, broad furrow on the dorsal aspect of the rostrum, the mesorostral gutter which has been described in connection with the dorsum of the rostrum.

The upper border of the vomerine gutter is a sharp, free edge which delimits it from dorsal aspect of the rostrum. Caudally, this margin divides to form the borders of the dorsal surface of the frontal portion of the bone.

The ventral border of the premaxillary rostral area is, in reality, a broad surface, being the ventral aspect of the marginal crest of the lateral surface. Rostrally, this surface is free and appears on the ventral face of the rostrum. Caudally, the whole surface, narrow here, articulates with the dorsum of the vomerine shelf of the maxilla and with the margin of the vomer.

*Frontal Portion of the Premaxilla.*—The distal limit of the dorsal surface of the frontal portion of the premaxilla may be placed at the premaxillary foramen. The dorsal border splits just rostrad of it and embraces a narrow concave surface, in the depth of which is the canal. The remainder of the surface on the right side is broad, smooth, and concave rostrocaudally. The mesal margin deviates widely to the left and, at its middle, is produced into a tubercle which is in close relation, in the foetal skull, with the mesethmoid ridge. In the adult, it forms a short articulation with the mesethmoid and, for the rest of its extent, presents a gently concave margin overhanging the nasal fossa.

The lateral margin is sinuous, convex rostrally and caudally with a concave area between. It is sharp for its rostral one-fourth and overhangs the maxillary articulations. Its caudal three-fourths broadens into a narrow surface which limits mesally the great frontal fossa of the maxilla.

The dorsal surface of the left premaxilla is much narrower than that of the right. It is delimited by elevated margins which render the surface concave transversely as well as rostrocaudally. The borders meet again as they approach the dorsal tip, the surface being thus replaced in the dorsal one-fourth of the process by a sharp crest. The mesal border, in contrast to that of the right bone, deviates laterad, sharing the displacement of the nasal fossa, and is concave in its general formation — the tubercle, so prominent on the mesal border of the right bone, being only slightly indicated. It has the same relations to the rostral gutter, mesethmoid, and nasal fossa as the corresponding border of the right bone, though its articulation with the mesethmoid is more extensive.

The ventral surface of the frontal portion of the right premaxilla is convex in its general conformation. Rostrally, it is marked by a high axial ridge, the prolonged lower border of the rostral region which fits into the

vomerine shelf of the maxilla. Caudally, this ridge splits into two elevations which later becoming more prominent can be traced to the caudal limit of the bone. A small area near the mesal border rostrally articulates with the mesethmoid. Caudad to this is a smooth surface which enters into the wall of the nasal passage. Owing to the marked mesal projections of the margin, this nasal surface on the right side forms part of the mesal roof as well as of the outer wall. The caudal extensions of the low ridges above mentioned limit a longitudinal depression which embraces the facial crest of the maxilla. All the articular areas are rough and furrowed for vessels. The ventral surface of the body of the left premaxilla differs from that of the right bone only in being much narrower. The axial ridge fits closely into a deep furrow formed by the vomerine crest of the maxilla, security of articulation being secured in this case rather by depth of interlocking than by breadth of contact. The nasal surface does not overhang the nasal passage and so forms only an outer wall, not a roof, for that structure.

In the adult, both bones appear to have increased more in dorsoventral extent than transversely. Thus the surfaces appearing in the nasal passages and frontal fossæ are much greater proportionately than in the foetal skull. Regarded as a whole, the frontal portion of the right bone appears triangular on cross-section with surfaces appearing in nasal passage, frontal fossa, and on the dorsum of the skull. The corresponding portion of the left bone appears as a vertical sheet with surfaces facing mesad in the nasal passage and laterad in the frontal fossa. The dorsal surface, so prominent on the right side, is comparatively insignificant. The two divisions of the bone appear to have different relations to each other on the two sides. On the right side, the frontal portion lies in the same longitudinal axis as the rostral. On the left side, the axis of the frontal portion shifts laterad and so forms a blunt angle with the axis of the rostral. This deviation of axis is owing to the encroachment of nasal passages on the left.

*The Vomer.*—The vomer, resting its expanded base against the ventral surface of the cranium and extending its pointed apex to within two inches of the tip of the rostrum, forms the central stem of that structure. The dorsal surface, concave and of smooth aspect, makes up a considerable part of the rostral groove. The ventral surface, convex throughout its extent, presents an axial ridge. This becomes high and sharp caudally and terminates in a spur which demarcates the rostral from the narial region. Both near its tip between the maxillæ and near its caudal termination between the pterygoids, the ridge appears on the ventral surface of the rostrum. The surface on either side is entirely overlain by the neighboring bones — for the greater part by the maxillæ. Near the caudal extremity are small areas for the palates and pterygoids. The surface of each maxilla wherewith the

vomer articulates is deeply concave, terminating above in the vomerine shelf and below in a strongly salient border. Thus it is firmly locked in its place and binds the maxillæ together and them in turn to the base of the skull.

At its caudal extremity, the vomer expands in such a manner as to form a broad sheet of bone concave transversely owing to the turning downward of the lateral margins. This sheet by its dorsal surface has an extensive articulation with the base of the cranium. Its caudal edge reaches the basioccipital. Its lateral borders overlap margins of the pterygoids and secure them to the skull. The ventral surface assists largely in the formation of the nasal cavities.

On either side of the mesethmoid there extend upward from the cranial edge of the vomerine plate flat strips of bone which reach the vertical height of the alæ orbitales. They incline laterad as they pass upward and lie along the lateral margins of the ectethmoid with which they tend to fuse. Their lateral borders override, rostrad, the mesal edge of the pterygoids and are in turn overlapped by the palate. The dorsal margin passes rostrad to the ventral edge of the frontal. These processes have a concave nasal surface which in union with the pterygoid forms the caudal wall of the nasal passage. Their convex caudal surface in part lies against the sphenoid and in part faces the cranial cavity. The position of these processes suggests that they are homologous to the sphenoidal turbinates of the mammalian skull.

*The Pterygoid.*—The pterygoid extends from the base of the rostrum to the cranial margin of the basal process of the basioccipital affording a powerful brace to the ventral aspect of the cranium. The bone is quadrilateral in shape, having two long rostral and two short caudal borders, one of the latter interrupted by a wide indentation. The lateral surface shows an extensive shallow fossa deep in the ventral and dorsal regions — less so centrally, owing to the presence of a wide convexity. The circumferential depressions are caused chiefly by the elevation into sharp ridges of all the borders. The central convexity is the external expression of the cylindrical nasal passage of which the bone in this region forms the lateral wall.

The mesal surface is divided by ridges into two articular areas and a nasal. The ridges greatly increase the thickness of the bone and give a corresponding increase in strength. The first is really the prominent ventral border. It is high and wide at its summit and bent at an obtuse angle near its rostral extremity. The portion rostrad to the angle articulates with the ventral ridge of the vomer. The remaining portion of the ridge meets the opposite pterygoid in the articulated condition, forming a median longitudinal suture in the rostral wall of the nasopharyngeal passage. The

second longitudinal ridge lies near the dorsal border. It is high and sharp at its summit, broad at its base, and its course presents a convexity ventrally. This ridge fits into a fissure between the lateral margin of the vomer, on the one hand, and the presphenoid, on the other. Its cranial extremity tends to become vertical in direction and bears on its summit a cup-shaped cavity for articulation with the lachrymal.

The third ridge is vertical in direction and connects the cranial ends of those already described. Though low in the greater part of its course, its dorsal extremity becomes elevated and bounds mesad a recession which receives a protuberance of the palate.

The first articular area lies craniad to the third ridge. It is triangular, smooth, and flat, except dorsad where there is the recession mentioned above. The greater part of the surface articulates with the palate bone. Near the ventral border is a small area for articulation with the maxilla.

The surfaces of the dorsal longitudinal ridge form the second articular area. The ventral has a large area for the vomer and a smaller rostral area for the sphenoidal turbinal. The dorsal surface shows an oblong, centrally placed, concave area for articulation with the ventral surface of the ala hypochiasmatica, and rostral to this a smaller region which, for the most part, articulates with the ala orbitalis but along its mesal border appears in the cranial cavity. At its caudal margin, this surface articulates laterally with the ventral aspect of the ala temporalis, mesally with the basisphenoid. The two areas, that for basisphenoid and that for the ala temporalis, are separated by a groove which allows passage to the great superficial petrosal nerve. The balance of the surface lies close to the ala orbitalis without contact. In the articulated state it forms the lateral wall of a recess ventrolateral to the ala orbitalis leading from the sphenoid fissure to the sphenomaxillary fossa.

The nasal surface is smooth-walled and uniformly concave dorsoventrad. It forms the lateral wall of the nasal passage.

The dorsorostral border is thin. The rostral two-thirds lies along the articulation of the pterygoid and palate. The caudal one-third, at a slightly higher level than the rest, bridges over the space between palate and greater wing of the sphenoid, forming a free edge ventrad to the apex of the orbit.

The ventrorostral border forms a fairly wide, slightly concave surface. Rostrally, where the two pterygoids articulate, they together make up a shallow fossa of considerable width. Caudally, the two surfaces diverge.

The caudoventral border presents two processes, separated by a wide notch. The ventral process, deeply concave laterad, corresponds to the hamular process of other mammals. The dorsal process articulates by its tip with the basal process of the basisphenoid.

The caudodorsal border articulates its full length with the rostral border of the ala temporalis.

There is evidence in the appearance of the pterygoid of two ossification centers. This takes the form of a slight fissure at the center of the pterygoid notch and of shallow grooves lining both surfaces leading rostrad from this notch. These appear to divide the bone into two portions, which join with shelving margins. The one includes the hamular process and the portion articulating with the palate; the other, placed more caudally, articulates with the pre- and basisphenoids. The significance of the double ossification center is hard to determine from the evidence at hand. It may be that the rostral and hamular processes represent the true pterygoid, and the more caudal portion the external pterygoid plate of the basisphenoid. On the other hand, as it is hard to accept an external pterygoid place which ossifies separately from the basisphenoid, it seems best to consider the whole structure as a pterygoid which ossifies from two centers and to find the external pterygoid plate fused to the body of the sphenoid as described in connection with that bone.

*Rostrum.*—Having considered the various elements of the rostrum separately we may now bring out the general principles on which it is built and attached to the cranium.

1. The articulation of the bones among themselves are interlocking. This is shown by the manner in which the alternating ridges and depressions of the maxillæ and premaxillæ fit into one another.
2. Approaching the cranium, the articulations become broad as well as interlocking.
3. The extensive mesorostral ossification in adult and especially in male skulls gives great additional strength to the rostrum.
4. The rostrum is braced against lateral and vertical strains by the great expansion of its base.
5. The vomer assists in uniting the bones of the two sides across the midline, furnishes a center of ossification for the mesethmoid cartilage, and unites the whole rostrum directly to the base of the skull.

*The Lachrymal.*—The lachrymal is a rather massive bone of sufficient breadth and length to form a considerable part of the roof of the orbit. The broader division lies laterad and thrusts its thickened rough margin to the edge of the rostral base, appearing as a border prominence just behind the antorbital notch. The apex reaches the inner recesses of the orbit, where it lies in a cup-like process of the pterygoid close to but not actually in the nasal cavity.

The main mass of the bone is in the shape of a disk. The dorsal surface of this is convex mesad, slightly concave laterad, owing to the elevation of the lateral margin. This concavoconvex surface opposes a depressed

region on the ventral surface of the maxilla which possesses reciprocal elevations and depressions. Along its rostral margin is a crescentic area for articulation with the jugal, which thrusts itself between lachrymal and maxilla.

The ventral surface of this section is, in the main, deeply and uniformly concave. This is the more marked in that the lateral margin is considerably decurved. Along the mesal edge is a smaller area delimited from the general surface by a caudorostral ridge. The rostral portion of this area is overlapped by a ledge, on the ventral surface of the maxilla, which assists in locking the bone firmly in place. A small caudal triangular portion appears in the roof of the orifice of the infraorbital canal. The caudal border of this, again, is overridden by a slight projecting ledge of the palate.

The lateral portion of the circumference of this section is taken up by a narrow groove, which receives the margin of the frontal. The lower edge of this groove is especially prominent and firmly supports the frontal from beneath. The grooved area is succeeded by the rough region already described as appearing beneath the lateral border of the maxilla. The rostral border is contained in the cup-like body of the jugal. The mesal margin lies under a ledge of the maxilla and terminates in a triangular projection which reaches the palate. The caudal border gives rise to the hook-like projection now to be described.

The caudal portion of the lachrymal is separated from the body of the bone by a deep indentation of the mesal margin which effects the formation of a neck. The bone becomes narrow in its transverse measurement, broader vertically, reversing the conditions found in the body. The whole process turns mesad and it terminates in a sharp vertical crest.

The laterocaudal surface is continuous with the grooved lateral margin of the body. It articulates, in part, with the base of the mesal edge of the orbital process of the frontal. Ventrad to this, there is a narrow strip which appears in the circumference of the apex of the orbit.

The mesoventral surface presents, first, a deeply concave area which partially surrounds the mesal opening of the lateral maxillary canal. A small spur on this surface marks off a secondary channel from the main one. Ental to the depressed area is one more elevated. By this surface, the lachrymal articulates in succession dorsoventrad with the maxilla, the palate by slightly interlocking surfaces, and with the pterygoid in a cup-like depression in which it rests its rounded extremity. Between the last two articulations is a furrow which bridges over a channel in the palate.

The dorsal surface is concave and lies against the maxilla, enclosing with it a vascular canal. The ventral surface appears, for the most part, free in the roof of the inner region of the orbit. The tip of this surface joins

the pterygoid in the manner already described. At its lateral limit is the orifice of a canal which penetrates the bone obliquely. This canal appears to be formed by the rolling over of the mesal margin of the bone to meet a similar process arising from the surface. The two enclose a short canal which terminates in a fissure which extends to the apex of the bone. This blind canal and fissure probably represent the lachrymal canal of other mammals.

It has been said that this mesal extension of the lachrymal terminates in a vertical edge. This can be seen from the nasal fossa in a fissure between maxilla, palate, and pterygoid on the one hand, and frontal on the other. In the articulated state, it appears to establish contact with the tip of that dorsal extension of the vomer described as the sphenoidal turbinal. The process as a whole lies in a bed formed for it by the maxilla, palate, pterygoid, and frontal.

*The Jugal.*—The jugal is a small bone possessing a three-sided body and a long slender shaft. The dorsal surface is convex in its transverse diameter and quadrilateral in outline, though the lateral border is so short as to make the surface approach a triangle. This surface articulates with a similarly shaped area on the ventral surface of the maxilla. The lateral border projects beyond the border of the maxilla in the antorbital notch.

The caudal surface is deeply concave in all dimensions and triangular in shape, the base of the triangle being placed laterad, the apex being prolonged into a slender process mesad. This surface fits like a cap over the convex cranial surface of the lachrymal bone, the slender process mentioned being received into a deep depression between lachrymal and maxilla.

The ventral surface is irregularly triangular in outline, the apex of the triangle being formed by that slender process which fits in between lachrymal and maxilla. The surface, where prolonged on this process, is, in the articulated state, overlapped by a ridge of the maxilla. The rest of the surface is free on the ventral surface of the base of the rostrum. From the ventral surface rises by a broad flat base the zygomatic process. This is a round, slender shaft of bone which reaches caudolateral almost to the tip of the jugal process of the frontal.

*Squamosal.*—The squamosal is notable for the massive process which supports the glenoid fossa and zygoma, contrasted with the insignificant plate which lies in the wall of the cranium. This latter is oval in outline, concave on its ental surface and convex ectally. The whole ental surface articulates with a tongue-shaped area on the outer surface of the parietal. The dorsal half of the circumference of this section is very thin and fades into the ectal surface of the cranium. The caudal portion of the ventral half of the border presents a hook-like projection which is received into a recession on the ventral border of the jugular process of the exoccipital.



The rostral portion of the ventral half of the border articulates by means of a wide grooved surface with the lateral border and inferior surface of the processes ascendens of the alisphenoid. Between these two articulations, that with the alisphenoid and that with the exoccipital, the ventral edge of the squamosal plate forms a free edge indented by a deep notch which borders on the foramen lacerum medium and assists in forming the bed of the periotic bone.

The glenoid process is a strong, quadrilateral mass of bone attached by its mesal border to the ectal surface of the squamosal plate. It is placed with its rostral border in a more dorsal plane than the caudal and its surfaces thus face rostroventrad and dorsocaudad. The dorsal surface is, for the greater part of its extent, convex and shows roughening for the attachment of muscles.

The ventral surface forms the glenoid fossa. This is quadrilateral in outline and markedly concave in all dimensions, owing to the decurvation of all the borders, especially the lateral. A well marked zygomatic process terminates the lateral border rostrally and a less massive postglenoid process is present caudally. Between the two, the border is deeply concave. The mesal border falls into two divisions. The rostral forms a thin margin, which is just under the ala temporalis. The caudal division forms a free, concave, sharp margin, which terminates at either end in a point. From the rostral of these springs a crescentic finger-like process, which curls about the anterior mass of the periotic bone. The whole free margin, which is known as the falciform process, in the articulated state lies under the periotic and holds it firmly in place.

The surface of the glenoid fossa is smooth rostrally but rough approaching the caudal border, possibly to afford attachment to the articular cartilage.

A third process juts caudad from the junction of the squamosal and glenoid portions of the squamous bone, giving it a triradiate appearance on lateral view. This is a pyramidal, hook-like structure which fills in the space between the glenoid mass and the exoccipital. Its ectal surface is continuous with those of the squamosal plate and glenoid process. Its ental surface assists in forming the lateral wall of the periotic bed. Its third surface articulates with the exoccipital.

This process becomes greatly thickened in the adult skull and forms, with the exoccipital, a notch which receives the tympanomastoid. Between it and the caudal edge of the glenoid process is a distinct groove for the external auditory canal.

*The Palate.*—The palate, a flat scale of bone, is placed at the base of the rostrum on the lateral surface of the maxilla. Two portions may be distinguished: an anterior, thin and broad, which lies compressed between

maxilla and pterygoid; and a posterior, massive and irregular, set at an angle to the first.

The lateral surface of the anterior portion shows a dorsal region, flat and smooth, which appears on the ventral surface of the rostrum, extending a little cranial to the pterygoid. Ventrad to this, separated from it by a ridge, is a broader portion, longitudinally striated, which in the articulated skull is overlain by the pterygoid. The mesal surface of this division is opposed in almost its entire extent to the ectal surface of the maxilla. The caudal extremity of the ventral border, however, forms a small projecting spur which overrides the maxilla and articulates with the vomer. The midline of this surface is marked by a groove for the posterior palatine canal.

The caudal portion of the bone, though narrow, is much thicker than the rostral and forms an angle therewith, changing direction mesad to fit the convexity of the maxilla. The dorsal border at the junction of the two sections shows a deep, smooth-edged groove which forms the inferior margin of the proximal opening of the maxillary foramen. Caudad to this is a thin, tongue-like projection, with a concave ectal surface, which lies in the inner wall of the lateral maxillary foramen. The extremity of the process presents a sharp edge, which overrides rostrad and excludes the tip of the sphenoidal turbinal from the nasal fossa.

The ventral margin of the caudal process of the palate is a sharp crest which fits into a groove on the inner surface of the pterygoid, aiding to form a firm union with that bone. The mesal margin is also prominent and fits under a ledge on the ventrocaudal surface of the maxilla. Three surfaces are included between these borders. The ectal shows a small area rostrad in a gap between lachrymal and pterygoid which lies in the floor of the sphenomaxillary fossa. This section is grooved by a canal which comes through the bone from the nasal passage, probably the sphenopalatine canal. A second canal formed between lachrymal and palate bone, divided from the one already mentioned by a thin partition, also enters this space from the nasal fossa. The remaining caudal portion of this surface is divided between a dorsal smaller area for articulation with the lachrymal and a larger ventral area for articulation with the pterygoid.

The mesal surface is smooth, concave rostrocaudally, narrow, and forms a portion of the lateral wall of the nasal passage, appearing between maxilla and pterygoid. The dorsal surface shows several longitudinal elevations and depressions which correspond to irregularities of the maxillary surface with which it articulates.

## BONES OF THE FLOOR OF THE CRANIUM

*Basioccipital*.—The basioccipital presents for description a body and paired basal processes.

The body forms the floor of the posterior fossa of the skull. It is divisible into two portions, a cranial quadrilateral area which is firmly fused to the basisphenoid and bears on its lateral borders the basioccipital processes, and a caudal triangular area. This latter portion lies with its base cranial and apex caudad on the foramen magnum, firmly wedged between the exoccipitals. It is demarcated from the former by lateral notches which suggest a previous complete separation.

The ental surface of the body, owing to the elevation of its borders is concave in all directions. Low marginal ridges serve to delimit it from the basisphenoid and basal processes, the superficial aspect of the bones being homogeneous. Near the apex of the triangular portion, bordering on the foramen magnum, there is a slight falling away of the surface, rendering this portion convex.

The ectal surface of the body is flat longitudinally and deeply concave transversely, owing to the extension ventrad of the basal processes. The caudal half of the triangular portion is roughened and divided into central and lateral areas by parallel, longitudinal fissures. The lateral areas, in the articulated state, form part of the surfaces of the condyles for articulation with the atlas. The central area, of which there is no indication in the adult, appears to form part of the general articular area and strongly suggests that in the young of this animal there may be a single horseshoe-shaped joint which becomes divided in later life.

As concerns the borders of the basioccipital, the cranial, as mentioned above, is firmly fused to the basisphenoid. The lateral borders give origin for their cranial one-third to the basioccipital processes. The caudal two-thirds present a wide roughened area for articulation with the exoccipital.

The basioccipital processes arise from the anterior one-third of each margin of the basioccipital, a low broad ridge on the dorsum marking the point of origin. Laterad to the ridge, there is a slight falling away of the surface. This section of the bone is narrow and almost directly horizontal. An inch from its origin the process turns ventrad, at the same time undergoing a considerable anteroposterior expansion. There is thus formed a vertical plate of bone, the surfaces of which, owing to rotation on a vertical axis, present laterocranial and mesocaudal.

A transverse fissure separates the horizontal portion of the process from the caudal edge of the alisphenoid. At the point where the process bends

ventrad, the fissure turns over the lateral border of the skull base between alisphenoid and basioccipital processes. After a short extension downward, it passes forward and inward between the ectopterygoid ridge of the basisphenoid and the cranial extension of the basal process. Thus the latter process presents the appearance of a sickle, the handle joining the basioccipital, the blade hooking forward and inward around the ectopterygoid ridge. The fissures do not extend through the bone to the ventral aspect, so that this view does not show the limits of the structures mentioned.

The dorsal surface of the horizontal portion of the basal process is marked by a prominent transverse ridge. In the articulated state, this extends towards a similar protrusion on the ental surface of the exoccipital, the two partially dividing the foramen lacerum into caudal and cranial divisions.

The cranial border of the basal process lies against the inner portion of the alisphenoid, the line being marked, as above described, by a fissure. The vertical plate has a dorsal border, hooking about the ectopterygoid, and a caudal border, which articulates in nearly its whole extent with the exoccipital. Near the tip, this border is free and is separated from the paracondyloid process of the exoccipital by a deep notch at the bottom of which opens the hypoglossal foramen.

In the articulated skull, the basal processes form a considerable portion of the paired, great longitudinal ridges which extend from the base of the rostrum cranially to the exoccipitals, caudally fitting between pterygoids and the paracondyloid processes of the exoccipitals.

*The Sphenoid.*—The sphenoid consists of a central portion, the basisphenoid and paired lateral processes, the alisphenoids.

The basisphenoid is a quadrilateral mass of bone which lies in the floor of the middle fossa of the skull. Caudally, it is firmly fused to the basioccipital. Cranially, fusion with the presphenoid has not yet occurred. The alisphenoids are firmly attached to the lateral borders of the body, though careful examination reveals certain lines of demarcation.

The ental surface of the body shows a well-marked transverse ridge, which may be identified as the dorsum sellæ. Anterior to this ridge is a shallow depression corresponding to the sella turcica of other mammals. The floor of this fossa is perforated by a small canal which reaches the ventral surface of the bone, evidently the canal for the hypophyseal stalk. Craniad to the sella, the surface of the bone is elevated in the midline by a rough ridge which mounts to an elevated margin along the border of the bone. On each side of the central ridge, the bone is longitudinally grooved by channels for the internal carotid arteries.

The ventral surface of the basisphenoid is concave transversely. In the midline can be seen the inferior opening of the hypophyseal canal.

The caudal border of the basisphenoid is fused, without line of demarcation, to the basioccipital. The cranial border presents a rough quadrilateral area, longest transversely, which articulates with the presphenoid. To the lateral margins are united the alisphenoids.

The alisphenoids consist of two portions: a mesal, which is in close relation to the body; and a lateral, or processus ascendens. The mesal, or processus alaris, is an oblong block of bone united by one long border to the basisphenoid. The line of union is marked at the junction of the middle and anterior thirds by the carotid foramen, which penetrates the bone from the ectal surface craniomesad. Grooves proceed both craniad and caudad from the foramen. The cranial of these reaches the anterior border of the bone and is evidently the external expression of the fissure which shows on the cross section and almost separates basi- from alisphenoid though not reaching the surface. The caudal of the two grooves leading from the carotid foramen reaches halfway to the posterior border, where it ends in a small excavation seemingly the remains of a canal which at one time deeply penetrated the bone. Both these grooves are probably occupied by vessels.

The fissure delimiting the basioccipital process from the alisphenoid has been described. At the point where it turns over the margin of the bone, an additional fissure branches from it. This passes forward, gradually increasing its distance from the former until it reaches the ectal opening of the carotid canal. The two fissures include between them a narrow, triangular strip of bone which lies with its base on the basisphenoid rostrad to the cranial margin of the basal process of the basioccipital. This portion of bone I take to represent the ectopterygoid process of the basisphenoid.

The dorsal surface of the processus alaris, craniad to the carotid foramen, is flat and passes smoothly on to the surface of the basisphenoid. Caudad to the carotid foramen, the surface becomes high and convex, owing to the presence of a prominent tubercle on the lateral border to be described later. The ventral surface is rough and convex longitudinally.

The cranial border of the processus alaris is short and articulates with a process from the presphenoid. The caudal border rests against the basal process of the basisphenoid. The union of the mesal border to the basisphenoid has been described. The lateral border demands more extended mention. Cranially, it gives origin to the processus ascendens. The line union is marked by a dorsal groove which leads from a notch in the caudal edge of the root of the processus. Caudad to this notch, the border juts laterad to form a prominent tubercle which in its turn is limited caudad by another deep recession. This latter borders on the foramen lacerum and is included in the caudal division of that opening. The tubercle helps to

separate the foramen lacerum posterior from the region of the foramen lacerum medium.

The processus ascendens takes origin from the anterolateral angle of the processus alaris by a narrow, flattened bar of bone. This passes for a short distance laterocranially, and then expands into a thick, quadrilateral block. The upper surface of this mass is marked mesally by a groove which probably provides passage for the middle meningeal vessel. Laterad to the groove is a broad smooth area which, in the articulated skull, is overlain by a process of the parietal bone. Cranially, there is a narrow, fissured area for articulation with the frontal bone.

The ventral surface is divided by a well-marked groove into a rostral smooth area, which borders on the sphenoidal fissure, and a caudal roughened area, which articulates in its whole extent with the squamosal. Laterally, there is a narrow border, which articulates with the frontal bone. The groove is for the third branch of the fifth cranial nerve.

The anteromesal border of this section is smooth and sharp, and bounds on the sphenoidal fissure. The anterolateral border is sharp and wedged-shaped for articulation with the frontal. The posterolateral border is divided into two narrow longitudinal strips, the ventral of which articulates with the squamosal, the dorsal with the parietal bone. The posteromesal lies on the foramen lacerum. It presents two indentations, a lateral for the middle meningeal vessel and a mesal for the third division of the fifth nerve.

#### BONES OF THE BRAIN CASE

*The Supraoccipital.*—The supraoccipital enters into the formation of a considerable part of the caudal wall and roof of the cranial vault. Its borders are exceedingly irregular. Lying on the foramen magnum is a short, concave area occupying one-fourth of the circumference of that opening. This margin is thin and sharp. On either side of the foraminal area the bone becomes thicker and presents on cross section a fairly broad, semi-oval articular surface for the exoccipital. This portion becomes narrow laterad and is succeeded by an exceedingly thick indented area which borders on the lateral occipital fontanelle. For the remaining half of the distance to the lateral angle of the bone the margin is rough and is dissimilar on the two sides, owing to irregularity of the disarticulation. Close examination shows that the parietals jut under the supraoccipital to a considerable extent and have, in a varying degree, remained attached to that bone.

From the lateral to the cranial angle there is a smoothly concave border of gradually increasing width which is slightly striated. This articulates

with the frontal. In the midline is an area, in length one-fifth the breadth of the bone, which is straight transversely. This is delimited from the concave section on each side by an angle. The surface here is of considerable width and deeply concave in all dimensions. Each half of this area receives a prominence on the border of the corresponding frontal, firm union being thus secured.

It has been mentioned that a considerable portion of the parietal on each side, overridden by the supraoccipital, has remained attached to this latter. Along the border, from the lateral to the cranial angle, there is a very narrow margin of bone which seems separated from the supraoccipital by a shallow fissure on the ectal surface and to belong with the parietals. In the midline, also, a considerable section of the supraoccipital crest is partially delimited by fissures from both supraoccipital and parietals. These fissures appear to indicate previous complete separation and so the presence of parietals reaching almost the midline and the presence of an interparietal between them.

The ectal surface shows a central depressed area passing caudocranially, taking in the whole width of the bone at the caudal angle. This corresponds to the supraoccipital crest on the ental surface. On either side of the central concavity is an elevated, uniform convexity, the external indication of the internal hollows which receive the cerebral lobes.

The ental surface is marked by a high supraoccipital crest with a deep uniform concavity on either side. This supraoccipital crest passes cranio-caudad from the cranial angle of the bone to within a short distance of the inferior angle. Here it bifurcates and the two resulting crests pass laterad to the center of the broad articular areas for the exoccipitals. These latter are continuations of similar crests on the ental surface of the exoccipitals and furnish attachment to the tentorium. The central crest itself is probably due to ossification of the falx cerebri and aids greatly in reinforcing the skull vault against anteroposterior pressure. It has already been mentioned that a considerable portion of the crest, in its most cranial region, is partially marked off from the rest by fissure and the suggestion was made that this area might represent an interparietal bone. This part is further subdivided by a fissure showing on only one side, and so there may be present here pre-interparietals as well as interparietals.

*Exoccipital.*—The exoccipital is roughly quadrilateral in shape, having two mesal and two lateral borders. The bone varies greatly in thickness, being massive at the ventromesal border, thin and shell-like at the dorso-lateral. The ventromesal border presents an extensive articular surface for the basioccipital. This falls into two divisions, separated by an obtuse angulation and a small fissure. The dorsal is the broader of the two, as

the bone is there thickened for the formation of the condyle on the ectal surface. The ventral is of uniform width and slightly concave. The inferior one-third of this area is born on a spur of bone which limits mesally the hypoglossal notch, the outer limit being the paracondyloid process. In the articulated condition this angulated border fits into a corresponding reentrant angle of the basioccipital, the fissure and concavity of the ventral area at the same time receiving a protrusion from the basioccipital. There is thus formed a firm interlocking joint.

The ventral half of the dorsomesal border is concave and sharp and enters into the margin of the foramen magnum. Dorsally, the border turns cranial and forms an articular surface of gradually diminishing breadth for the supraoccipital.

The dorsolateral border is a thin, sharp margin of irregular outline which helps to limit the lateral occipital frontanelle. The ventrolateral border is also thin, of sinuous outline, and protrudes to a slight extent ectally, thus assisting in the formation of a salient ridge at the occipitosquamosal suture.

The ental surface of the exoccipital is exceedingly uneven. From the angle at the centre of the ventromesal border there curves dorsal a well-marked, rounded ridge which meets the dorsomesal border just above the limit of the indentation of the foramen magnum. This is continuous with a similar ridge on the ental surface of the supraoccipital and evidently affords attachment to the tentorium. Caudad to this ridge, the surface of the bone is concave to form part of the posterior fossa for the lodgement of the cerebellum. In this concavity appears the ental opening of the hypoglossal foramen. This canal passes through the bone cranioventrad to its ectal outlet in the hypoglossal notch between basi- and exoccipital. Cranial to the ridge is a triangular concave surface which enters into the side wall of the middle cerebral fossa. This is limited ventrally by a massive projection of bone of triangular base and double apex. The dorsal surface of this mass presents in the cranial cavity. The anterior surface is extra cranial, being covered in the articulated skull by the parietal. Ventral to the surface of the parietal is a deep depression which receives a spur from the squamosal, thus forming a dovetailed articulation.

The ventral surface of the exoccipital spine is extracranial and helps form the bed for the periotic capsule. Of the angles delimiting the surfaces of the pyramid, the dorsal is a smooth even ridge which fades gradually into the surface of the bone. The ventral is rough, broad, and overlain nearly to the apex by a protuberance of the squamosal. The caudal is marked about midway by a sharp spur which gives the pyramid the appearance of having a double apex. This spur projects toward a similar one on the basioccipital and the two almost divide the foramen lacerum posterum



into caudal and cranial divisions. The larger apex reaches toward the commissura alicochlearis of the alisphenoid and with this indicates the cranial limit of the foramen lacerum posterium. The whole mass corresponds to the processus jugularis of other mammalian skulls. Below the jugular process is a smooth concave surface which forms the ventral aspect of the paracondyloid process. This is covered along its lateral margin by the squamosal. The remainder of the surface is free and forms the caudal wall of the periotic bed.

The ectal surface of the exoccipital reveals three elevations separated by a Y-shaped depression. Caudally, at the junction of the mesal surfaces, is a rough, crescentic elevation which forms the larger part of the condylar articular surface of one side. Ventrally, beneath the cranial arm of the Y, is the smooth, convex ectal surface of paracondyloid process. Dorsally, between the arms of the Y, is a low wide elevation which is the external expression of the concavity which lodges the posterior lobe of the cerebrum.

*Frontal.*—The vertical portion of the frontal, in union with its fellow of the opposite side, forms a large part of the rostral wall of the skull cavity. It has the shape of one-quarter of a circular disk, with the straight borders mesad and ventrad. Centrally, the bone is thin and comparatively fragile. The entire circumference is thickened, especially the dorsal and ventral margins. The former of these expands mesally into a massive process which forms, when articulated, the prominent vertex of the cranium and furnishes broad surfaces for articulations. The latter gives rise rostrally to the orbital process and caudally to a thick projection which embraces the tip of the ala orbitalis and articulates with the greater wing of the sphenoid.

The caudal surface is, for the most part, uniformly concave. The dorsomesal angle, however, is occupied by a considerable triangular area, broad mesad, pointed lateral, which is roughened, convex dorsoventrad, and articulates with the supraoccipital. The ventral part of the lateral border also presents a smaller triangular area for articulation with the parietal.

The rostral surface is centrally convex in correspondence to the concavity of the ental surface. In the dorsal and ventral regions, owing to the thickening of the bone, the surface becomes concave. Below, it passes smoothly on to the dorsal surface of the orbital process. Near the lateral border is a narrow strip marked off from the general surface by a shallow groove, above by a low ridge. This represents an area which appears as a free border in the articulated state. The remainder of the surface is opposed to the frontal portion of the maxilla on articulation, the two thus forming a double vertical front wall for the skull. The lateral and dorsal borders take part in the formation of the great transverse crest. The mesal border

is considerably thickened. At the dorsal termination is a triangular area for articulation with the nasal bone. Ventral to this succeeds a smaller surface which meets the frontal bone of the opposite side. The lower half of the border is bevelled at the expense of the rostral surface. This bevelled area presents a thin, sharp edge mesad, which borders on the frontal fontanella. The surface itself is very rough for the attachment of ligaments. The ventral margin, however, furnishes a narrow strip of smoother aspect for articulation with lachrymal, laterad, and pterygoid and sphenoidal turbinal, mesad.

The orbital process is a triangular projection of the rostral aspect of inferior margin of the vertical portion. Its apex points ventromesad and rostrad. The lateral border is continuous with that of the vertical portion and the dorsal surface here presents a narrow strip marked off by a shallow groove. The mesal border is concave, moderately sharp, and articulates for its whole length with the lachrymal, into a depression of which it fits.

The dorsal surface is concave caudorostrad and is covered in the articulated state by the maxilla. The ventral surface is slightly concave in all dimensions, and forms the main part of the roof of the orbit.

The postorbital process rises from the junction of the lateral borders of the vertical and orbital portions. It is a sharp spur which points caudolateral. Its mesal surface is smooth and concave and limits the temporal fossa laterad. The ectal surface is convex and rough.

A thick three-sided protuberance projects caudoventrad from the caudal aspect of the junction of orbital and vertical processes. The upper surface of this structure faces in the cranial cavity. The inferior surface partially roofs in the temporal fossa. The mesal surface is deeply indented by a narrow groove which, in the articulated state, forms the outer extremity of the sphenoidal fissure. Of the borders, the outer presents a narrow articular surface for the parietal continuous with that on the dorsal surface of the vertical division. The caudal border is deeply striated for articulation with the ala temporalis, and the mesal concave margin receives the blunt, lateral extremity of the ala orbitalis. The lower lip of the groove on the mesal surface articulates with the palate.

*Presphenoid.*—The presphenoid, in its extension from basisphenoid to mesethmoid, rises more and more sharply so that it enters not only into the floor of the cranial cavity, but into the anterior wall as well. It is as yet separated from the basisphenoid by an open fissure. The ala orbitalis and mesethmoid are, on the other hand, already firmly united to it and the delimiting lines are with difficulty made out.

The sphenoidal body is a quadrilateral mass of considerable thickness. Its ental surface is uniformly concave in the sagittal axis, the rostral border

being placed at a much higher level than the caudal. Thus the surface as a whole looks dorsocaudad, the rostral region almost directly caudad. The midline is occupied by a low, wide, longitudinal ridge. This is the surface expression of the base of the mesethmoid which is deeply set into the bone from the ventral aspect. Owing to the presence of this ridge, the surface is concavoconvex in its transverse aspect. As a whole, it forms a broad shallow depression for the optic chiasm and laterally the optic nerves.

The ectal surface of the sphenoidal body is markedly convex in all dimensions, bevelling at its expense occurring in the lateral and rostral regions. In the midline, the thick mesethmoid juts rostrad. The lateral regions are, in the articulated condition, concealed from view by the sphenoidal turbinals and vomer mesally and by the pterygoids along the borders.

The rostral margin is sharp and on each side falls away laterad where it demarcates the orbitonasal fissure. In the midline it lies against the mesethmoid and, though the union is close, a transverse line of fusion can be made out.

The caudal border articulates with the basisphenoid. At its lateral limits fissures of considerable depth indicate the original separation of the ala from the body. In the midline, the cross section shows an inverted V-shaped depression which rests its limbs on the ventral margin of the border and extends its apex almost to the dorsal surface. This may be taken to indicate the original separation of the part included in the V, the base of the mesethmoid, from the main mass of the sphenoidal body wherewith it forms a morticed union.

The lateral borders bear the alæ orbitales. Two areas can be distinguished in these structures. Springing directly from the sphenoidal body is a triangular process sloping caudorostrad. The upper surface is concave, broad at its origin, but narrow laterad till it terminates in a spout-like process which forms the ventral half of the circumference of the optic foramen. This triangular process corresponds to the structure found in the chondrocrania of other mammals designated as the ala hypochiasmatica (Voit). It has been shown to chondrify independently of the presphenoid and so the separate ossification here indicated can be understood.

From the extremity of the ala hypochiasmatica rises the ala orbitalis proper by two pedicles which unite to form an arch over the optic foramen. Of these pedicles the caudal is much the more slender and it appears to extend itself along the caudal border of the ala hypochiasmatica to the body itself of the presphenoid, becoming incorporated in the region cut off by that fissure on the caudal border already mentioned. Here is formed a short process seemingly continuous with the root of the ala orbitalis, which extends caudad to the border of the sphenoidal body and articulates with a special process of the basisphenoid.

The rostral root of the ala orbitalis is thicker and almost vertical in position. It takes its origin by a triangular base but quickly loses this shape through the flattening of one of the angles. At their junction, the roots form a flat bar of bone with dorsomesal and ventrolateral surfaces and narrow borders.

It will be seen that the whole ala orbitalis proper consists of the arch enclosing the optic foramen out of all proportion smaller than the ala hypochiasmatica.

The ala orbitalis appears at the mesal extremity of the orbit, encircled by frontal, lachrymal, and pterygoid. Of these bones with only the frontal does it form an articulation. This is by the periphery of the arch. The articular surface is broad rostrad, being one of the surfaces of the triangular base. It quickly narrows and maintains a uniform width to the caudal limit of the articulation. From this point a narrow border passes meso-caudad to join the border of the ala hypochiasmatica at an acute angle. This margin is the dorsal limit of the sphenoidal fissure.

*Nasals.*—The nasal bones, owing to their close approximation and firm union, really form an entity. This consists of a three-sided pyramidal mass which rests its base against the frontals, the caudal portions of its sides between maxillæ and premaxillæ, and which overhangs with its prow-like ventral surface and apex the nasal cavities. The dorsal surface of the mass forms the summit of the transverse crest. The bone of the left side is considerably smaller than that of the right, which overreaches it dorsad and caudad. On the other hand, the ventral extension of the left is greater than that of its fellow. Four surfaces and a base may be distinguished in each bone.

The base rests against the rostral face of the summit of the frontal. It is a slightly concave surface which faces laterad as well as caudad owing to the marked caudal production of the mesal border. That of the right extends beyond the caudal border of the left and thrusts itself between the two frontals. Thus the right nasal bone articulates with both of these bones; the left only with that of its own side. The whole base of the right nasal articulates with the frontal of its own side. On the other hand, the lower portion of the base of the left is refused so that only the upper half of the surface enters into this articulation in the case of this bone. Across the middle of this surface of the left bone passes a transverse groove which joins a canal between the two bones channelling their respective mesal surfaces.

The dorsal surface is triangular, smooth, convex antero-posteriorly. That of the right is more extensive in all dimensions and rises higher than that of the left. Together, the two bones form a wedge with its apex rostrad between the nares.

The lateral surface is triangularly convex and, owing to bevelling at the expense of its ventral margin, looks slightly ventrad. A small articular surface for the premaxilla exists along the caudal margin of this aspect of each bone. The rest of the surface is free.

The mesal surface is convex on the right bone, concave on the left, the two being thus neatly adapted to one another. That of the right side is prolonged caudad beyond the left and articulates with the left frontal, as already mentioned.

The ventral surfaces differ considerably on the two sides. That of the left forms a triangle with the base caudad. The caudolateral angle is produced downward in the form of a spur, rendering the surface immediately rostrad concave. The mesal border is slightly elevated and with a similar formation on the right bone forms a central caudorostral ridge on the ventral aspect of the nasal bone complex. The lateral border has a lateromesad direction, owing to the bevelling of the outer surface which affects chiefly the rostral region.

The ventral surface of the right presents two triangles, base to base, their apices rostrad and caudad. The first, except for being somewhat broader, corresponds to the ventral surface of the left nasal. The second represents the ventral surface of that caudal extension of the mesal border of the base of the bone already described. It is concave transversely, convex caudoventrad, owing to the refusal dorsad of the apex.

*Ethmoid.*—The mesethmoid is a triangular plate of bone which rests its base in the dorsal groove of the vomer, and extends its apex high into the ethmoidal notch between the frontals. The base is markedly convex transversely, straight caudorostrad and thickened at either extremity.

The rostral border leaves the ventral at an acute angle and extends dorso-caudad. It is convex longitudinally, plane from side to side, and extensively pitted to afford attachment to the septal cartilage. The cross-section shows the bone to be of soft porous structure.

The caudal border, for the greater part of its extent, is buried in the rostral face of the presphenoid. The dorsal extremity, however, rises above that structure for about half an inch, meeting the rostral border at an acute angle and forming a prominence which corresponds to the crista galli of other mammals. This border is concave to coapt it to the convex rostral surface of the presphenoid, and like the rostral, is considerably thicker near its ventral limit.

The lateral surfaces of the mesethmoid form the mesal walls of the nasal passages. They are slightly convex in the vertical direction, concave caudorostrad. Along the ventral and caudal margins they are overlain respectively by the vomer and ectethmoids. These latter bones so closely fuse to the surface that their limits can be made out only approximately.

The dorsal view shows that the bone has a distinct twist to the left, especially approaching the upper margin. The rostral tip, on the other hand, twists to the right, rendering the right lateral surface more deeply concave than the left. This deflection falls in with the general asymmetry of the skull in the narial region.

The lateral ethmoid regions consist of paired thin plates of bone attached by their mesal margins to the mesethmoid in the region of the crista galli. As they extend laterad their surfaces look toward caudad and rostrad and their lateral borders are lapped rostrad by the mesal margins of the sphenoidal turbinals. From the rostral surface of these plates thin projections which enclose between them the mesethmoid extend forward. These terminate in sharp edges which lie close to the surface of that bone, the line of demarcation being scarcely distinguishable. They present a concave, smooth surface to the nasal cavity, and a plane surface to the mesethmoid, from which they are separated by a narrow fissure. Into this fissure there opens from the cranial cavity a narrow crack, which is thought to allow passage to the nasal branch of the first division of the fifth cranial nerve. These lateral extensions of the mesethmoid are interpreted as representing the turbinals and accessory air spaces of other mammals. The space enclosed by them is the ethmoidal region. (Compare with De Burlet's work.)

*Parietal.*—The parietal is a shell-like bone, concave entally, convex ectally, which fits in the side wall of the cranium like a wedge between the converging frontal and exoccipital. It rests its thick base on the dorsal aspect of the alisphenoid. The thin pointed tip is overridden dorsally by the exoccipital. The anterior border, becoming thinner ventrodorsad, articulates in its whole extent with the frontal. Its caudal border articulates from its ventral one-third by a broad convex surface with the jugular protuberance of the exoccipital. The ental surface lies, in part, free on the outer aspect of the cranium. The ventral one-third of this surface is occupied by a depressed tongue-shaped area for articulation with the squamosal, which overlies it.

## THE MANDIBLE

The mandible is an elongated bone, broad and thin caudally, more massive but narrow towards its rostral tip. It undergoes, caudorostrad, a rotation in its long axis, so that, whereas the broader surfaces lie in the vertical plane, the narrow distal surfaces slope from below mesolaterad. Its proximal extremity bears the condyle for articulation with the glenoid cavity. The pointed distal extremity presents a cylindrical excavation for a tooth.

As mentioned above, the proximal half of the bone is broad and thin, gradually narrowing rostrad. The external surface is convex, the summit of the convexity being angular and somewhat nearer the dorsal than the ventral border. Along the line of this angulation the bone is considerably thickened. Toward either border it becomes thinner and the margins are sharp. The thickening affords considerable increase in the structural strength of the bone. The internal surface in this region presents a broad fossa, open in nearly its whole extent. Approaching the narrower portion of the bone, however, the borders give origin to shelving projections which tend to deck over the fossa more and more till they meet at an acute angle. Thence rostrad for a short distance is a complete cylinder of bone enclosing a canal which communicated rostrally with the dental groove.

The change in the width of the bone at the center of its longitudinal extent is abrupt, the full degree of narrowing being quickly reached. Thence forward to the region of the symphysis the breadth is uniform. The external surface continues rostrad in an even more marked degree the ridge found more caudally. This ridge finds its termination at a point opposite the proximal end of the symphysis, where it disappears. Just ventrad to this termination is a large mental foramen. The rostral continuation of the surface is concave caudo-rostrad, convex dorsoventrad, and faces slightly ventrad owing to the rotation of the bone already mentioned. The surface markings of this region are of interest. Strands of the most dense structure radiate from a point on the axial ridge near its center, rostrad, dorsad, and caudad. This formation would appear to be designed to make up in this pituation the strength otherwise lost through its greater narrowness as contrasted with the region immediately caudad.

The internal surface of the narrow portion is smooth throughout the greater part of its extent and convex dorsoventrad. The rostral one-third, however, is set off from the rest by a prominent ledge which passes obliquely dorsoventrad and caudad. This area, of elongated oval shape and longitudinally striated, joins the bone of the opposite side in the symphysis.

The dorsal border of the mandible in the caudal half is slightly concave. In the middle of its course it passes over a slight convexity, then falls away ventrad, thus giving rise to the narrowing of the bone. To the middle of the symphysis the margin is then horizontal. At this point it turns dorsad and, as the ventral border follows, the termination of the bone has a marked upward turn. In the caudal half the edge is smooth and rather sharp. The rostral half is channeled by an alveolar gutter which deepens till it almost splits the bone. It terminates at its very extremity in a large, round, tooth socket.

The inferior border of the mandible is uniformly concave from the caudal

extremity to the middle of the symphysis. Here it turns dorsad, in correspondence to the dorsal border, and becomes markedly convex.

From the lateral view the bone as a whole has a sinuous outline, being horizontal in its caudal half then turning slightly ventrad till the symphysis is reached when it turns dorsad. This appearance is entirely due to the direction of the borders. The axial ridge is straight and horizontal from its caudal termination in the condyle to its rostral termination at the symphysis.

The rostral extremity of the mandible is blunt and is perforated by the round tooth socket. The caudal extremity is convex in its general outline. Two-fifths of its extent, somewhat nearer the dorsal than ventral margin, bears the condyle. This projects a short distance beyond the rest of the margin and presents an oval facet, roughened for union with the articular cartilage. This condyle, in reality, is the caudal extremity of the axial ridge of the whole bone whose cross-section it represents.

#### BIBLIOGRAPHY.

- ANDERSON, R. J., 1904, 6<sup>me</sup> Congrès International de Zoologie, Berne, p. 703.  
 BURMEISTER, H., 1866, *Ann. and Mag. Nat. Hist.*, (3), XVIII; 1869, *Anales del Museo Publico de Buenos Aires*, I, 1864-1869, p. 312.  
 CUVIER, 1823, *Oss. Fossiles*, 2 Ed., V, part 1, p. 350.  
 DEAN, B., 1914, *Scientific American*, Sup., LXXVII, No. 2003, May 23, p. 333.  
 DOUMET, 1842, *Revue Zoologique*, p. 207.  
 DUVERNOY, 1851, *Annales des Sciences Naturelles*, Zool., (3), XV, p. 63.  
 FISCHER, 1866, *Ann. and Mag. Nat. Hist.*, (3), XVIII, p. 255;  
 1867, *Nouvelle Arch. du Mus. d'Hist. Nat.*, III, pp. 42, 45;  
 1881, *Actes, Soc. Linn. de Bordeaux*, (4), XXXV, p. 103.  
 FLOWER, 1871, *Trans. Zool. Soc. London*, VIII (1874), p. 203;  
 1876, *Proc. Zool. Soc. London*, p. 477.  
 GERVAIS, 1850, *Annales des Sciences Nat.*, Zool., (3), XIV;  
 1859, *Zool. et Paléontol. franç.*, 2d Ed., p. 287.  
 GRAY, 1865, *Proc. Zool. Soc. London*, pp. 357, 523;  
 1871, *Ann. and Mag. Nat. Hist.*, (4), VII;  
 1873, *Trans. and Proc. New Zealand Inst.*, VI (1874), p. 95.  
 HECTOR, J., 1872, *Trans. and Proc. New Zealand Inst.*, V (1873), p. 154;  
 1878, *Trans. and Proc. New Zealand Inst.*, X, p. 343.  
 KNOX, F. J., 1870, *Trans. and Proc. New Zealand Inst.*, III (1871), p. 125.  
 MCINTOSH, 1911, *Zoologist*, (4), XV, p. 81.  
 OWEN, R., 1870, *Monograph of the British Fossil Cetacea from the Red Crag*, No. 1.  
 SCLATER, 1901, *The Fauna of South Africa*, II.  
 STEJNEGER, L., 1883, *Proc. U. S. Nat. Mus.*, VI, p. 75.  
 TRUE, F. W., 1886, *Proc. U. S. Nat. Mus.*, VIII, p. 596;  
 1910, *Bull. 73, U. S. Nat. Mus.*



- TURNER, W., 1880, Reports on Bones of Cetacea Collected on the Voyage of H. M. S. Challenger in the years 1873-1876, part 1;  
1872, Trans. Royal Soc. Edin., XXVI, p. 759.  
VAN BENEDEN, 1888, Memoires Couronnés l'Acad. Roy. des Sci., Brussels, XLI.  
VON HAAST, J., 1870, Ann. and Mag. Nat. Hist., (4), VI, p. 348;  
1876, Proc. Zool. Soc. London, pp. 456, 466;  
1876, Trans. and Proc. New Zealand Inst., IX (1877), pp. 430, 440;  
1879, Trans. and Proc. New Zealand Inst., XII (1880), p. 241;  
1880, Proc. Zool. Soc. London, p. 232;  
1883, Proc. Zool. Soc. London, p. 590.

## EXPLANATION OF PLATES

## PLATE XX

- Figure 1. Dorsal view of adult female skull.  
Figure 2. Ventral view of adult female skull.

## PLATE XXI

- Figure 1. Dorsal view of foetal skull.  
Figure 2. Ventral view of rostrum, foetal.

## PLATE XXII

- Figure 1. Lateral view of adult skull.  
Figure 2. Caudal view of adult skull.

## PLATE XXIII

- Figure 1. Floor of cranial cavity, foetal.  
Figure 2. Rostral wall of cranial cavity, foetal.

## PLATE XXIV

- Figure 1. Caudal wall of cranial cavity, foetal.  
Figure 2. Lateral wall of cranial cavity, foetal.

## PLATE XXV

- Figure 1. Basi- and exoccipitals, ental aspect, foetal.  
Figure 2. Basi- and exoccipitals, ectal aspect, foetal.

## PLATE XXVI

- Figure 1. Base of skull, otic region, adult.  
Figure 2. Base of skull, otic region, foetal.

## PLATE XXVII

- Figure 1. Dorsal view of maxillæ, foetal.  
Figure 2. Ventral view of maxillæ, foetal.

## PLATE XXVIII

- Figure 1. Dorsal view of premaxillæ.  
Figure 2. Lateral aspect, left premaxilla (above), and  
Mesal aspect, right premaxilla (below).

## PLATE XXIX

- Figure 1. Dorsum of vomer, mesethmoid, and presphenoid.  
Figure 2. Lateral aspect of vomer, mesethmoid, and presphenoid.  
Figure 3. Ventral aspect of vomer, mesethmoid, and presphenoid.

## PLATE XXX

- Figure 1. Nasal and jugal bones.  
Figure 2. Palate and lachrymal bones.

## PLATE XXXI

- Figure 1. Pterygoids.  
Figure 2. Periotic and tympanic bones.

## PLATE XXXII

- Figure 1. Mandible.  
Figure 2. Frontal.

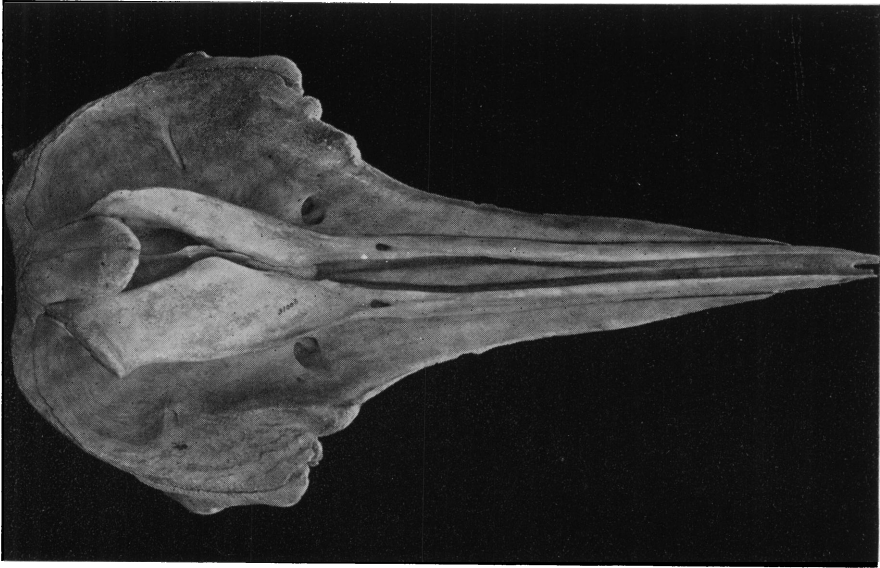


Fig. 1. Dorsal view of adult female skull.

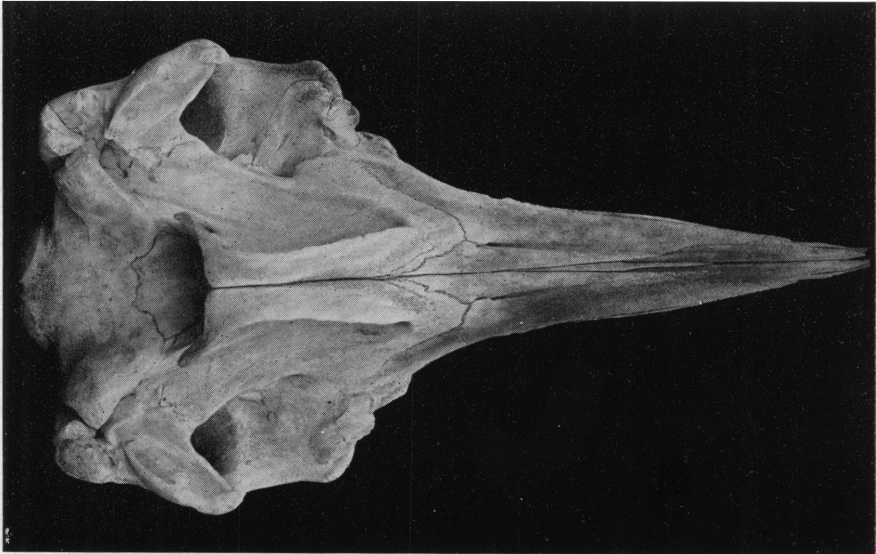


Fig. 2. Ventral view of adult female skull.



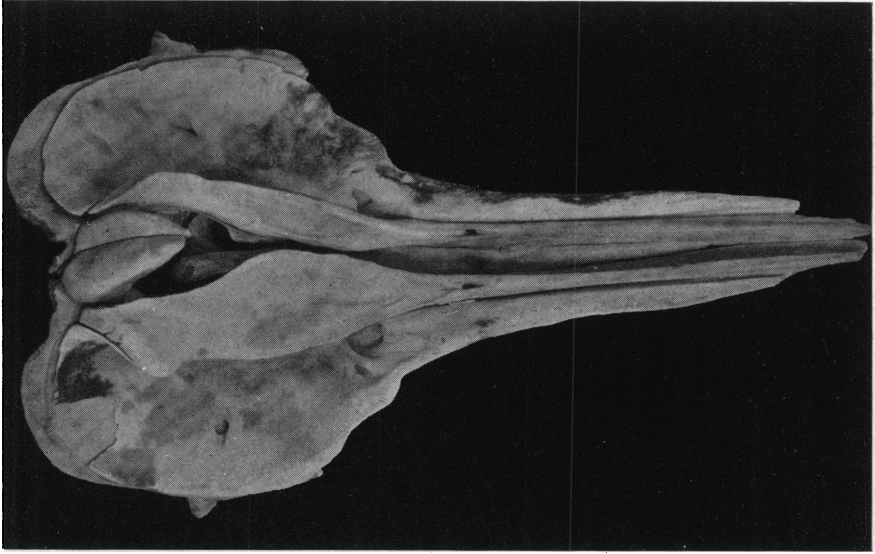


Fig. 1. Dorsal view of foetal skull.

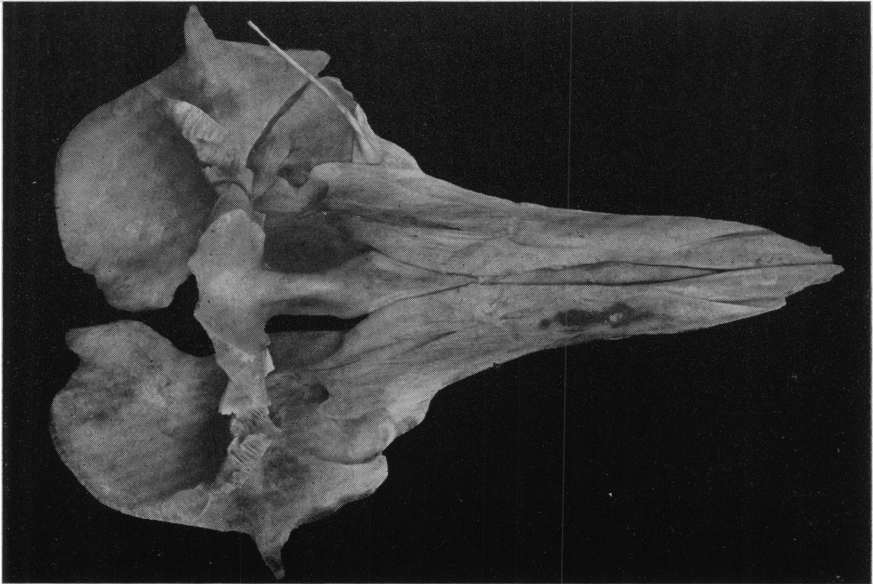


Fig. 2. Ventral view of rostrum, foetal.



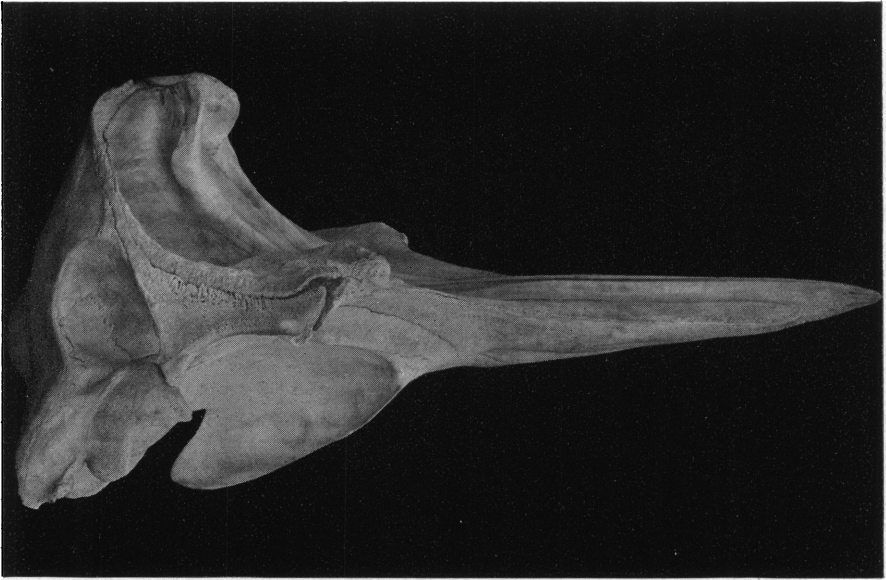

Fig. 1. Lateral view of adult skull.

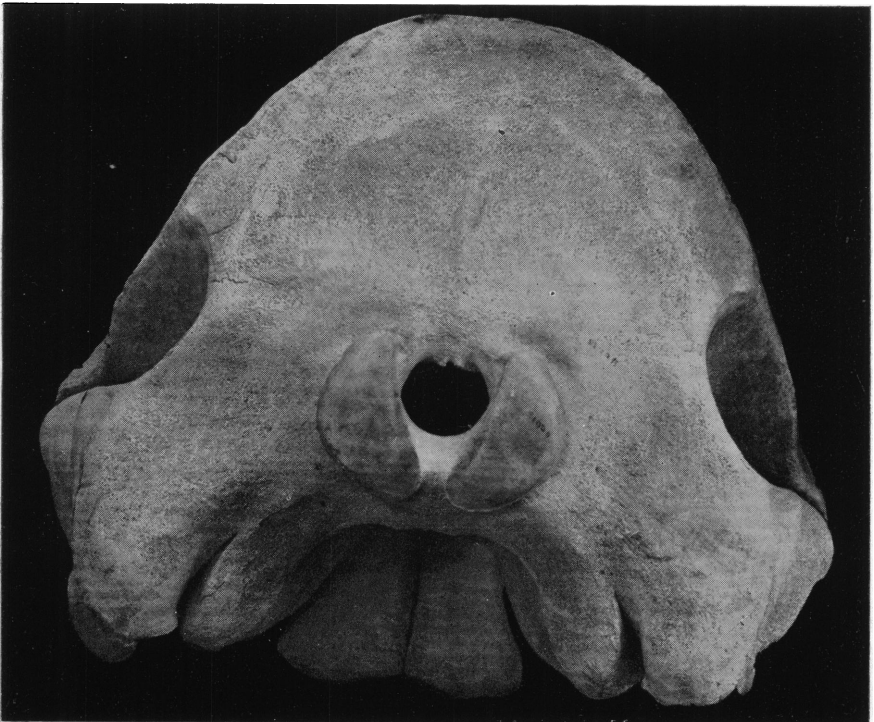


Fig. 2. Caudal view of adult skull.





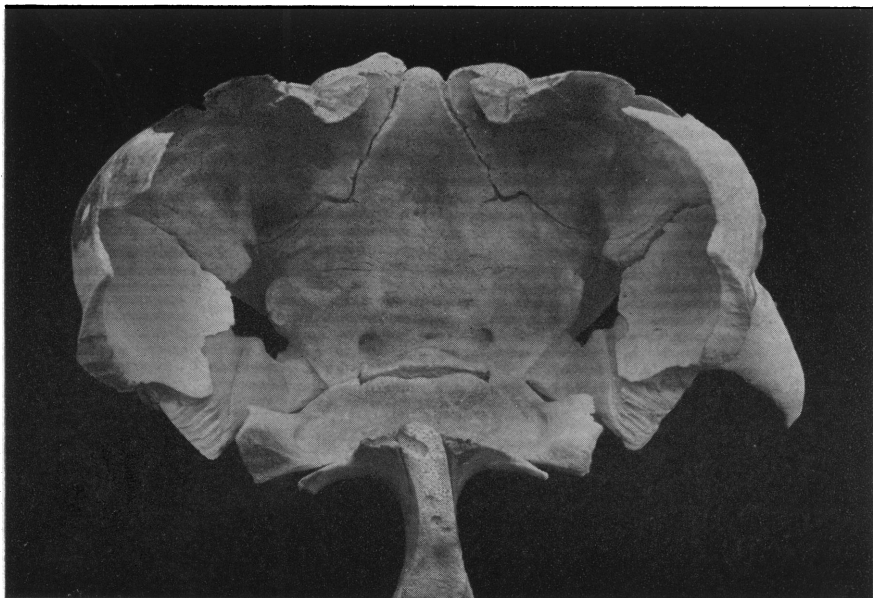

Fig. 1. Floor of cranial cavity, foetal.

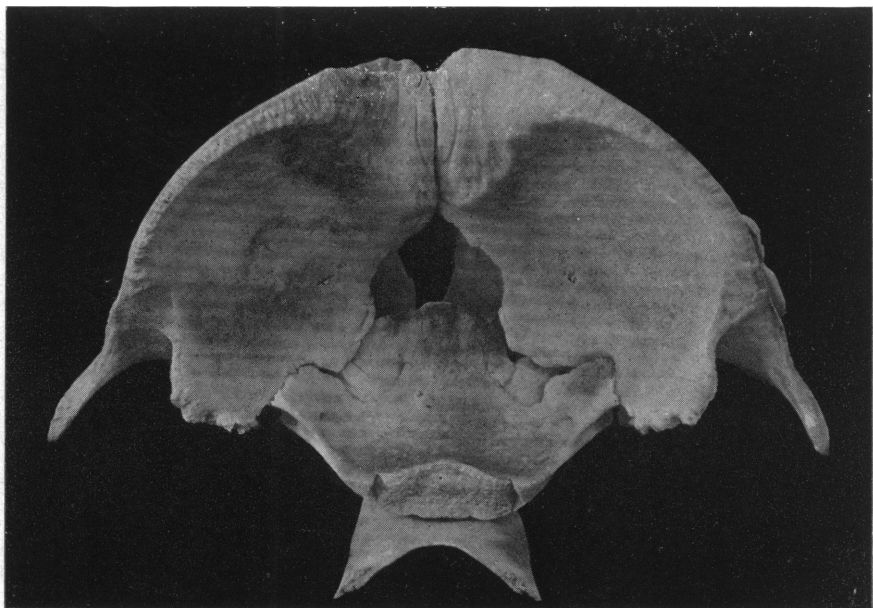


Fig. 2. Rostral wall of cranial cavity, foetal.



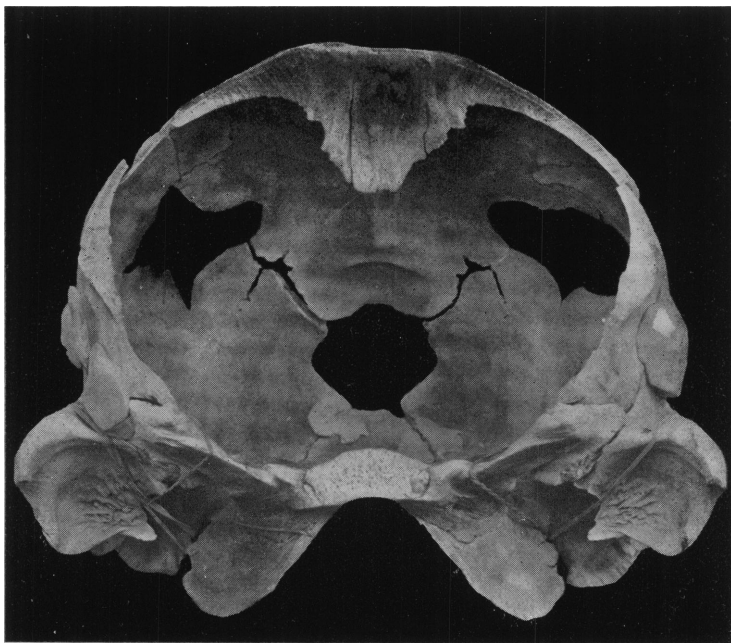


Fig. 1. Caudal wall of cranial cavity, foetal.

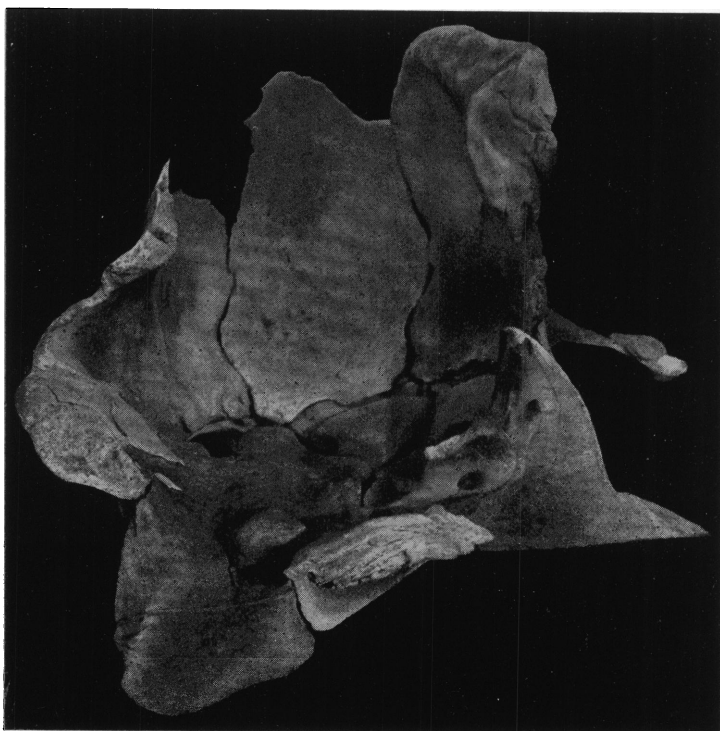

Fig. 2. Lateral wall of cranial cavity, foetal.



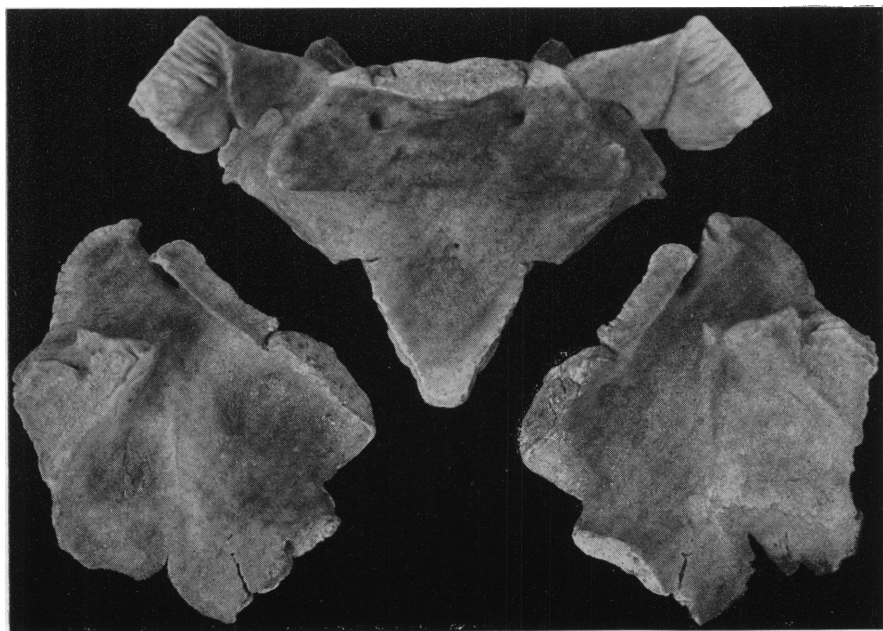


Fig. 1. Basi- and exoccipitals, ental aspect, foetal.




Fig. 2. Basi- and exoccipitals, ectal aspect, foetal.



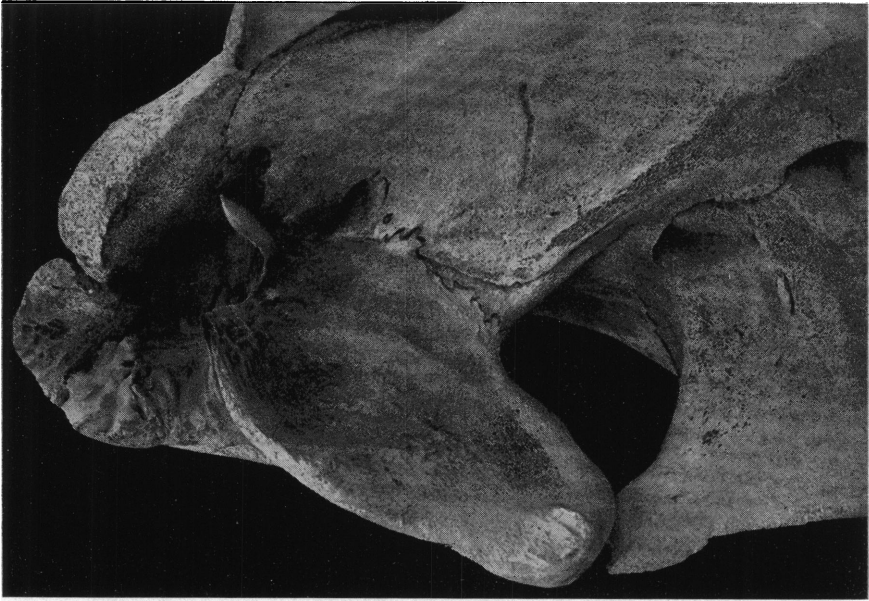

Fig. 1. Base of skull, otic region, adult.

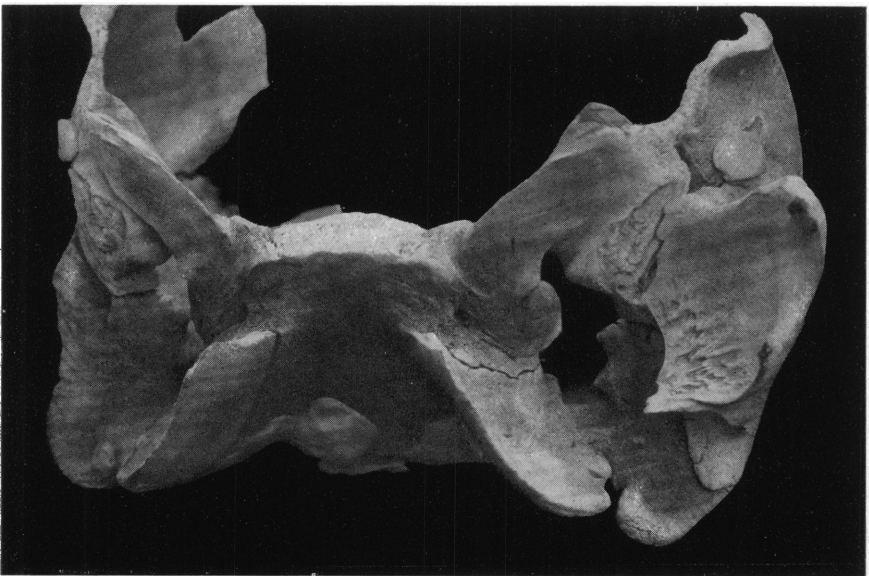

Fig. 2. Base of skull, otic region, foetal.





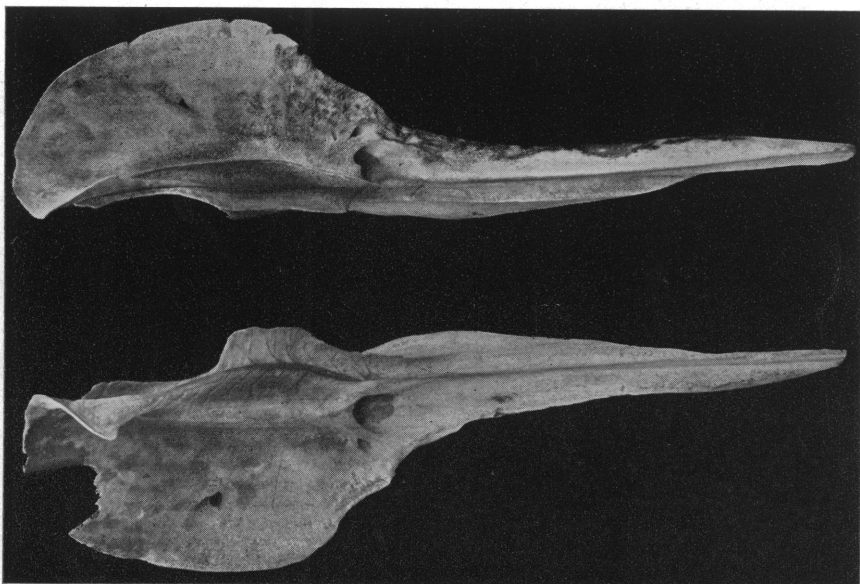


Fig. 1. Dorsal view of maxillæ, foetal.

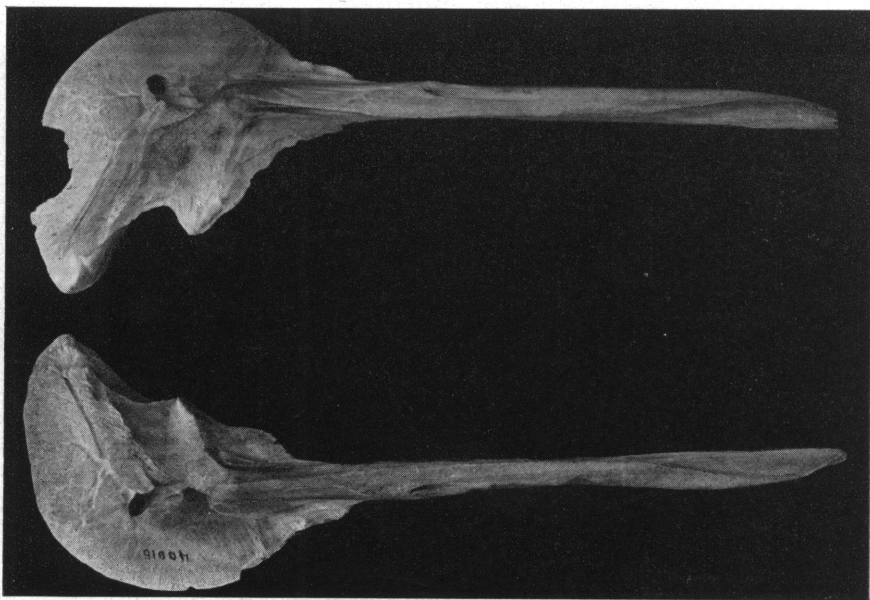


Fig. 2. Ventral view of maxillæ, foetal.



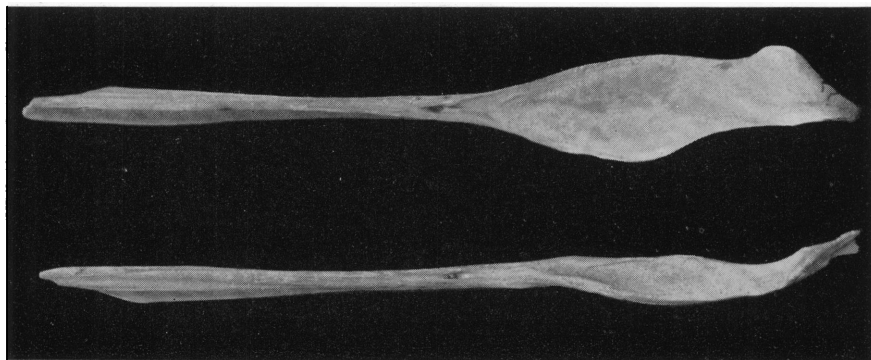


Fig. 1. Dorsal view of premaxillae.

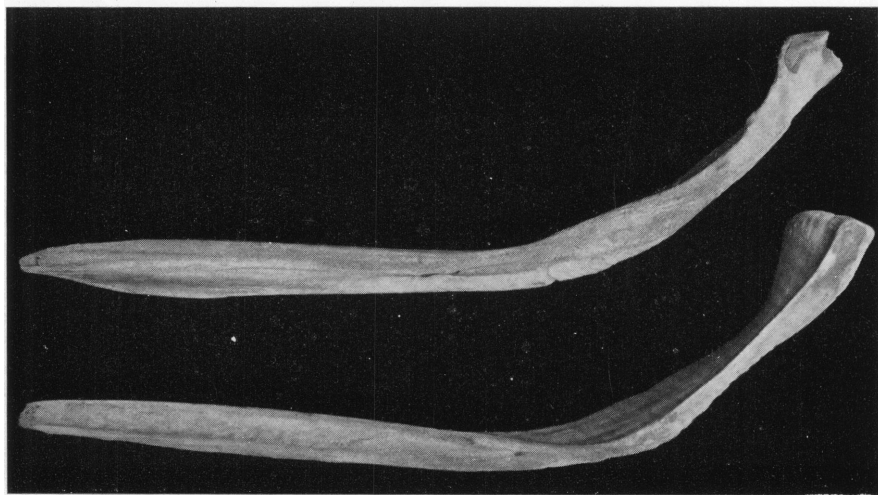


Fig. 2. Lateral aspect, left premaxilla (above), and mesal aspect, right premaxilla (below).






Fig. 1. Dorsum of vomer, mesethmoid, and presphenoid.

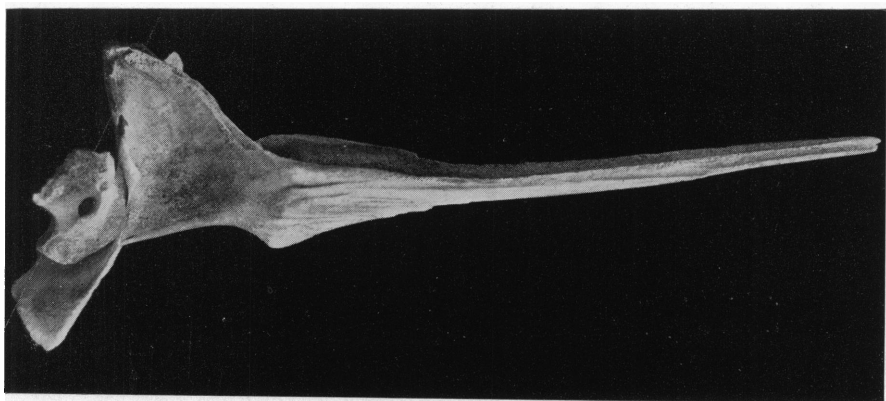


Fig. 2. Lateral aspect of vomer, mesethmoid, and presphenoid.

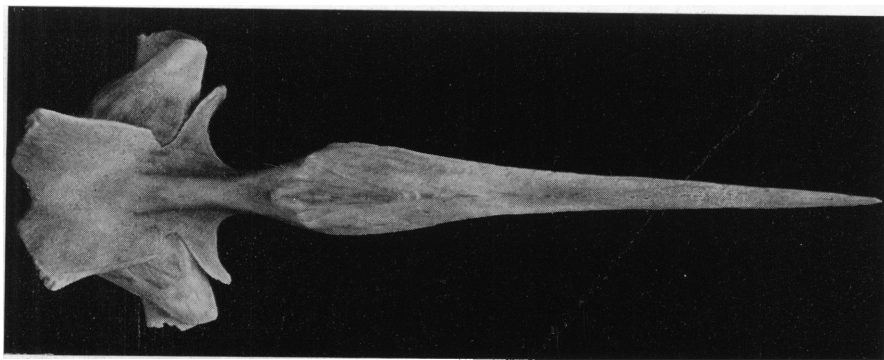


Fig. 3. Ventral aspect of vomer, mesethmoid, and presphenoid.



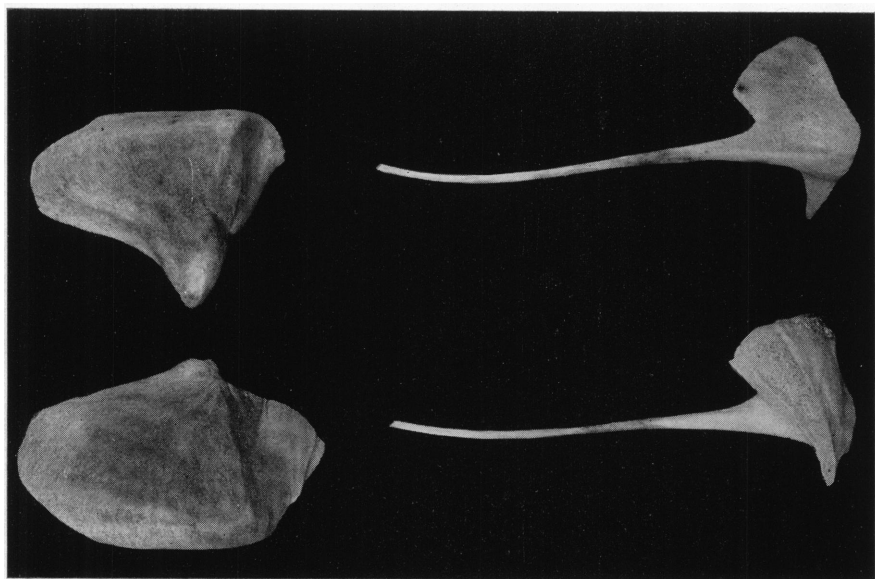


Fig. 1. Nasal and jugal bones.

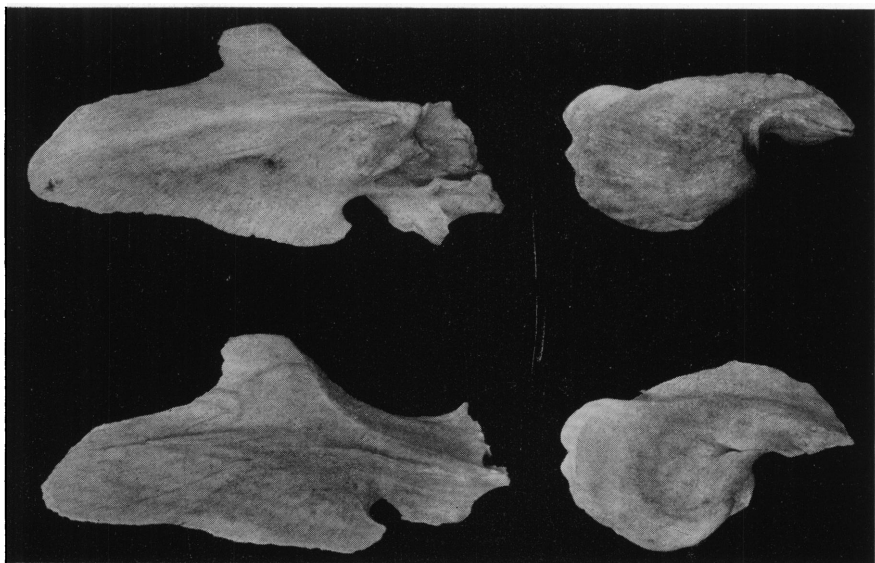


Fig. 2. Palate and lachrymal bones.





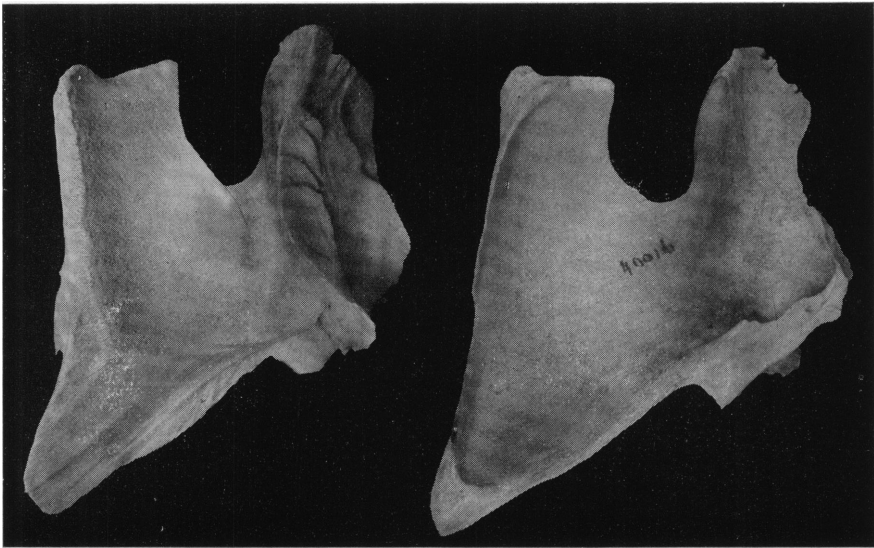


Fig. 1. Pterygoids.

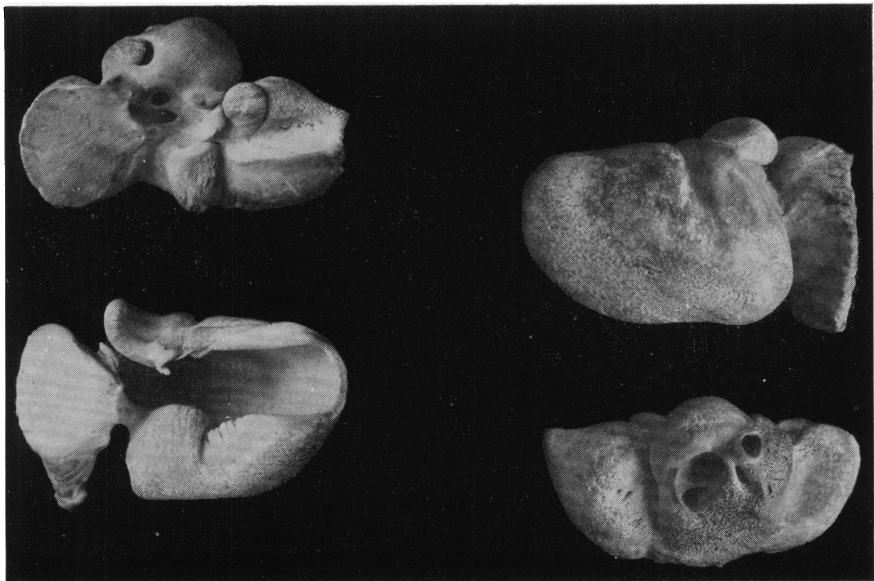

Fig. 2. Periotic and tympanic bones.



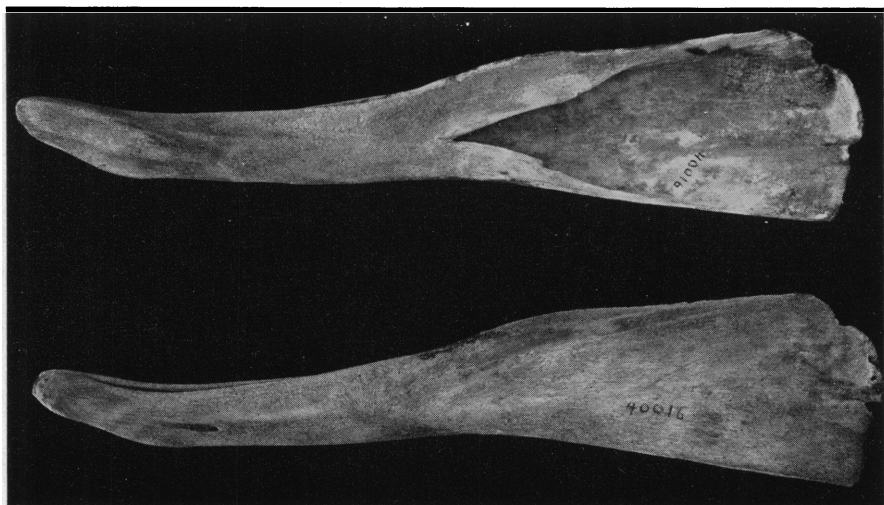


Fig. 1. Mandible.

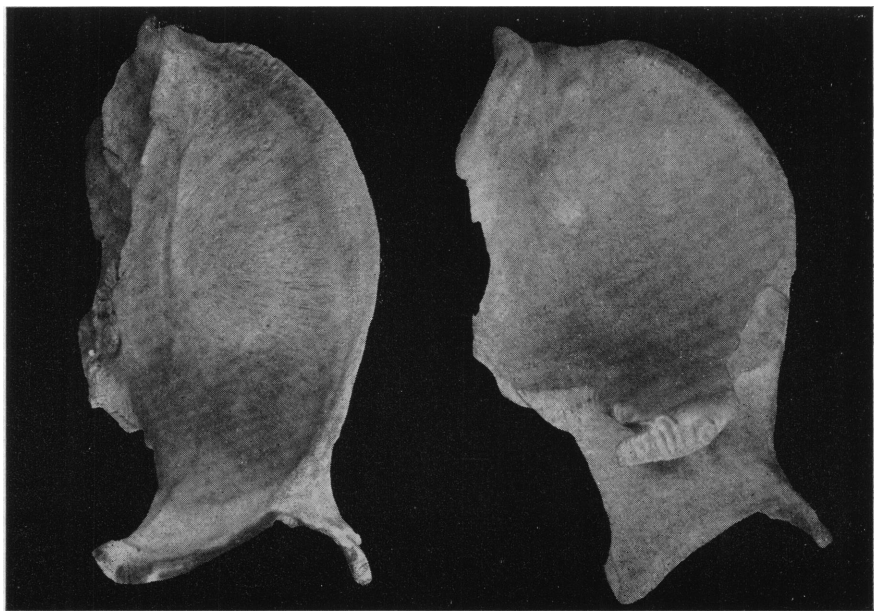

Fig. 2. Frontal.

