

# AMERICAN MUSEUM NOVITATES

Number 740

Published by  
THE AMERICAN MUSEUM OF NATURAL HISTORY  
New York City

August 17, 1934

---

59.9.725 E: 14, 71.52

## FRONTAL PROTUBERANCES IN HORSES

### AN EXPLANATION OF THE SO-CALLED "HORNED" HORSE

BY S. HARMSTED CHUBB

Many of those who are associated with or are particularly interested in horses have seen or heard reports of "horned" horses. It is true that occasionally a horse appears with a pair of small protuberances on the forehead above the eyes and a little toward the median line of the skull. Although these protuberances are commonly spoken of as "horns," they should not be associated in any way with true horns, such as we find in the cattle, sheep, goats, and antelopes. While horns are simply modified hair, a dermal growth, with a bone process rising from the skull to support them, the protuberances on horses' foreheads, though composed of bone, never have any suggestion of a horny growth over them but are covered with skin and the usual growth of hair. The occasional development of these abnormalities in horses has attracted considerable attention and prompted a good deal of discussion among scientists as to its cause and possible significance.

The writer has at hand more than a dozen authentic reports of horses having such protuberances. It did not escape the notice of Darwin who, in 'The Variation of Animals and Plants Under Domestication,' (1) published in 1867, wrote as follows: "In various countries hornlike projections have been observed on the frontal bones of the horse: in one case described by Mr. Percival (2) they arose about two inches above the orbital processes, and were 'very like those in a calf from five to six months old,' being from one-half to three-quarters of an inch in length. Azara (3) has described two cases in South America in which the projections were between three and four inches in length: other instances have occurred in Spain."

Lydekker (4) cites a number of examples and gives an illustration of a skull bearing protuberances. The subject also is discussed at some length by Winogradow and Frolow (5), by Cunningham (6), and others.

Mr. Alfred J. Day of Fontwell, England, has kindly sent us plaster casts of the foreheads of two thoroughbred horses, "Domain," four years old, and "The Swamper," two years old, which show very clearly typical

examples of these protuberances. A photograph of one of these casts is shown in figure 1, where it will be seen that the normal growth of hair extends uniformly over the protuberances. The horses from which these casts were taken were under Mr. Day's observation for some time and were described by him in a paper, 'Rudimentary Horns in Horses,' which he has sent me and which he tells me was read by Dr. Eustace (7) before the Linnaean Society of London in June, 1903. He writes as follows: "These animals have rudimentary bosses of bone on the forehead: in the younger of the two animals the breeder informed me when I purchased it that they did not appear until about six months after birth,

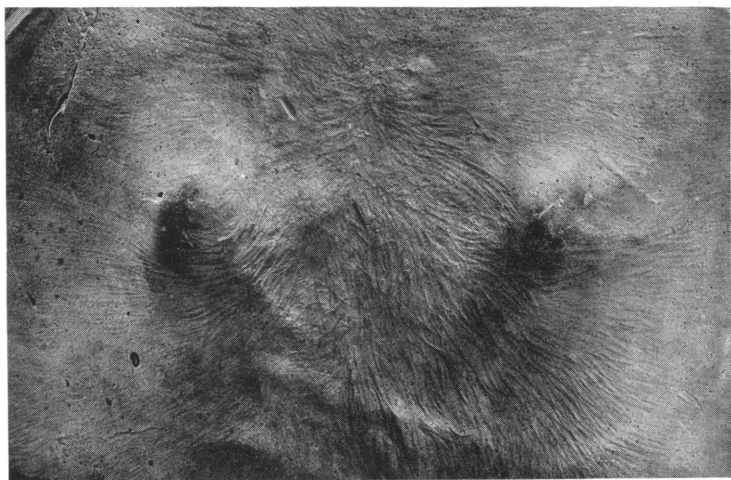


Fig. 1. Plaster cast of the forehead of "Domain," a thoroughbred horse four years old, showing frontal protuberances.

It will be seen that the normal growth of hair extends uniformly over the protuberances. Cast presented by Mr. Alfred J. Day.

and in both horses the near or left horn is larger than the right. . . . In the elder horse, "Domain," the left boss is about an inch in length, which has slightly increased during the two years it has been under my observation."

There are on exhibition in the British Museum (Natural History) two skulls as well as Mr. Day's plaster casts, which show conditions practically identical to those so often described.

Although for many years I have been interested in this subject, the present investigation probably would not have been made at this time had it not been for Mr. Day's generosity in giving us these plaster casts,



**Fig. 2. Two cases of frontal protuberances.**

*A*, a work horse having symmetrical but small protuberances. Owned by Sheffield Farms Company.

*B*, a heavy type horse, thirteen years old, showing protuberances not quite symmetrical, the left, the larger one, being three-fourths inches high. Owned by Borden's Farm Products Company.

*C*, side view of *B*.

and also in sending us reports of other cases that have come under his observation.

Recently I have made a systematic search among the horses of New York City, having examined three thousand one hundred eighty horses, in the hope of finding a few well-defined cases of frontal protuberances and also of establishing an approximate estimate of the percentage of its occurrence.

Here I wish to express my appreciation of the courtesy and kind coöperation shown by many owners of horses, particularly by Mr. Lagerquist of the Sheffield Farms Company, and by Mr. Bates and Mr. Evans of the Borden's Farm Products Company, who have rendered valuable assistance in giving me a free hand in their many stables.

Among this large number of horses examined only five of the much sought abnormalities were found. This is a very small percentage for New York City, but, no doubt, a horse breeding section would show a much higher percentage, as the stock offered in a city market would be more or less selected. In this discrimination, anything that might be regarded as a serious pathological condition or a blemish might cause the individual to be discarded even though the protuberances under consideration would not detract in the least from the practical value of the horse.

The most well-defined case met with is illustrated in figure 2, *B* and *C*, a heavy type of work horse thirteen years old, now in the service of Borden Company. In this case, however, the protuberances are much less prominent than in many of those that have been reported. In another respect this individual is not quite typical, as the protuberance on the left side, which rises three-fourths of an inch above the plane of the forehead, is perceptibly larger than the one on the right. They are located on the frontal bone three and one-half inches apart and three and one-fourth inches from the borders of the orbits.

At one of the many Sheffield Farms' stables visited, a white horse (Fig. 2, *A*) was found with a symmetrical pair of small protuberances. In addition to those figured, three cases were found where the protuberances were equally developed but not sufficiently pronounced to attract special attention.

Although many writers have called attention to these frontal protuberances, so far as I have learned no satisfactory explanation of their occurrence has been offered. There are those who would regard these abnormalities as reversions, a manifestation of the tendency to harp back to some ancestor of the remote past, but, as the evolution of

the Equidae is now well known as far back as *Eohippus* of the Lower Eocene, and as none of the fossil remains shows any indication of "horns," this theory seems hardly tenable. Winogradow suggests that it may be a reversion to a reptilian ancestor, but this would require a strain of the imagination quite unnecessary if there is an explanation near at hand.

Then there are others who would look upon these "horns" as being prophetic and would expect that in ages to come horses will be equipped with these implements, impediments, or ornaments, as the case may be. This theory is difficult to controvert, for who shall say what the appearance of a horse may be only a few million years hence.

But should we not first "seek diligently" for a more tangible explanation? It is true that abnormal enlargements may appear in or under the skin at any part of the body. However, the fact that there seems to be a striking uniformity in the appearance and location of these small protuberances, that they are in the bone, and also that they occur in pairs, would lead one to look for a structural cause for their presence rather than for a pathological condition.

The most hopeful line of investigation, therefore, has been found in the singular behavior of the orbitosphenoid wings of the sphenoid complex in the Equidae, notwithstanding the fact that these wings have their origin at the base of the cranium, while the point of our present interest is at the top of the skull.

The sphenoid complex, in the foetal stage, is one of the bones that is preformed in cartilage, differing in this respect from those cranial bones that are of intermembranal formation. It is one of the few bones of the skull not occurring in pairs, being central and intersected by the median line of the skull. This bone is located in the anteroventral and lateral portions of the cranium, and in the Equidae, as in most of the ungulates, forms a considerable part of the floor and wall of the brain cavity.

The sphenoid complex has a pair of wing-like extensions known as the orbitosphenoids. Each of these orbitosphenoids extends outward and upward along the inside of a part of the frontal bone, with the upper border inserted into a fissure between an inner and an outer wall of the frontal. This bone is best seen in a view of the interior of the sectioned skull of a colt eleven months old (Fig. 3, Specimen No. 38) where the greater part of the cartilage is now replaced by bone, although from a lateral view of the same specimen (Fig. 4, *os.*) smaller parts of the bone can be seen: a narrow strip in the posterior region of the orbit, exposed to view by the removal of the zygomatic arch, and another, exposed by an opening cut in the outer wall of the frontal.

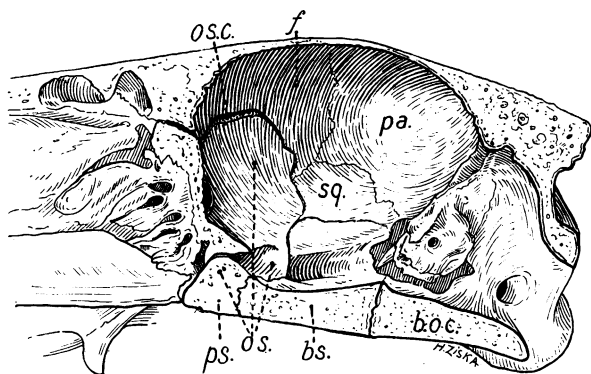


Fig. 3. Median section of the skull of a colt eleven months old, showing interior of brain cavity.

*os.*, orbitosphenoid; *os. c.*, part of the cartilaginous portion of the orbitosphenoid where it enters the frontal fissure; *f.*, frontal; *ps.*, presphenoid; *bs.*, basisphenoid; *boc.*, basioccipital; *pa.*, parietal; *sq.*, squamosal; Specimen No. 38.  $\frac{1}{3}$  natural size.

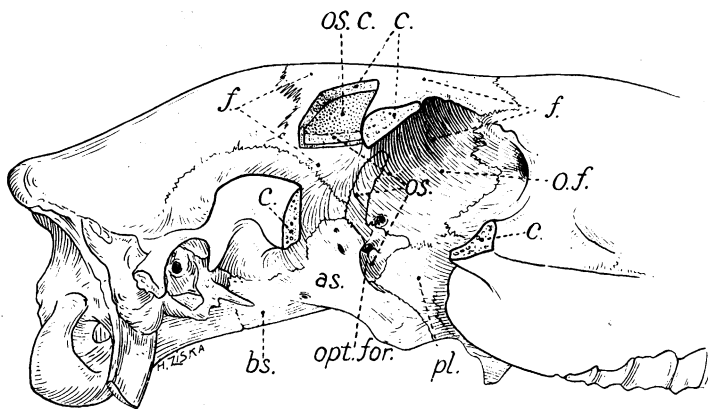


Fig. 4. Lateral view of the skull of a colt eleven months old, with zygomatic arch and section of frontal removed.

*os.*, part of orbitosphenoid where it appears through the narrow opening in the frontal, also its upper portion where it is exposed by the removal of the outer wall of the frontal; *os. c.*, that part of the orbitosphenoid which, in the colt, is still represented in cartilage but will later be replaced by bone; *c.*, cut surface of bone; *f.*, frontal; *o. f.*, orbital wall of frontal; *opt. for.*, optic foramen; *as.*, alisphenoid; *bs.*, basisphenoid; *pl.*, palatine. Specimen No. 38.  $\frac{1}{3}$  natural size.

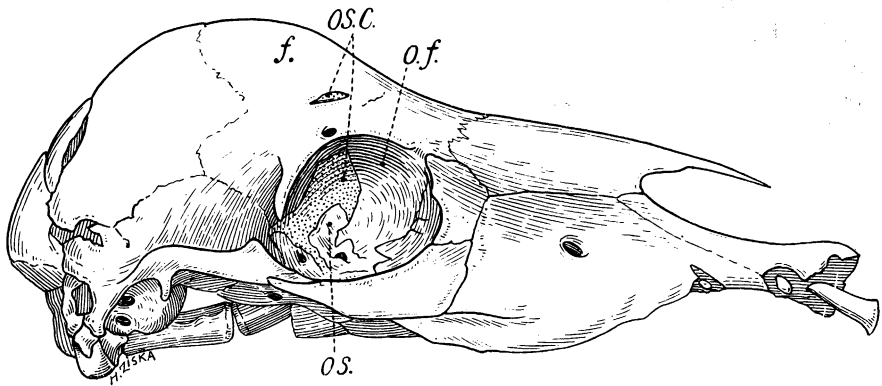


Fig. 5. Foetal skull at an early stage of gestation.

*os.*, bony portion of orbitosphenoid; *os. c.*, cartilaginous portion of orbitosphenoid which will later be replaced by bone; *f.*, frontal; *o. f.*, orbital wall of frontal. Specimen No. 2.  $\frac{3}{8}$  natural size.

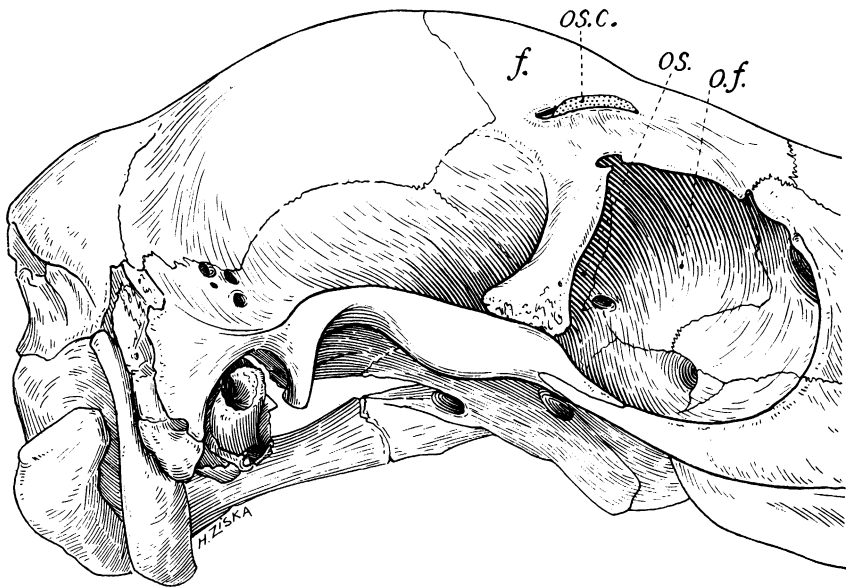


Fig. 6. Skull of a colt five weeks old.

*os.*, orbitosphenoid; *os. c.*, cartilaginous edge of orbitosphenoid protruding through perforation in frontal; *f.*, frontal; *o. f.*, orbital wall of frontal. Specimen No. 34.  $\frac{3}{8}$  natural size.

Now, upon considering an early foetal stage, we find that the central body of the sphenoid begins its calcification while the orbitosphenoid extension still remains represented in preformed cartilage. Soon bone begins to replace the cartilage in the lower portion of the orbitosphenoid, but long before the bone has extended to the upper part a strange development takes place. It would seem that the upward growth of the orbitosphenoid is just a little too rapid for the outside expansion of the growing skull. Consequently, while it is still in soft cartilaginous form, it forces its way into the fissure of the frontal and finally perforates the bone, so that a portion of the cartilaginous edge of the orbitosphenoid appears through the surface of the frontal bone at a point on the forehead corresponding to the position of the so-called "horns," as shown in figure 5.

Although this interesting phase of development appears early in the prenatal stage it continues in a greater or less degree until shortly after birth when, normally, the growing skull overtakes the precocious growth of the orbitosphenoid, leaving its upper edge below the surface of the frontal. Then the perforation fills with new bone and disappears.

It has been said that a tallow candle can be shot through an oak board. I have not tried this interesting experiment but, if true, it would seem no stranger than that soft cartilage should force its way through a much harder frontal bone.

Upon the examination of many specimens it seems that this exciting race in the speed of growth is a close one and, while the frontal has by far the better chance, the finish is never quite certain. During the foetal stage, the lead is sometimes transferred from one to the other in a given individual so that the frontal may be perforated, then filled, and again perforated. Now, if later in the period of colthood, for some reason, the orbitosphenoid should persist in the lead, the natural tendency would be for the frontal bone to build up over the obstruction. Then we would have the phenomenon of a "horned" horse. Indeed, the specimen shown in figure 6, a skull about five weeks old, seems to be approaching this condition. It will be seen that the edges of the perforation, through which the cartilage protrudes, are inclined upward as if in the process of covering the protruding cartilage; and had the colt lived it would, no doubt, have developed a pair of prominences on the forehead. Unfortunately, owing to its curtailed career, it never quite attained the distinction of becoming a "horned" horse.

Referring again to figure 4, where a portion of the outer wall of the frontal bone has been removed, it will be seen that a considerable

portion of the orbitosphenoid is still in cartilaginous form. When the skull is fully grown, this cartilage will have been replaced by bone and the upper border of the mature orbitosphenoid will be only a scant eighth of an inch beneath the surface of the frontal bone. This seems a rather narrow margin of safety by which any individual may escape developing a pair of frontal protuberances that would make him eligible for a "freak show."

In general appearance the orbitosphenoid in the Artiodactyls is similar to that of the Equidae and enters the frontal fissure as in the horse but does not appear to outgrow the frontal, so that there is no competition and no perforation of the frontal bone, so far as I have observed.

For many years I have hoped to procure the skull of a fully mature horse showing these abnormalities. When successful, I feel sure that a careful examination of the frontal region will add even further evidence in support of the above deductions.

It has been shown that the perforation of the frontal bones by the orbitosphenoids is a perfectly normal occurrence during foetal life, that occasionally a slight overgrowth of these wings persists after birth, and that, in such a case, the frontal bones build up ossified material over these parts of the protruding orbitosphenoid wings; thus these prominences become permanent and the so-called "horned" horse results. Frontal protuberances in horses should be looked upon, therefore, not as a reversion to an ancestral type, or as a rudiment of some future development, or even as a pathological condition, but as a result of a peculiar method of construction which, in rare cases, becomes only slightly modified and yet affects the contour of the mature skull.

#### REFERENCES

- (1) DARWIN, CHARLES R. 1900. 'The Variation of Animals and Plants Under Domestication.' New York, I, p. 50.
- (2) PERCIVAL, CHARLES. 1828. 'Horns in the Horse.' *Veterinarian*, August, I, p. 274.
- (3) AZARA, FELIX DE. 1838. 'Natural History of the Quadrupeds of Peru.' London, I, pp. 30-31.
- (4) LYDEKKER, R. 1912. 'The Horse and Its Relatives.' New York, p. 60.
- (5) WINOGRADOW, P. P., AND FROLOW, A. L. 1929. 'Hörnerförmige Bildung auf den Stirnbein eines Pferdes.' *Anat. Anz.*, Bd. 68, pp. 93-94.
- (6) CUNNINGHAM, J. T. 1905. *Proc. Zool. Soc. London*, II, p. 323.
- (7) EUSTACE, DR. G. W. 1903. 'Rudimentary Horns in Horses.' *Proceedings of the Linnaean Society of London*, June, pp. 48-49.

