

# American Museum Novitates

---

PUBLISHED BY THE AMERICAN MUSEUM OF NATURAL HISTORY  
CENTRAL PARK WEST AT 79TH STREET, NEW YORK, N. Y. 10024

---

NUMBER 2399

DECEMBER 30, 1969

---

## On the Jaw Muscles of Ankylosaurs

BY GEORGE HAAS<sup>1</sup>

### INTRODUCTION

The present paper is based on the study of two ankylosaur skulls and their mandibular rami. These skulls, in the American Museum of Natural History (A.M.N.H. Nos. 5337 and 5405), have not as yet been described. It seems probable that they belong to the genus *Euoplocephalus*. They came from the Oldman Formation of late Cretaceous age, and were found at localities along the Red Deer River, below Steeveville, Alberta.

I am very grateful to Dr. Edwin H. Colbert who kindly suggested that I carry out the study on the cranial muscles in both of these skulls. The muscles are discussed in the following sequence: 1) the adductor externus group, including the levator anguli oris; 2) the adductor posterior; 3) the adductor mandibulae internus group, including the pseudo-temporalis muscle, and the pterygoideus muscle. All of these muscles are innervated by the trigeminal nerve. The muscle depressor mandibulae, innervated by the facialis nerve, is also discussed.

### THE ANKYLOSAUR SKULL

The ankylosaur skull, as exemplified by the two specimens used in this study, is secondarily closed by accessory dermal bones so that no temporal fossae can be discerned. Similar accessory ossifications cover certain parts of the external and ventral face of the mandible. The skull is rather depressed in profile view, and is blunt and very broadened

---

<sup>1</sup> Professor, Department of Zoology, Hebrew University, Jerusalem, Israel.

caudally, as seen in ventral aspect. Owing to the strong secondary bone cover and the rigid structure of the palatal bone elements, no kineticism of skull elements is possible. The pterygoid bones, which are divergent caudally, together enclose an angle of 150 degrees more or less—a rather peculiar position; they are reinforced by a close apposition of deep, wide pterygoid bone lamellae of the quadrates. The possible normal area for the adductor muscles is somewhat shortened, because the orbit has a rather posterior position and it pierces the skull at a remarkably low level. The posterolateral part of the skull flares out laterally and is firmly anchored by a massive quadrate element, both dorsally and latero-ventrally. The two articular surfaces of both quadrates are shifted inwards from the frill-like armored temporal “carapace” and enclose (repeating the direction of both caudal pterygoid lamellae) an angle of about 150 degrees. Both articulations are elongated, more or less cylindrically, in the same direction. The temporal armor of dermal bones is internally hollowed out, especially posterior to the quadrates, up to a level dorsal to the paroccipital processes of the exoccipitals.

In lateral view, it is apparent that the tooth-bearing portion of the lower jaw has a much higher convex elevation than the low symphyseal part and the insignificant “coronoid” prominence in front of the articular area. With the mouth closed the mandibular dental elevation disappears partly inside the similarly arched contour of the upper jaw by penetrating into a wide furrow between the maxillary margin and the upper tooth row.

## THE JAW MUSCLES

The possible location of adductor muscles is discussed first. One of the first problems is to determine whether, and to what extent, such muscles did overgrow the posterolateral parts of the mandible—posteriorly and posterolaterally to the dental bulge. Deep furrows, caused by periosteal blood vessels, together with large ventral areas plastered with osteodermic ossifications, exclude such a possibility. Nevertheless, there still remains a considerable area in the smaller posterior half of the jaw exhibiting rather smooth bone surfaces. In reptiles, a notable extension of adductors on the outer surface of the mandible is rarely found. This has been amply demonstrated, not only in a few squamates and *Sphenodon*, but also in turtles and crocodiles, among which muscles of this group attach mainly to the inner (posterior) face of the jaw and to the “coronoid elevation.” Only in the case of a developed levator anguli oris might antero-external insertions be expected—or parts of

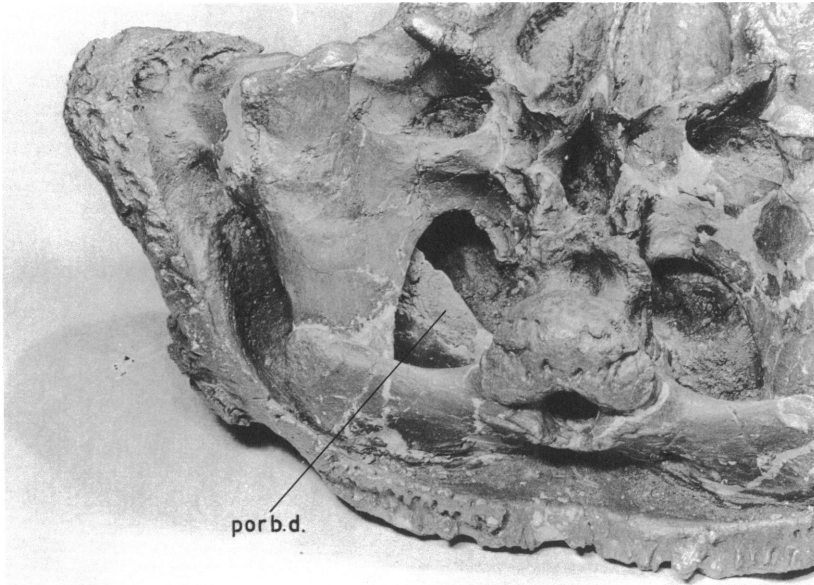


FIG. 1. Oblique view (A.M.N.H. No. 5337). Right posteroventral corner of skull. Quadrate articulation at left top. Between paroccipital process and descending branch of the quadrate, oblique postorbital partition wall is seen; it separates pseudotemporalis group (in front) from deeper parts of adductor externus group.

*Abbreviation:* porb.d., postorbital division.

the adductor mandibulae externus superficialis (1b) might reach such areas. Before deciding on this matter, the other, more normal, insertional areas should be considered. The retroarticular process of the mandible is invariably the area of insertion for a depressor (opener) of the jaw in reptiles; this condition prevails in the ankylosaurs, as might be expected. At the posteromedial part of the jaw the coronoid rim, a triangular prearticular field, and the medial-posterior face of the mandible, even possibly including the interior of a wide, intramandibular canal, form the admissible areas of attachment for adductors. Muscular scars are distinguishable here and are, in most cases, clearly ascribed to specific muscles (see below). The areas of origin, however, are much more controversial because of the peculiar topography of the temporal region in relation to the mandible in these reptiles. Discussions about position of muscular origins from the interior of the secondarily closed temporal area are complicated by a peculiar, rather deep bony shelf (postorbital

division, fig. 1) linked dorsally with the skull roof, and emerging from the posterior part of the otic region. I shall call it the postocular shelf, because in front of it the bulbus and eye muscles, probably including a Harderian and/or lacrimal gland, were accommodated. Because the exits of the trigeminal emerge in front of this shelf, and the pseudotemporalis group (or single muscle) has to rise in front and above the  $V_3$  exit, this muscle or pair of muscles had of necessity to emerge from the gap in front of the postocular shelf in order to reach the inner face of the mandible (see below). We shall have to recognize the possibility of more

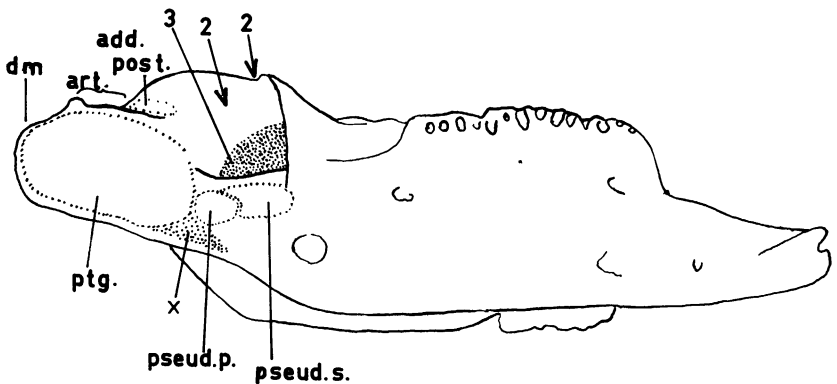


FIG. 2. Medial view (A.M.N.H. No. 5337). Left mandibular ramus. Two muscular scars are shown under deep primordial fossa (insertions of pseudo-temporalis group); the insertion of the pterygoideus muscle complex is shown caudally; in front of the articular surface is scar of the adductor posterior, or a corresponding posterior part of adductor externus profundus.

*Abbreviations:* add.post., adductor posterior; art., articular; dm., depressor mandibulae; pseud.p., pseudotemporalis profundus; pseud.s., pseudotemporalis superior; ptg., pterygoid muscle.

jaw muscles emerging from a position in front of this osseous ledge. A considerable, if not the main, part of the jaw adductors had its origin, therefore, in the space behind this shelf and in front of the otic process of the quadrate, reappearing in front of the quadrate-mandibular joint and reaching the mandible in this way. The available space for such muscles is surprisingly small, but is nevertheless larger than the available space facing the lower jaw that projects into the anterior compartment in front of the postocular shelf. We have to include, however, as possible areas of origins for deep (or posterior) adductors, the anterior face of the quadrate above the mandibular joint (fig. 6).

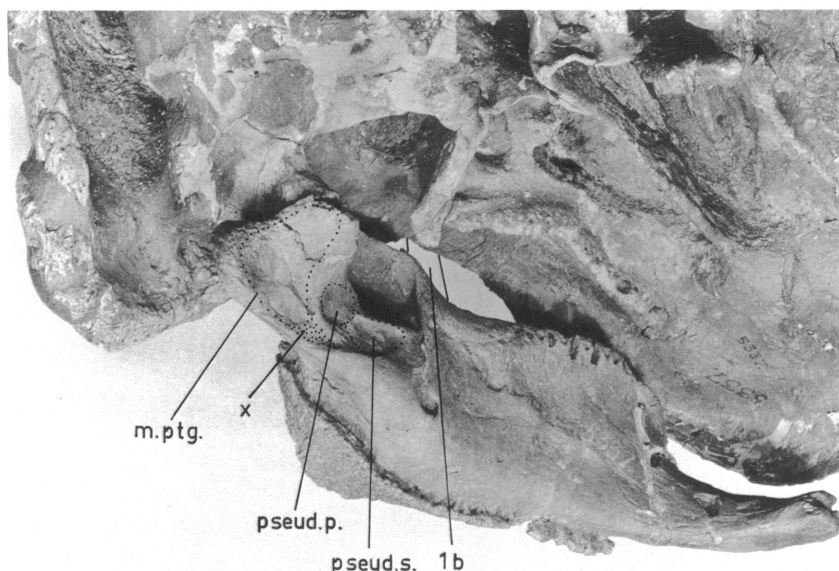


FIG. 3. The same specimen (A.M.N.H. No. 5337) with mandibular ramus in more or less natural position. Several muscle scars are shown.

*Abbreviations:* m.ptg., musculus pterygoideus; pseud.p., pseudotemporalis profundus; pseud.s., pseudotemporalis superior; 1b, m. adductor mandibulae externus superficialis.

It cannot be stated with certainty whether only the adductor posterior, as well as deep portions of the adductor externus profundus, also followed this path. We can be sure that the pterygoid muscle rose from an area starting from the ectopterygoid prominence onto the caudal wing of the pterygoid, and (questionably) from areas anterior to the pterygoid wing of the quadrate lamina facing laterally. A fairly large muscular scar area, clearly divided into a smaller, more medial and a larger lateral field lies suborbitally opposite the jutting apex of the ectopterygoid. This area most probably formed the origin of the externalmost adductors, with possibilities of an insertion at the posterolateral surface of the jaw; such a position (figs. 4 and 5) would place the (fleshy) angle of the mouth in front of the anterior margin of the orbit and enable a levator anguli oris to raise this part dorsally toward the external origin scar. I believe that this external position of such a muscle group (rather atypical for a reptile) has a high degree of probability in ankylosaurs. The akinetic skull of the ankylosaurs retains, of course, nothing of a levator and protractor pterygoidei, but a retractor bulbi dorsalis certainly did survive as the

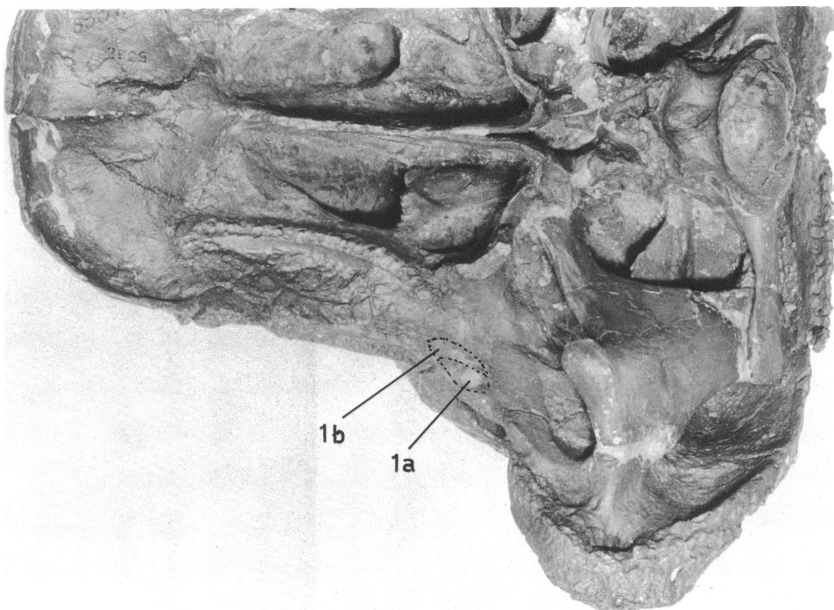


FIG. 4. Ventral view (A.M.N.H. No. 5337), indicating suborbital and pre-orbital scars of the levator anguli oris and the adductor externus superficialis.

*Abbreviations:* 1a, m. levator anguli oris; 1b, m. adductor mandibulae externus superficialis.

remaining part of the constrictor internus dorsalis (V) group. It probably rose internal to the pseudotemporalis origin and, therefore in front of the postocular shelf (fig. 6).

Following these general remarks, more precise areas for single muscles can be given.

**LEVATOR ANGULI ORIS (1a):** Lies vertically, toward the inner rictal plate and its dorsal transition into the outer one; origin from the outer muscular scar seen suborbitally and pointing toward the caudal end of the maxillary cutting margin. It is also possible that this muscular scar was shared by a 1b muscle (adductor mandibulae externus superficialis) of a more complicated, split nature, affixed internally to the 1a (fig. 5).

**ADDUCTOR EXTERNUS SUPERFICIALIS (1b):** See remark on subocular muscular scar. A muscular scar depression medial to the 1a scar certainly formed the origin, or (see above) at least the partial origin, of this important muscle, probably widely expanded at the external face of the lower jaw—from the coronoid “elevation” laterad and latero-

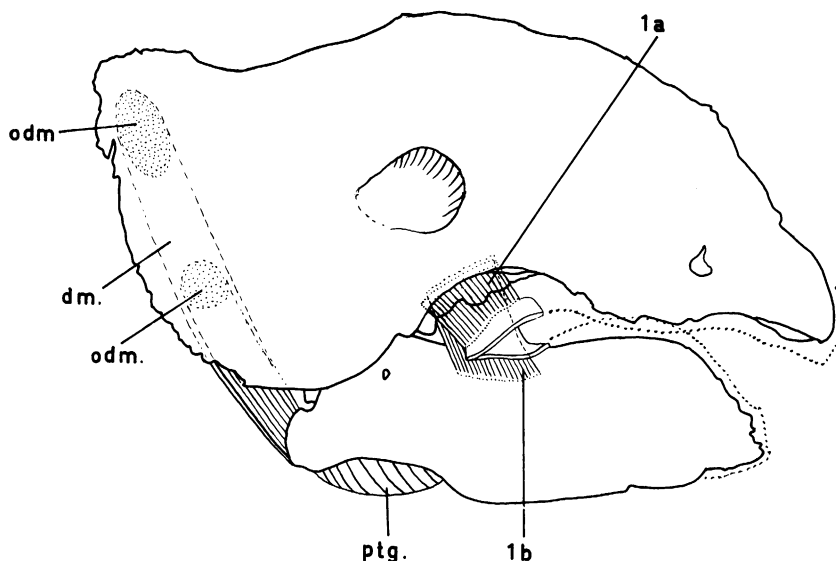


FIG. 5. Lateral view (A.M.N.H. No. 5337), with position of levator anguli oris, m. adductor mandibulae externus superficialis, and depressor mandibulae.

*Abbreviations:* adm., origin of m. depressor mandibulae; dm., depressor mandibulae; ptg., pterygoid muscle; la, m. levator anguli oris; 1b, m. adductor mandibulae externus superficialis.

ventrad into the osteodermal margin dorsally and cranially up to the abrupt border between the posterior smooth and the anterior corrugated area (the anterior half of the ramus). Mainly the coronoid, surangular, and posterior (smooth) part of dentary would be the area of insertion. Obviously, this lateral expansion would not transgress the nerve foramen in the surangular, which is clearly visible in profile view (drawn much narrower in fig. 5).

**ADDUCTOR MANDIBULAE MEDIALIS AND PROFUNDUS:** This complex pointed, in general, toward the inner face of the lateral wall and the "antrum" (intramandibular groove-fossa primordialis) is here deep and well developed (fig. 6). We have, therefore, to assume a deep intramandibular penetration of cranio-ventral parts of this muscular complex (probably the more internal, profundus component), whereas the lateral mandibular bladeliike elevation, up to the lateral circumference of the fossa, would probably harbor the shorter-fibered medialis component. From this complex insertional field, fibers would converge into the anterior part of the slot-shaped compartment between the ascending main

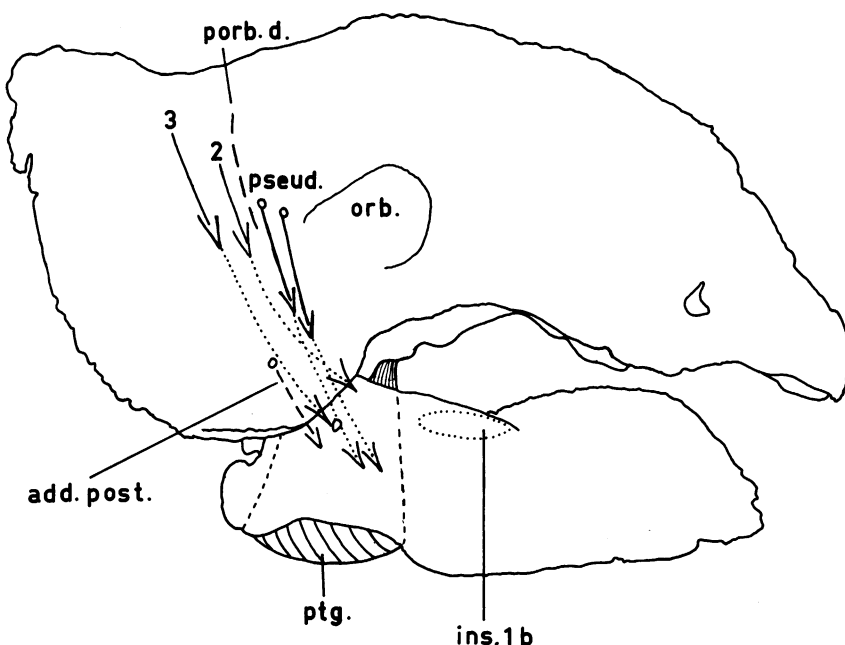


FIG. 6. Lateral view (A.M.N.H. No. 5337). Skull and mandible. Positions of the pseudotemporalis group, the postorbital bone division, and position of the adductores externi medialis, profundus, and adductor posterior, are indicated.

*Abbreviations:* add.post., adductor posterior; ins. 1b, insertion of the adductor mandibulae externus superficialis; orb., orbit; porb.d., postorbital division; pseud., pseudotemporalis; 2, m. adductor mandibulae externus medialis; 3, m. adductor mandibulae externus profundus.

(otic) ramus of the quadrate, but would mainly follow the posterior face of the postocular osseous lamina—probably even partly rising from this partition. A portion of this muscular complex probably arose from the inner face of the postorbital and temporal roof.

Posterior and ventral to the entrance of the primordial fossa, the caudal part of the mandible shows clearly a triple muscular scar (fig. 2); the biggest and most caudal of these (under the jaw joint) of arched contour, certainly formed the insertion of a powerful pterygoid muscle group. The meaning of the two successive anterior ones is open to discussion (see p. 9) but indicates a double pseudotemporalis muscle.

DESCENDING PROCESSES OTICUS QUADRATI: Certainly formed an extended origin surface for a powerful adductor posterior, the insertion of



which, in front of the articular facet, a triangular area, left a clear mark on the upper face of the articular (figs. 2 and 7).

**ADDUCTOR INTERNUS SYSTEM:** Its insertional mark at the above-mentioned triple scar is clearly seen. As we have concluded that the pseudotemporalis muscle had to emerge from the anterior compartment of the postocular shelf in connection with the anterior location of the trigeminal exit from the skull, it seems logical to ascribe the anteriormost and middle scar to the insertion of this single, or more probably, double muscle (pseudotemporalis superior + profundus). Such an assumption would allot the big posterior scar to a rather complex pterygoideus muscle (?dorsalis and ventralis). The anterior part of this muscle (?dor-

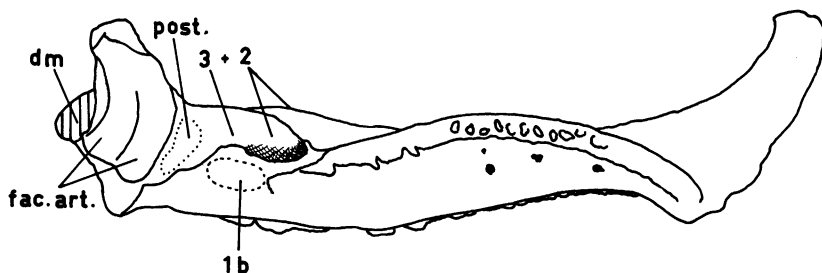


FIG. 7. Dorsal view (A.M.N.H. No. 5405). Mandible. Several muscular insertions are indicated.

*Abbreviations:* dm., depressor mandibulae; fac. art., articular facet; post., m. adductor posterior; 1b, m. adductor mandibulae externus superficialis; 2, m. adductor mandibulae externus medialis; 3, m. adductor mandibulae externus profundus.

salis) points toward the external angle of the ectopterygoid, whereas the much larger posterior part faces the pterygoid and the pterygoid wing of the quadrate, as probable origin areas for the pterygoideus ventralis, which formed the typical ventral masticatory bulge under the caudal part of the jaw (fig. 5).

An alternative explanation would restrict the insertion of a single pseudotemporalis muscle to the most rostral muscle scar, and refer the second (small) insertional scar to a pterygoideus dorsalis rather than to a second part of the pseudotemporalis muscle. I believe, however, more in the correctness of the first interpretation, which favors a superposition of two more or less separated pterygoideus portions that have one single insertional scar.

Both muscles had an almost transverse direction owing to the short-

ness of the whole "muscular area."

**DEPRESSOR MANDIBULAE:** No special problem exists concerning the location of this muscle. It arose from the posterodorsal and posterolateral part of the cranial roof, laterodorsal to the paroccipital process, and lateral to it, and converged toward the upper face of the short processus retroarticularis of the mandible. In this way a space between the posterior slope of the quadrate and the anterior surface of the muscle left room for the tympanic cavity and the stapes (not preserved), which bulged into it (see fig. 5).

### THE TEETH AND BEAK

The reduced and feeble dentition of the ankylosaurs was certainly not very effective, and most probably was surpassed in importance by the mechanically more efficient horny cover, principally of the anterior-most parts of the upper and lower jaws. The horn-covered area in the lower jaw was restricted to the anterior inwardly bent, predental area. In contrast, the outer maxillary and premaxillary margins probably had for a considerable length a horny sheath which, in the premaxillary region, was almost certainly in the nature of a real beak.

The arched lower dental series fits into a deep furrow, flanked externally by the horny, and internally by the dentiferous, flanges of the upper jaw (maxillary) the dental series of which is therefore considerably shifted inwards and remote from the cutting external maxillary blade (fig. 4).

### DISCUSSION

The arrangement of the jaw muscles in a secondarily closed skull, as in the case of the ankylosaurs, suggests the possibility for an extension and redistribution of the narrowed normal fields of origin. For example, there are the suborbital and marginal origins of the adductor externus superficialis group, consisting of a levator anguli oris (1a) and a superficialis (1b) proper. A similar and very striking enlargement of a field of origin is seen at the posterior inner and dorsal face of the cranial roof, which shows extensive muscle scars for the attachment of the depressor mandibulae. The peculiar postocular shelf separated the pseudotemporalis group and the levator bulbi dorsalis (together with eye muscles, bulbus oculi, and attached glands) from the rest of the adductor group, which was lodged in the more caudal compartment, together with a posterior adductor. Except for a considerable shortening in anteroposterior extent, the pterygoideus group of muscles was not deeply affected by the changes in the cranial roof. It is of course impossible to guess

about the size and extent of a nuchal portion of the depressor mandibulae, which certainly was present.

The whole muscular system in the ankylosaur skull was not very strong for such a massive skull. The reduced lateral teeth and the toothless anterior area of the jaws, most probably covered by horny sheaths, indicate that these dinosaurs probably ate relatively soft vegetable food.

The subocular external muscle group (levator anguli oris and adductor externus superficialis) which, because of its abnormal position, considerably narrowed the width of the gape and possibly even allowed for some suction of soft or juicy vegetable matter. But such an assumption is presented here only as an indication of a possibility.

#### REFERENCES

- HAAS, G.  
1955. The jaw musculature of *Protoceratops* and in other ceratopsians. Amer. Mus. Novitates, no. 1729, pp. 1-24.  
1963. A proposed reconstruction of the jaw musculature of *Diplodocus*. Ann. Carnegie Mus., vol. 36, art. 13, pp. 139-157, illus.
- LAKJER, T.  
1926. Studien ueber die trigeminus-versorgte Kaumuskulatur der Sauropsiden. Copenhagen, C. A. Reitzel, 154 pp., 26 pls.

