

# AMERICAN MUSEUM *Novitates*

PUBLISHED BY THE AMERICAN MUSEUM OF NATURAL HISTORY  
CENTRAL PARK WEST AT 79TH STREET, NEW YORK, NY 10024  
Number 3681, 70 pp., 41 figures March 4, 2010

## Morphology of the Braincase in the Cretaceous Hybodont Shark *Tribodus limae* (Chondrichthyes: Elasmobranchii), Based on CT Scanning

JENNIFER A. LANE<sup>1,2</sup>

### ABSTRACT

The braincase of the Lower Cretaceous hybodont shark *Tribodus limae* is examined using high-resolution CT scanning, and its internal and external morphology is described based on three-dimensional digital reconstructions. This study represents the first in-depth examination of a hybodont braincase using CT scanning and digital imaging technology. The braincase of an additional Lower Cretaceous hybodont, *Egertonodus basanus*, is also digitally reconstructed and compared to *Tribodus*. A reconstruction of cranial nerves and blood vessels in *Tribodus* is presented on the basis of preserved foramina. The braincase of *Tribodus* shares many features with those of *Egertonodus* and neoselachians, providing further support for the sister-group relationship between hybodonts and extant elasmobranchs. CT scans confirm that in both *Tribodus* and *Egertonodus* the glossopharyngeal and vagus canals converge and exit from a common foramen (also found in *Chlamydoselachus*). In both of the hybodonts examined, the trochlear nerve exits the braincase anterior to the optic nerve, a possible hybodont synapomorphy. Separate foramina for the two rami of the octaval nerve are present in both *Tribodus* and *Egertonodus*, and may represent an additional hybodont synapomorphy. Also, both taxa have three separate foramina for the trigeminal, facial, and anterodorsal lateral line nerves, apparently including an individual foramen for the superficial ophthalmic complex. However, the basicranial arterial system in *Tribodus* differs considerably from that of *Egertonodus* in that in the former the internal carotid arteries enter the braincase much farther posteriorly and through paired foramina rather than a single median foramen. The median ventral basicranial process in *Tribodus* is similar in structure and position to median ventral processes seen in some extant neoselachians (e.g., *Etmopterus*) and in embryonic *Torpedo* (although in the latter this structure disappears during development), and thus may have had a similar ontogenetic origin.

<sup>1</sup> Division of Paleontology, American Museum of Natural History (jlane@amnh.org).

<sup>2</sup> Department of Biology, the Graduate Center, City University of New York, 365 Fifth Avenue, New York, NY 10016-4309.

## INTRODUCTION

Interrelationships of extinct chondrichthyans have only recently begun to be understood with clarity. Knowledge of fossil chondrichthyan cranial morphology, in particular, was impeded until recently by a lack of well-preserved material as well as the means to examine the few that did exist without destroying the specimens in the process. Serial grinding/sectioning techniques (e.g., Stensiö, 1927; Poplin and de Ricqlès, 1970; Jarvik, 1980) were once the methods of choice for examining fossil shark braincases, and were still widely used until fairly recently (e.g., Schaeffer, 1981). These methods resulted in numerous slabs or slices that make it difficult to reconstruct the original three-dimensional fossil, although they provided the best view of internal structures then available.

It is only in the past decade that CT scanning technology has provided a breakthrough in paleontological studies, allowing intact fossil neurocrania to be examined without damage to the specimens. Fossil chondrichthyan braincases recently investigated with the aid of CT scanning now include *Cladodoides wildungensis* (Maisey, 2005) and symmoriiforms (e.g., “*Cobelodus*”: Maisey, 2007). Moreover, the extant shark *Notorynchus cepedianus* has also been examined using CT scanning (Maisey, 2004b), providing valuable information on the relationship of soft anatomical cranial features to skeletal morphology, as well as a control for interpreting the reliability of CT scanning of fossil taxa. In addition, studies of well-preserved fossil chondrichthyan braincases not based on CT scans (e.g., *Pucapampella*: Maisey, 2001b; Maisey and Anderson, 2001; *Orthacanthus* and *Tamiobatis*: Schaeffer, 1981; *Egertonodus basanus*: Maisey, 1983; *Hybodus reticulatus*: Maisey, 1987; *Synechodus*: Maisey, 1985; *Akmonistion*: Coates and Sequeira, 1998) have provided additional information of value for comparative studies.

However, CT scanning of fossil chondrichthyan braincases is a relatively new field of study, and due to a number of factors (e.g., cost, time, effort involved in CT-scan based studies, and rarity of appropriate specimens), many taxa have yet to be examined. Hybodont sharks, considered the extinct sister group of

extant elasmobranchs (neoselachians), are one such group.

Among hybodonts, relatively complete neurocrania are known in only a few taxa, including *Hybodus reticulatus* (Maisey, 1987), *Egertonodus basanus* (Woodward, 1889, 1916; Maisey, 1983, 1987), and *Tribodus limae* (Brito and Ferreira, 1989; Brito, 1992; Maisey and Carvalho, 1997). Thus far, only the latter two taxa include specimens that are well enough preserved for CT scanning. However, despite the existence of these potential candidates for CT scanning, no in-depth descriptive studies of these specimens based on CT scanning have yet been carried out, although brief descriptions (mainly in the context of comparative studies of which other taxa were the focus) have been provided (i.e., Maisey, 2004a, 2005).

*Tribodus limae* is a hybodont shark from the Lower Cretaceous (Aptian-Albian) Santana Formation of Northeastern Brazil (Brito and Ferreira, 1989; Brito, 1991, 1992; Maisey and Carvalho, 1997; Lane and Maisey, 2009). It has been placed in the hybodont subfamily Acrodontinae, together with *Acrodus* and *Asteracanthus*, on the basis of dental morphology (Brito, 1992; Maisey et al., 2004). Although *Tribodus limae* is the type species, at least three additional species of *Tribodus* (*Tribodus tunisiensis*, *Tribodus morlati*, and *Tribodus aschersoni*) have been proposed (from southern France and northern Africa, e.g., Werner, 1989, 1994; Maisey, 2000; Cavin et al., 2001; Rage and Capetta, 2002; Vullo et al., 2003; Cuny et al., 2004; Vullo et al., 2005; Capetta et al., 2006), but these are based on fragmentary specimens (mostly isolated teeth). The braincase of *Tribodus limae* was initially described by Brito (1992), based on a specimen lacking most of the ethmoid region and postorbital processes. A better-preserved specimen was reported by Maisey and Carvalho (1997), but was not described in depth. *Egertonodus basanus*, from the Lower Cretaceous (Valanginian–Lower Aptian) of southeastern England, is considered to belong to the unnamed sister group of Acrodontinae, which also contains *Hybodus* (e.g., Maisey et al., 2004), again on the basis of tooth structure.

Endocranial morphology in *Tribodus limae* was briefly described by Maisey (2004a) in a comparative study of fossil and extant chon-

drichthyan endocrania based on CT scans. A braincase of *Egertonodus basanus* was also mentioned in that paper, but was not figured or described in great detail. Maisey (2005) did describe the inner ear of *Tribodus* in considerable detail, and found a number of interesting features of potential phylogenetic significance, including several characters of the skeletal labyrinth associated with semidirectional low-frequency phonoreception in extant neoselachians (e.g., presence of a medial chondrified capsular wall separating the skeletal labyrinth and main endocranial cavity; absence of a crus commune and sinus superior; isolation of the posterior semicircular canal and its preampullary extension to describe an almost complete circuit; presence of perilymphatic fenestrae; out-of-plane orientation of the external canal; and presence of a complete parietal fossa). These may represent further synapomorphies supporting the putative sister-group relationship between hybodonts and neoselachians (Maisey, 2004a).

However, a full description of internal cranial morphology in *Tribodus* and *Egertonodus* has not yet been provided, the interior of the braincase of *Egertonodus* has never been figured in a publication, and the cranial endocast has never been reconstructed in these or any other hybodont. The aim of the present paper is to provide the first detailed description of external and internal cranial morphology in hybodont sharks (*Tribodus* and *Egertonodus*) based on CT scanning and digital imaging technologies. This information will then be used to reconstruct soft anatomical features of *Tribodus* (including the cranial nerves and vascularization) for the first time, and to compare cranial morphology in hybodonts to that of other fossil and extant chondrichthyan taxa.

## MATERIALS AND METHODS

All specimens of *Tribodus* described here are from the Lower Cretaceous (Aptian-Albian) Santana Formation of the Chapada do Araripe, Ceará state, northeastern Brazil, and come from the fossiliferous concretion-bearing layers of this formation. All are referred to the type species *Tribodus limae* (Brito and Ferreira, 1989; Brito, 1992; Maisey

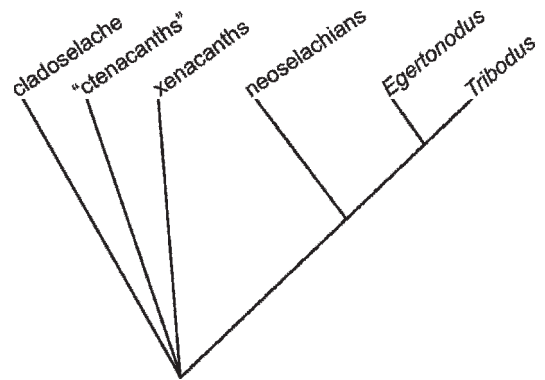


Fig. 1. Phylogenetic relationship of hybodonts (represented here by *Tribodus* and *Egertonodus*) to other representative fossil and extant chondrichthyan taxa. Based on Maisey (1989); Coates and Sequeira (2001); Ginter (2005); Gaudin (1991); and Young (1982).

and Carvalho, 1997). In the present paper, all references to *Tribodus* indicate the type species, which is the only species of *Tribodus* of which articulated skeletal material is preserved. Hybodonts (including *Tribodus* and *Egertonodus*) form a monophyletic sister group to neoselachians (extant sharks and batoids) (Maisey et al., 2004; Coates and Sequeira, 2001). Relationships of *Tribodus* and *Egertonodus* to other representative chondrichthyan taxa are shown in figure 1.

The braincase of AMNH FF 13958 (*Tribodus limae*) is three-dimensional and almost perfectly preserved, with an infilling of carbonate matrix that gives a low-density contrast, with the exception of localized pyritization and small areas lacking matrix. This specimen was scanned and briefly discussed by Maisey (2004a). CT scanning on this specimen was performed by R. Ketcham and M. Colbert, 3/16/1999. Scanning parameters include: 8 bit and 16 bit RLS, 420 kV, 1.8 mA, 2 brass filters, air wedge, 160% offset, gain of 4, integration time 128 ms, slice thickness 0.25 mm, source object distance 630 mm, 2000 views, 4 rays per view, 1 sample per view, scan position 141 mm, interslice spacing 0.25 mm, field of reconstruction 94 mm, reconstruction offset 400, reconstruction scale 500; 8 bit export parameters 2400/1000.

One braincase of *Egertonodus basanus* (NHM P. 60110) was also scanned and briefly discussed by Maisey (2004a). This specimen is

three-dimensional, but partly crushed. Its preservation is in an ironstone matrix, which gives a good density contrast with the prismatic calcification of the specimen. CT scanning was performed by R. Ketcham and M. Colbert, 1/26–27/2001. Scanning parameters include: 16bit RLS, 420 kV, 4.7 mA, on brass filter, empty mount wedge, offset 130%, gain 4, integration time 64 ms, slice thickness 0.25 mm, S.O.D. 595 mm, 1000 views, 5 rays averaged per view, 1 sample per view, interslice spacing 0.25 mm, field of reconstruction 77 mm, reconstruction offset 630, reconstruction scale 448. Detector running average width 5 pixels (skip 1).

Scan data for both *Tribodus* and *Eger-tonodus* was originally exported as TIFF images, and cropped and reprocessed in ImageJ version 1.34s. Contour-based surface reconstruction of both fossils was generated in Imaris X64 version 5.0.2. Three-dimensional images of the braincase of *Tribodus* and *Eger-tonodus* were constructed through contour-based surface rendering of CT slices using Imaris/Surpass software. Illustrations of soft anatomical features were prepared using the computer program Adobe Photoshop Elements version 4.0.

#### MATERIAL OF *TRIBODUS LIMAE*

**HOLOTYPE:** GP/2T-2 IG-USP. Complete fish lacking the caudal fin, figured by Brito and Ferreira (1989: fig. 1A).

**PARATYPE:** DGM-DNPM 1296-P. Skull with first fin spine and associated dermal elements, figured by Brito and Ferreira (1989: fig. 2B).

#### OTHER MATERIAL OF *TRIBODUS LIMAE* EXAMINED

AMNH FF 13957. Acid-prepared, nearly complete fish lacking the caudal fin, figured by Lane and Maisey (2009: fig. 1A).

AMNH 13958. Mechanically prepared, three-dimensionally preserved braincase with mandibular and hyoid arch elements, figured by Maisey and Carvalho (1997: fig. 1); pectoral endoskeleton, figured by Lane and Maisey (2009: figs. 3, 4).

AMNH 13959. Acid-prepared, crushed neurocranium with mandibular and hyoid arch elements and partial pectoral girdle (figured by Lane and Maisey, 2009: figs. 1B, 2).

AMNH 13961. Mechanically prepared partial braincase, anterior dorsal fin, and pectoral girdles, figured by Lane and Maisey (2009: fig. 1C, D).

UERJ-PMB-40. Articulated partial specimen with three-dimensionally preserved head, visceral arch elements, and anterior dorsal fin spine.

UERJ-PMB-114. Articulated partial specimen with braincase and partial visceral skeleton.

UERJ-PMB-119. Articulated partial specimen with braincase, visceral arch elements, dorsal fin spine and fragmentary pectoral girdles.

MN 5808-V (formerly CD-P-106). Nearly complete fish lacking the caudal fin, figured by Brito (1992: fig. 2).

MN 5807-V (formerly CD-P-105). Nearly complete fish lacking the caudal fin, figured by Brito (1992: fig. 1).

#### MATERIAL OF *EGERTONODUS BASANUS* EXAMINED

NHM P.60110. Three-dimensionally preserved braincase with visceral arch elements, figured by Maisey (1983: figs. 4, 5).

NHM 40718. Three-dimensionally preserved braincase with visceral arch elements, figured by Maisey (1983: fig. 2).

NHM P11870. Articulated head with visceral arch elements, figured by Maisey (1983: fig. 6C, D, E)

NHM 6356. Articulated head with visceral arch elements, figured by Maisey (1983: fig. 6A, B).

### ABBREVIATIONS

#### INSTITUTIONAL ABBREVIATIONS

AMNH	American Museum of Natural History, New York
DGM-DNPM	Divisão de Geologia e Mineralogia, Departamento Nacional de Produção Mineral, Rio de Janeiro, Brazil
IG-USP	Instituto de Geociências, Universidade de São Paulo, São Paulo, Brazil
MN	Museu Nacional, Rio de Janeiro, Brazil
NHM	The Natural History Museum, London, UK
UERJ	Universidade do Estado do Rio de Janeiro, Rio de Janeiro, Brazil.

#### ANATOMICAL ABBREVIATIONS

aa	anterior ampulla
acv	anterior cerebral vein
add f	fossa for mandibular adductor muscle
alln	anterodorsal lateral line nerve
ant	antorbital process
asc	anterior semicircular canal
ba	barb on cephalic spine
br	branchial arches



c	crown of cephalic spine	onc	orbitonasal canal (for the orbitonasal vein)
cer	cerebellar region	opa	optic artery
ch	ceratohyal	opha	ophthalmic artery
cik	caudal internasal keel	or	orbit
crd	dorsal crest of cephalic spine	ora	orbital (= stapedial) artery
crl	lateral crest of cephalic spine	otcap	otic capsule
csa	articular process for cephalic spine	pa	posterior ampulla
csb	base of cephalic spine	pac	preampullary canal
csp	cephalic spine	pf	perilymphatic fenestra
da	dorsal aorta	p fos	parietal fossa
den gr	dental groove	pit v	pituitary vein
dfs	dorsal fin spine	popr	postorbital process
ds	dorsum sellae	pq	palatoquadrate
ea	external ampulla	pr.art	possible articular process for preorbitalis muscle
ebra 1	1 <sup>st</sup> efferent branchial artery		
ect	ectethmoid process	prcf	precerebral fontanelle
eha	efferent hyoidean artery	pre	preorbital canal
end f	endolymphatic foramen	prof	profundus nerve
endo	endocranial cavity	psc	posterior semicircular canal
epsa	efferent pseudobranchial artery	pvpr	paired ventral basicranial process(es)
esc	external semicircular canal	qfl	quadrate flange of palatoquadrate
ethpr	ethmopalatine process	rb	rostral bar
ethr	ethmoid region of braincase	rec	external trigeminofacialis recess
fica	foramen for internal carotid arteries	s	striae (cephalic spine)
fm	foramen magnum	sac	saccular chamber
gica	groove for internal carotid arteries	soc	spinooccipital nerves
glda	groove for lateral dorsal aortae	soph	course of superficial ophthalmic complex (trigeminal + anterodorsal lateral line nerves)
gora	groove for orbital arteries		
hd	hypophyseal duct	subs	suborbital shelf
hf	hypophyseal foramen	supc	supraorbital crest
hm art	hyomandibular articulation	t	teeth
hy	hyomandibula	t med	taenia medialis
hyp	hypophyseal chamber	tel	telencephalic region
ica	internal carotid artery	ur	utricular recess
jc	jugular canal	I	olfactory nerve
lab	labial cartilages	II	optic nerve
lag	lagena	III	oculomotor nerve
lda	lateral dorsal aorta	IV	trochlear nerve
lhr	lateral hypophyseal ridge	V, VII	trigemino-facial foramen (contains trigeminal and anterodorsal lateral line nerves in <i>Tribodus</i> and <i>Egertonodus</i> ).
ll	lateral lobe of cephalic spine	V oph	trigeminal nerve component of superficial ophthalmic complex
lm	mesial lobe of cephalic spine	VI	abducens nerve
lotpr	lateral otic process	VII ar	anterior ramule of palatine ramus (facial nerve)
lp	posterior lobe of cephalic spine	VII hm	hyomandibular ramus of facial nerve
mc	Meckel's cartilage	VII pr	posterior ramule of palatine ramus (facial nerve)
mcw	medial capsular wall	VIII	octaval (acousticovestibular) nerve
med	medullary region	VIII a	anterior ramus of octaval nerve
mil	lateral marginal indentation of cephalic spine	VIII p	posterior ramus of octaval nerve
mim	mesial marginal indentation of cephalic spine	IX	glossopharyngeal nerve
mvpr	median ventral process of basicranium	X	vagus nerve
nc	neurocranium	X <sub>d</sub>	dorsal branch of vagus nerve
nt	notochordal canal		
oc art	occipital artery		
oc cot	occipital cotylus		
olf can	olfactory canal		
olfc	olfactory (nasal) capsule		
olln	canal for otic lateral line nerve		

## DESCRIPTION

## SYSTEMATIC PALEONTOLOGY

Class CHONDRICHTHYES Huxley, 1880

Subclass ELASMOBRANCHII Bonaparte,  
1832

Plesion HYBODONTIFORMES Maisey, 1987

Suborder HYBODONTOIDEI Maisey, 1989

Family HYBODONTIDAE Owen, 1846

Subfamily ACRODONTINAE Maisey, 1989

Genus *TRIBODUS* Brito and Ferreira, 1989

*Tribodus limae* Brito and Ferreira, 1989

TYPE SPECIES: *Tribodus limae* Brito and Ferreira, 1989.

DIAGNOSIS: As for the type species, Brito and Ferreira, 1989. Hybodont shark, weakly heterodont. Teeth high crowned not exceeding 5 mm in length, crown with strong vascular striae, deeper than broad in anterior and posterolateral teeth, shallower than broad in anterolateral teeth, root hybodontoid; fin spines slender reaching about 12.5 cm, lateral faces with 8 to 10 sharp continuous ridges, single anterior ridge forming a keel in the anterior border, posterior denticles in two series; large dermal denticles with thornlike shape measuring approximately 2.5 to 3.0 mm.

An emended diagnosis for *Tribodus limae* was provided by Brito (1991), in agreement with that of Brito and Ferreira (1989) except for the following change:

Hybodont shark of approximately 700 mm total length; teeth weakly heterodont [heterodonty is monognathic; possibly also dignathic], higher than broad... tooth crown with striae, deeper than broad in posterolateral teeth and shallower than broad in anterior and antero-lateral teeth; root much more developed than the crown, showing in labial view a central foramen.

## NEUROCRANIUM

GENERAL FEATURES: The neurocranium of *Tribodus limae* was first described by Brito

(1992), who reconstructed it as generally similar in overall morphology to that of *Egertonodus basanus* and other previously described hybodonts. However, that description was based on an incomplete specimen (lacking much of the ethmoid region and postorbital processes), the only material then available (fig. 2). Later, Maisey and Carvalho (1997) announced the discovery of a more complete specimen, AMNH 13958. Although this specimen (fig. 3) was mentioned in several later papers, revealing a selection of intriguing morphological details (Maisey, 2004a, 2005, 2007), a complete description of its morphology has not been presented until now. Additional specimens of *Tribodus limae* neurocrania have since been discovered and are included in the present description (figs. 4, 5). CT scans of the braincase of AMNH 13958 were examined for the present study (figs. 6–9), and were used to produce digitally rendered images of the braincase (figs. 10–14), cranial endocast (figs. 15–18), and skeletal labyrinth (figs. 19–22), described below.

*Tribodus limae* has a platybasic braincase (fig. 10), wedge shaped to trapezoidal in lateral view (fig. 13), in which the dorsal surfaces of the occipital and ethmoid regions slope downward to form obtuse angles with the top of the orbitotemporal region. When viewed under a light microscope, the pattern of prismatic calcified cartilage is visible on the surface of the neurocranium as a thin layer composed of dark brown tesserae, which appear rounded to polygonal in shape. The prismatic cartilage is particularly visible on the ventral surface of the braincase, and in the area surrounding the parietal (= endolymphatic) fossa dorsally. This prismatic pattern is also visible in many of the other cartilaginous skeletal elements in the AMNH specimens of *Tribodus*, except those in which the surface was abraded during preparation (e.g., the jaws of AMNH FF 13958). As in other hybodonts and neoselachians (and unlike many Paleozoic sharks), most of the skeleton is covered with only a single layer of prismatic cartilage, which wraps around to cover both outer and inner surfaces including that of the endocranial space.

In dorsal view (fig. 10) the braincase is weakly triangular, with the otico-occipital

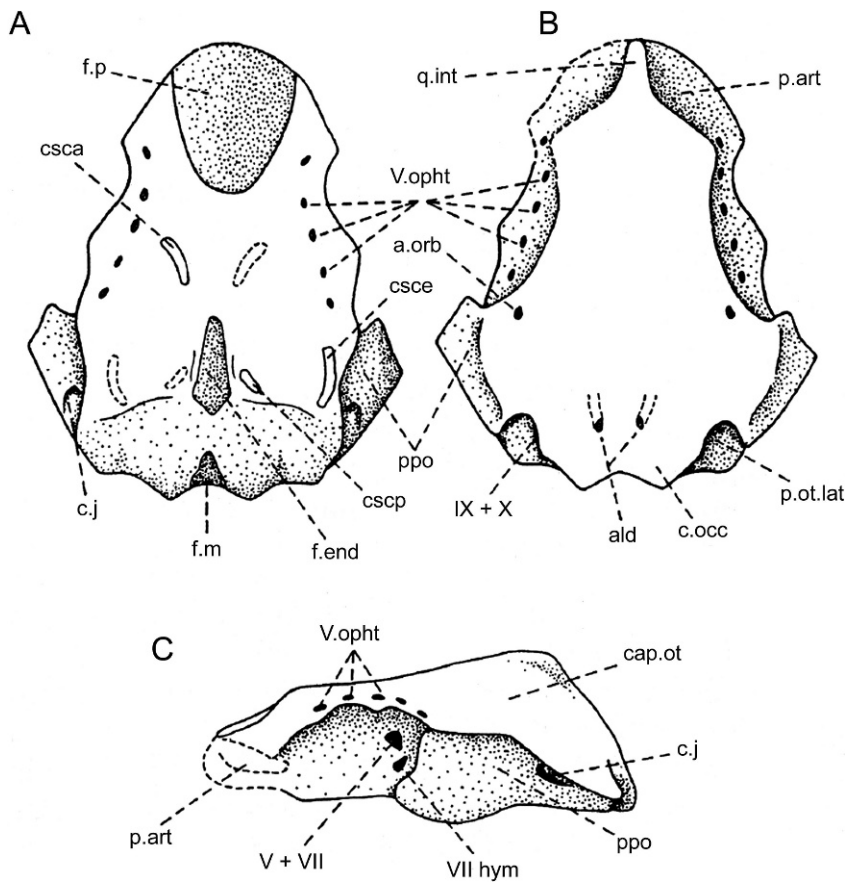


Fig. 2. Reproduction of original illustrations of the *Tribodus limae* braincase, modified from Brito (1992), in **A**, dorsal; **B**, ventral, and **C**, lateral views. Abbreviations (translated from the original French): **ald**, foramina for lateral dorsal aortae; **a.orb**, orbital artery; **cap.ot**, otic capsule; **c.j**, jugular canal; **c.occ**, occipital cotylus; **csca**, anterior semicircular canal; **csce**, external semicircular canal; **cscp**, posterior semicircular canal; **f.end**, endolymphatic (parietal) fossa; **f.m**, foramen magnum; **f.p**, precerebral fontanelle; **p.art**, articular process for palatoquadrate; **p.ot.lat**, lateral otic process; **ppo**, postorbital process; **q.int**, internasal keel; **V.opht**, superficial ophthalmic ramus of nerve V; **V + VII**, foramen for main branch of trigeminal and facial nerves; **VII hym**, foramen for hyomandibular branch of facial nerve; **IX + X**, glossopharyngeal-vagus foramen. Not to scale.

region approximately 1.5 times wider than the ethmoid region. Although the distal parts of the postorbital processes (figs. 10–13: popr) are broken off, their lateral extent can be extrapolated based on the shape of the preserved portion of each process. Based on this, it can be concluded that the widest part of the braincase was across the otic region, rather than between the postorbital processes as in *Egertonodus* (Maisey, 1983). The maximum width of the braincase in *Tribodus* is 88.5 mm, 78% of its total length of 113 mm. As in

*Egertonodus* (Maisey, 1983), the width of the neurocranium is only slightly less than its length.

The margins of the orbits form a more complete oval than in *Egertonodus basanus* (Maisey, 1983), in which the broad forward-pointed postorbital processes give the orbits a more anteriorly directed appearance. A major difference between *Tribodus* and *Egertonodus* is the lack in *Tribodus* of an anteroposterior ventral ethmoidal keel (the “caudal internasal keel”; Maisey, 1983: figs. 9B–D: cik; this paper,

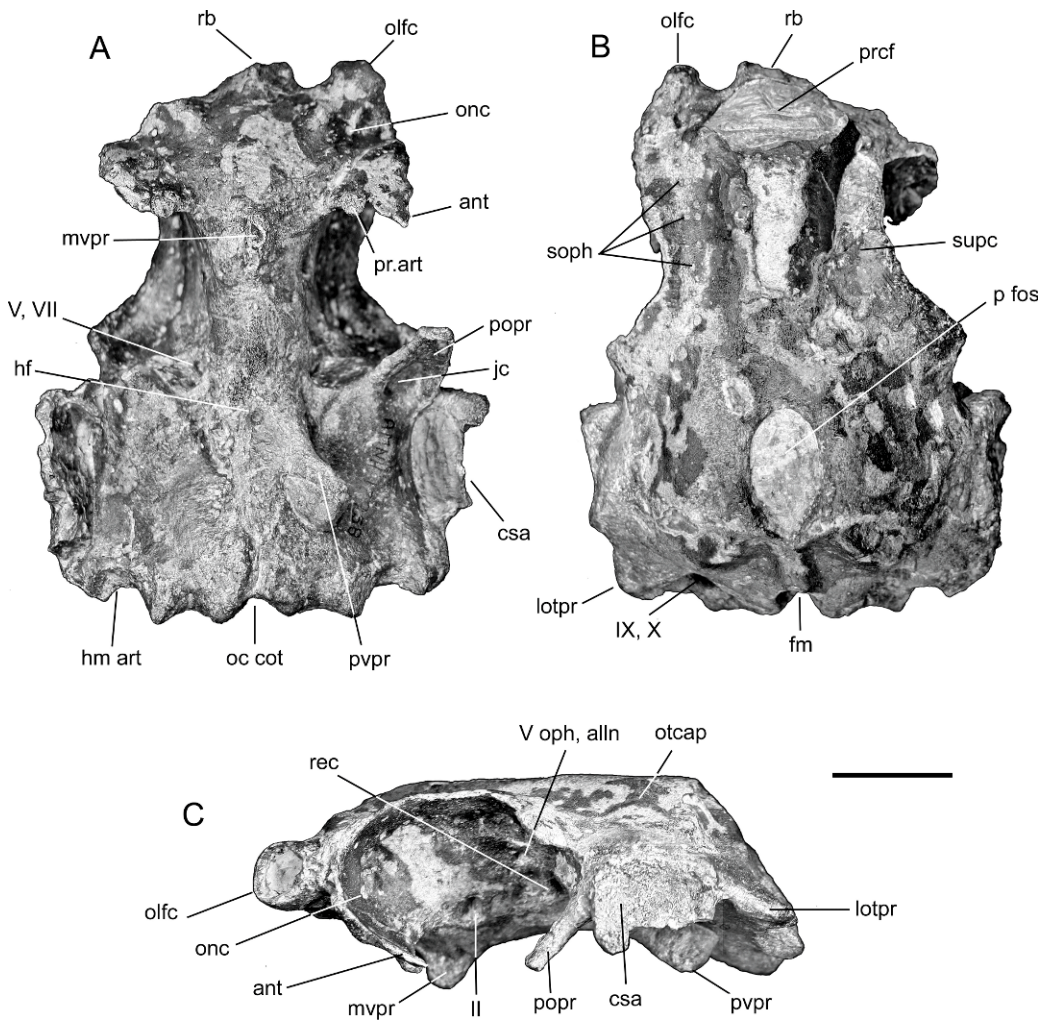


Fig. 3. Braincase of *Tribodus limae*, AMNH FF 13958. **A**, ventral view; **B**, dorsal view; **C**, lateral view. Scale bar is 2 cm.

figs. 29B, 33, 34: cik). Instead, the ventral surface of the ethmoid region in *Tribodus* is smooth and very slightly convex both antero-posteriorly and transversely, and slopes posteroventrally before joining with a median ventral process (fig. 11: mvpr), located between and directly posterior to the antorbital processes. *Tribodus* also lacks the inflated ethmopalatine processes of *Egertonodus*. A raised supraorbital crest is present above the orbits in *Tribodus*. At the widest part of the neurocranium (at the level of the otic capsules) are paired, rectangular, laterally concave structures, which are fibrous and lack prismatic calcification (fig. 3:

csa). These have been identified as the points of articulation for the cephalic spines (Maisey and Carvalho, 1997). The convexly curved cephalic spine bases fit neatly within these concave, bowl-shaped platforms, with the curved distal cusps of the spines directed posteriorly. Elevated ridges on the cranial roof immediately anterior and posterior to the parietal fossa correspond to the positions of the anterior and posterior semicircular canals (cf. *Notorynchus*; Maisey, 2004b). As in *Egertonodus basanus* (Maisey, 1983) and many other hybodonts, the otico-occipital region is "telescoped" forward between the postorbital processes, so that the



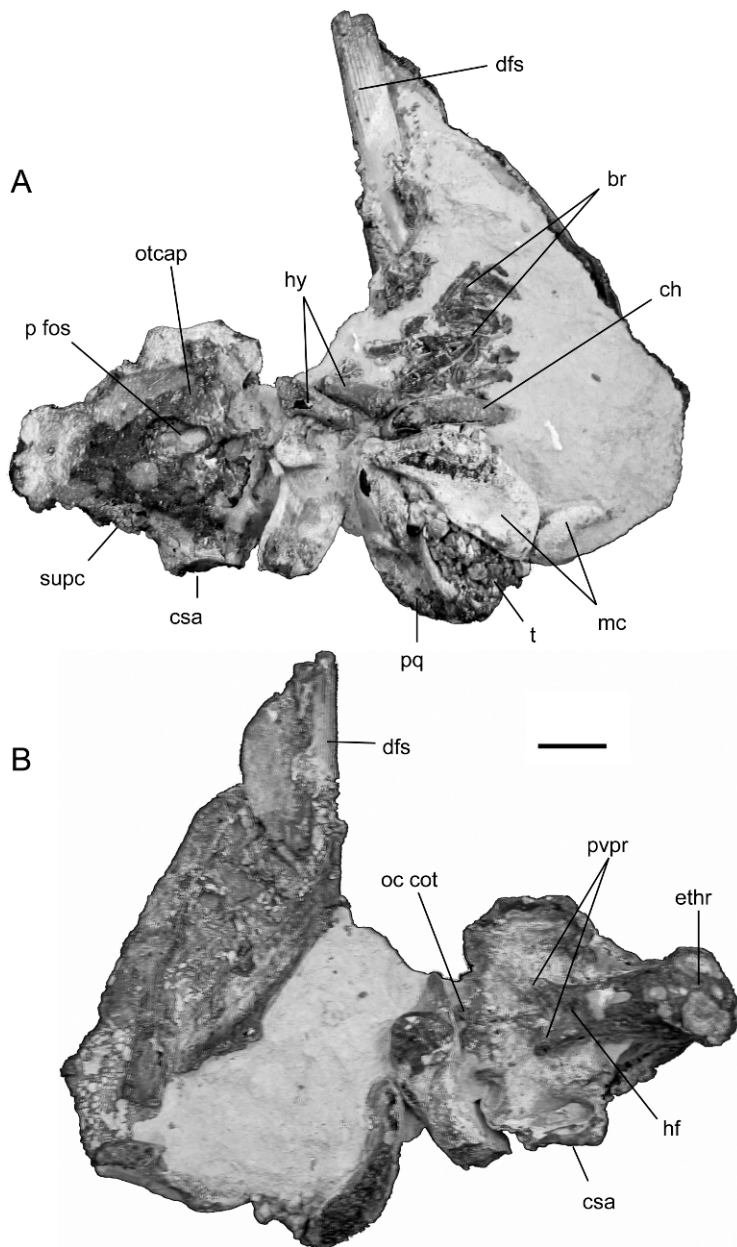


Fig. 4. *Tribodus limae*, UERJ-PMB-40. A, dorsal; B, ventral views. Scale bar is 2 cm.

otic capsules are situated between these processes (unlike many Paleozoic sharks, in which the otic capsules are located behind the postorbital processes). However, in *Egertonodus* the occiput projects somewhat farther posteriorly than it does in *Tribodus* and most neoselachians (cf. Maisey, 1983).

#### ROSTRAL AND ETHMOIDAL REGIONS

**PROPORTIONS OF THE ETHMOID REGION:** The ethmoid region of *Tribodus limae* is proportionally wider across than it is in *Egertonodus basanus*, and the olfactory capsules are more widely spaced. The left olfactory chamber of






Fig. 5. *Tribodus limae*, UERJ-PMB-114. A, dorsal; B, ventral views. Scale bar is 2 cm.

AMNH 13958 is well preserved, and although its interior is filled with matrix, it can be observed via CT scanning (fig. 6A). The right olfactory chamber is not preserved. The ethmoid region of *Tribodus* comprises about one-third of the entire length of the braincase, unlike *Egertonodus basanus* and *Hybodus reticulatus*, in which the ethmoid region constitutes only one-quarter of its length (Maisey 1983, 1987). Maisey (1983) describes the ethmoid region in *Egertonodus* as shorter than in most living sharks, but similar in length to that of *Tristychius*, while in *Cobelodus*, *Tamiobatis*, and *Xenacanthus*, the proportion is even lower (Maisey, 2005, 2007). In the extant shark *Notorynchus* (Maisey, 2004b), the ethmoid region comprises approximately one-third of the total braincase length,

resembling the condition in *Tribodus*. The proportional length of the ethmoid region in *Tribodus* thus more closely resembles that of some extant neoselachians than that of other hybodonts and outgroup chondrichthyan taxa.

**PRECEREBRAL FONTANELLE, ROSTRAL BAR, AND BASICRANIAL PROCESS:** The precerebral fontanelle of *Tribodus limae* is oval in cross section, and is slightly wider across than in *Egertonodus basanus* (fig. 3B, 6A–D). At the anteroventral tip of the precerebral fontanelle, the base of a forward-directed process is visible, although its anterior portion is missing (fig. 3B: rb). This is interpreted as a rostral bar, as in *Egertonodus* (Maisey, 1983). On the ventral medial surface of the rostral bar (fig. 11) there is a small, ventrally directed

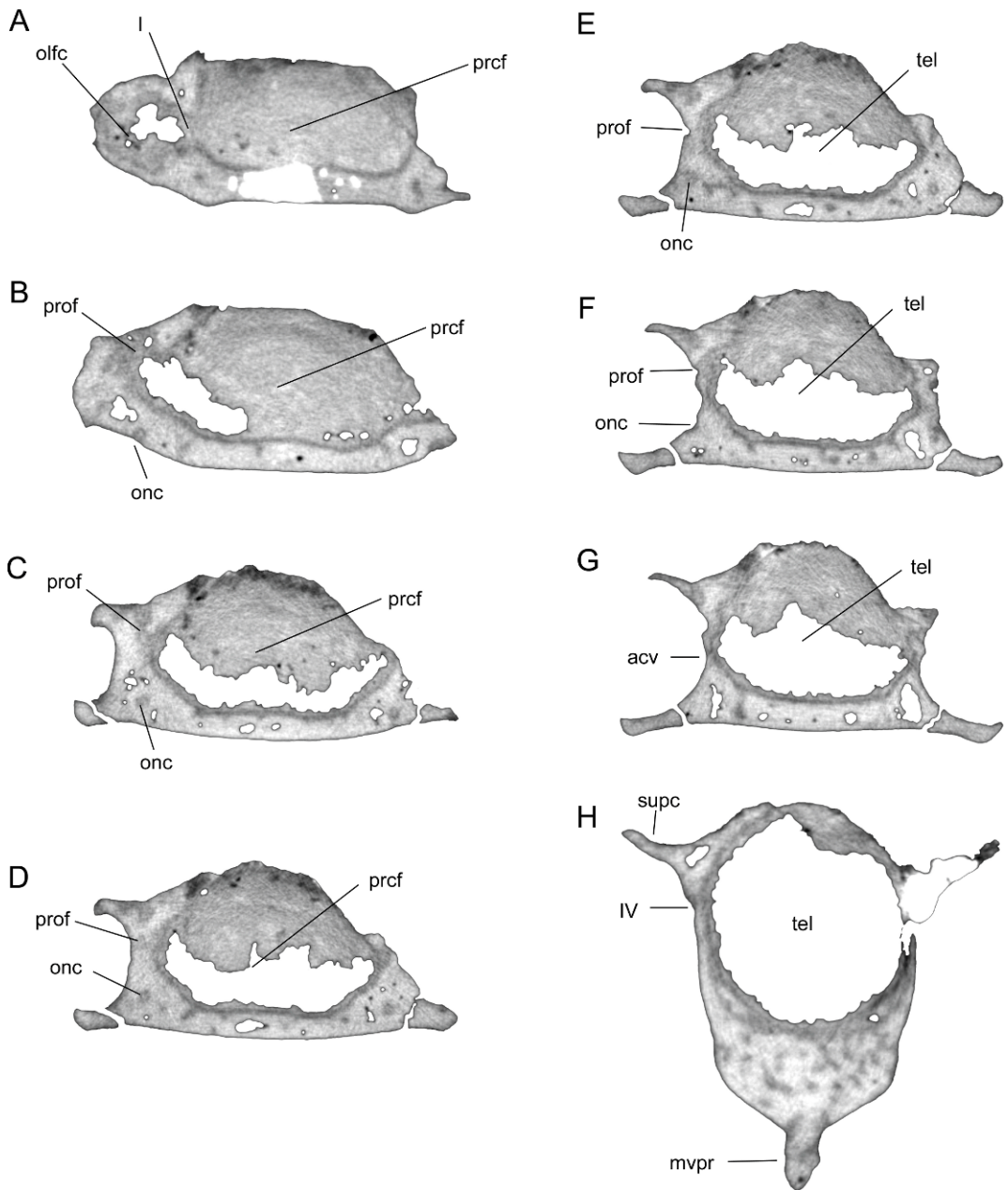


Fig. 6. Transverse CT scan slices of the *Tribodus limae* braincase, AMNH 13958. Ethmoidal region. **A**, slice 57, through the olfactory chamber and precerebral fontanelle; **B**, slice 72, through the precerebral fontanelle showing the ventral exit of the orbitonasal canal; **C**, slice 83, through the precerebral fontanelle showing the orbitonasal canal traveling through the cartilage; **D**, **E**, **F**, slices 87, 89, and 94, respectively, through the precerebral fontanelle showing the course of the profundus nerve and orbitonasal canal; **G**, slice 100, at the level of the anterior cerebral canal; **H**, slice 159, through the anterior of the orbit at the level of the trochlear nerve and median ventral basicranial process. No scale.

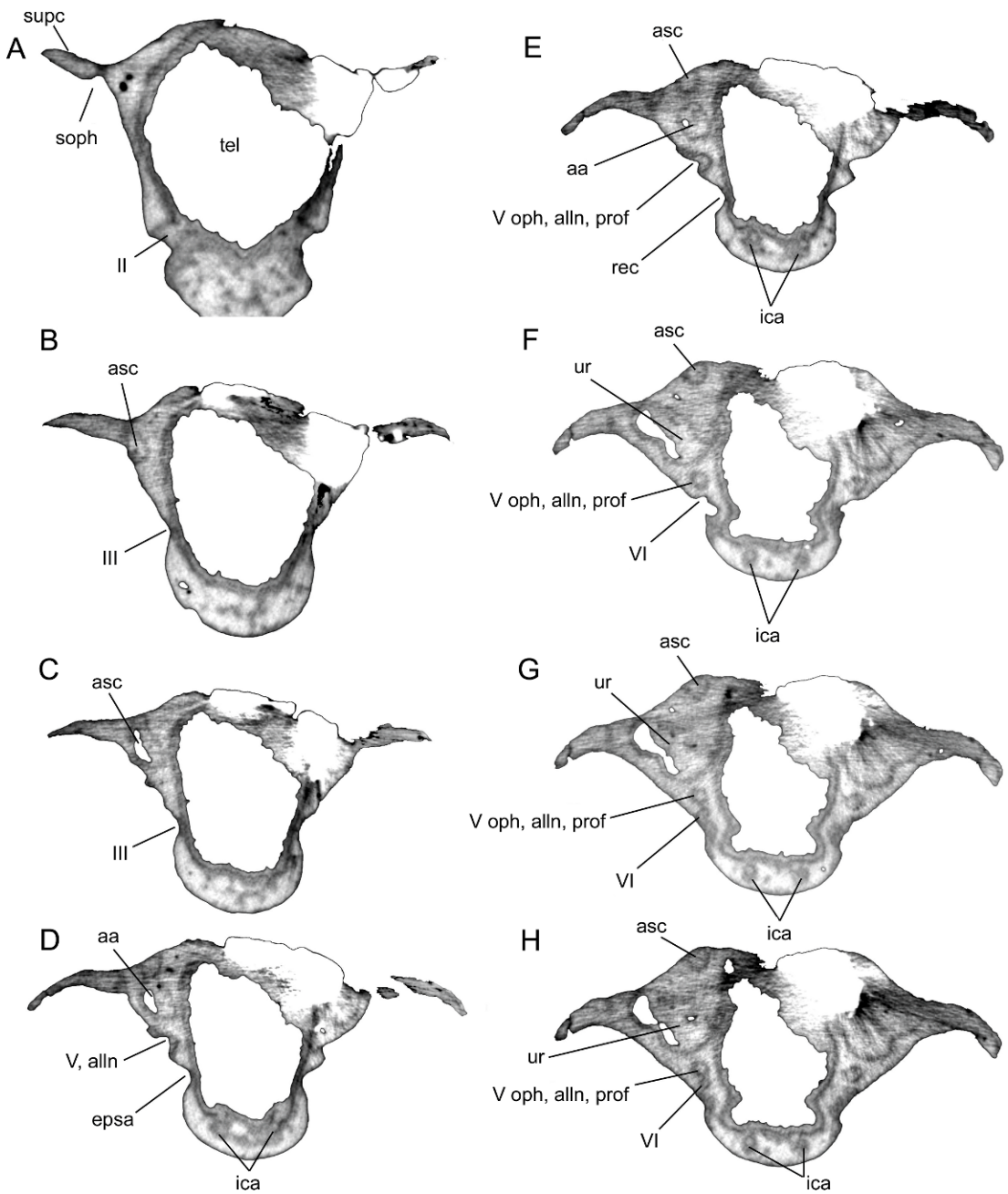


Fig. 7. Transverse CT scan slices through the *Tribodus limae* braincase. Orbital region. **A**, slice 187, at the level of the optic nerve; **B**, slice 209, at the level of the oculomotor nerve; **C**, slice 216, at the level of the oculomotor nerve showing the anterior semicircular canal originating anterior to the postorbital process; **D**, **E**, slices 222 and 226, respectively, at the level of the efferent pseudobranchial foramen and the foramen for the superficial ophthalmic complex and profundus nerve; **F**, slice 239, at the level of the utricular recess and abducens foramen; **G**, **H**, slices 241 and 242, respectively, showing the course of the superficial ophthalmic complex and abducens nerve within the cartilage of the orbit. No scale.

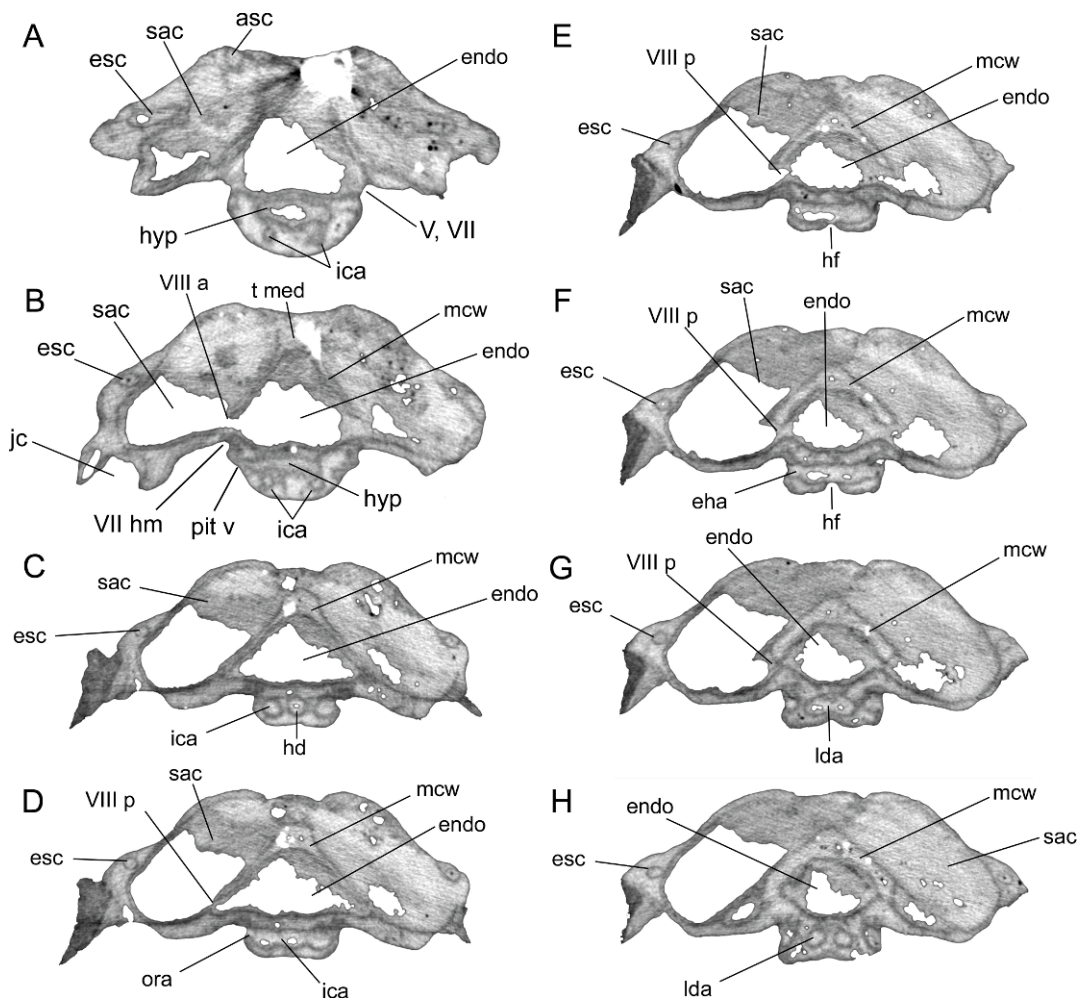


Fig. 8. Transverse CT scan slices through the *Tribodus limae* braincase. Otic region. **A**, slice 257, at the level of the hypophysis and facial nerve; **B**, slice 270, showing the pituitary vein canal and the anterior ramus of the octaval nerve; **C**, slice 285, showing the hypophyseal duct and internal carotids; **D**, slice 290, showing the posterior ramus of the octaval nerve and the exit of the orbital arteries from the braincase; **E**, slice 298, at the level of the hypophyseal foramen; **F**, slice 303, showing the exit of the efferent hyoidean arteries from the braincase; **G**, slice 307, showing the canals for the lateral dorsal aortae converging to form a single chamber medial to the efferent hyoidean foramina; **H**, slice 313, showing the lateral dorsal aortae diverging posteriorly. No scale.

process, which appears V-shaped in frontal view. Posterior to this, the ventral surface of the internasal septum is broad and smooth, without a caudal internasal keel medially or paired ethmopalatine processes laterally such as those described in *Egertonodus* by Maisey (1983: fig.9: cik, ethppr).

Farther posteriorly, a large, medial, ventrally directed process is present on the ventral

surface of the basicranium, originating anteriorly directly between the bases of the antorbital processes and extending posteriorly to just below the anterior margin of the optic foramen (figs. 3, 5, 6, 11: mvpr). This process is located immediately anterior to the anterior margin of the palatoquadrate, as illustrated by UERJ-PMB-114 (fig. 5B). This median ventral process was referred to as the basicranial



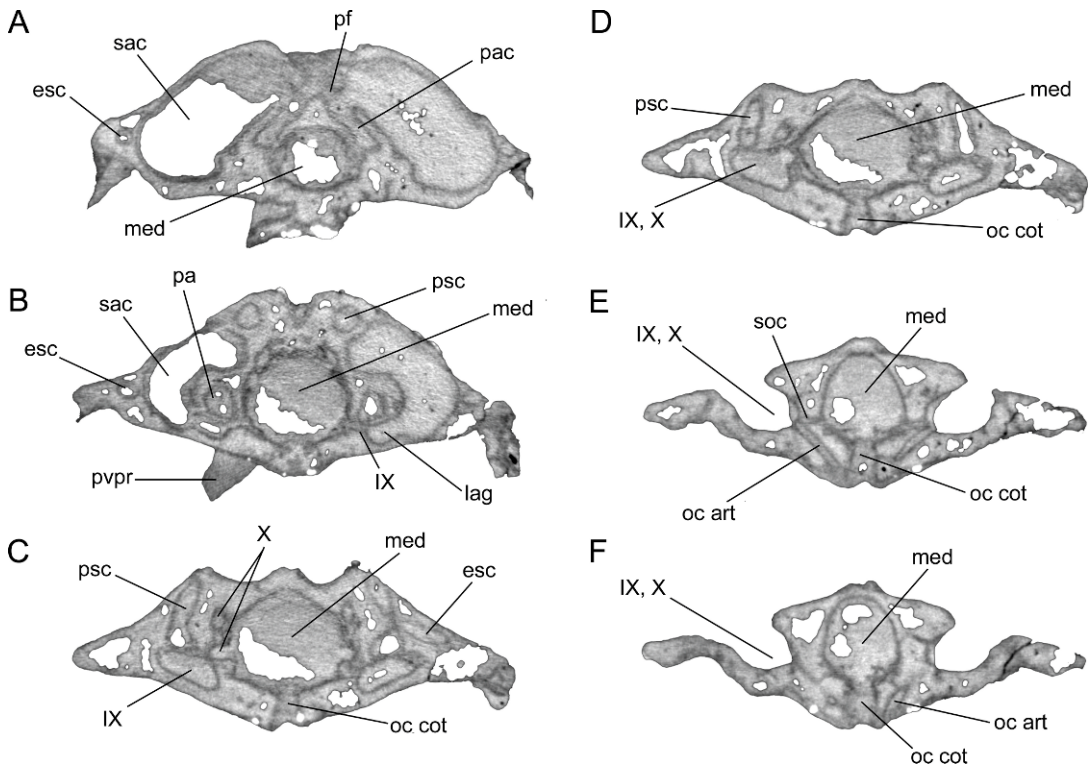


Fig. 9. Transverse CT scan slices through the *Tribodus limae* braincase. Occipital region. **A**, slice 334, at the level of the preampullary canals and perilymphatic foramina; **B**, slice 369, at the level of the posterior ampullae and glossopharyngeal canal; **C**, slice 395, at the level of the vagus nerve; **D**, slice 400, at the level where the vagus canal exits into the glossopharyngeal foramen; **E**, slice 418, showing canals for the occipital arteries and spino-occipital nerves; **F**, slice 423, at the level of the occipital cotylus. No scale.

process by Maisey and Carvalho (1997). It is possible that the basicranial process is homologous to the caudal internasal keel of other hybodonts, due to its ventromedial position and location in the anterior region of the braincase (also originating as an outgrowth of the embryonic trabeculae), and its probable similar involvement in jaw suspension (perhaps as an attachment point for soft tissues involved in jaw support in the case of *Tribodus*, rather than directly abutting the palatoquadrates as in *Egertonodus*). In *Egertonodus* the caudal internasal keel extends from the tip of the rostrum to the anterior margin of the suborbital shelf. This includes the area where the ventral process is located in *Tribodus*, further suggesting that the two structures could be homologous. However, the basicranial process of *Tribodus* differs from the caudal internasal keel of *Eger-*

*tonodus* in its much shorter anteroposterior extent. It is also possible that the median ventral process of *Tribodus* is homologous to a ventral interorbital septum, as in *Squaliolus* (Maisey, 2007), which like the process in *Tribodus* forms a solid wall of cartilage in the basicranium, and is located between the antorbital process and optic foramen.

The median basicranial process in *Tribodus* could alternatively be homologous to the keel process of some modern squalan sharks (e.g., *Centroscyllium*, *Etmopterus*; Maisey, 2007), which also typically terminates immediately anterior to the palatoquadrates and is located between the optic foramen and antorbital process. In extant elasmobranchs, the pre-orbitalis muscle (= suborbitalis of Shirai, 1992; Maisey, 2007) originates at the dorsal end of this process in *Etmopterus* and *Centroscyllium*. According to Maisey (2007),



the interorbital septum of *Squaliolus* is probably not homologous to the keel process of the aforementioned sharks, because the latter forms later in ontogeny and differs in its ontogenetic point of origin. Because *Tribodus* is extinct and its ontogeny is unknown, the exact homology of its median ventral process to similar structures of modern forms remains uncertain. However, due to its location and probable function (confined to the anterior of the orbit between the antorbital processes and optic foramen; immediately anterior to palatoquadrate symphysis; not directly articulating with a forwardly extended palatoquadrate), it seems more likely that this process was homologous to the ventral orbital processes of modern elasmobranchs than to the caudal internasal keel of *Egertonodus*. A similar basicranial process occurs in embryos of the extant batoid *Torpedo*, but disappears later in ontogeny (Holmgren, 1940: fig. 162: m.a.). This process was described by Holmgren (1940: 169) as a “distinct rudiment... corresponding to the posterior part of the medial area in *Etmopterus* and *Squalus*,” and is positioned in front of the palatoquadrate symphysis. In *Torpedo*, this process is continuous with an anteroposteriorly elongated ridge or medial lamella (the “medial area” of Holmgren), which extends from nearly the anterior tip of the braincase to just in front of the palatoquadrate, but later disappears. Interestingly, this elongated ridge covers the same area as the caudal internasal keel of *Egertonodus*. The last part of the ridge to remain during ontogeny is the small, anteroposteriorly compressed median process (the “rudiment” described above), which superficially resembles the median ventral process of *Tribodus*. Whether the “medial area” of *Torpedo* is homologous to the median ventral process of *Tribodus*, and/or the caudal internasal keel of other hybodonts, is uncertain. However, it suggests that the two structures found in hybodonts could be homologues of each other, resulting from similar ontogenetic processes.

As in *Egertonodus* and *Chlamydoselachus*, the anteroventral margin of the precerebral fontanelle in *Tribodus* is defined by the slightly upturned forward part of the internasal septum (Maisey, 1983). The precerebral fon-

tanelle is infilled with matrix, making structures on the interior walls and floor of the fontanelle difficult to examine; however, these structures can be observed with the aid of CT scanning (fig. 6A–D). In a three-dimensional image of the braincase made from CT scans of AMNH 13958, the olfactory nerve foramen is visible as a large opening in the internasal septum connecting the precerebral fontanelle with the olfactory chamber (fig. 14, I). The olfactory nerve canal is visible on the interior of the braincase as an elongated furrow on the ventrolateral wall of the ethmoid region (fig. 14: olf can).

VASCULARIZATION AND INNERVATION OF THE ETHMOID REGION: Allis (1923) and Jarvik (1942) noted three major groups of nerves and blood vessels in the anterior of the orbit in *Chlamydoselachus*: a set of dorsal and ventral foramina within the orbit, and an additional group of structures that pass superficially, lateral to the ectethmoid process (Maisey, 1983). These include the maxillary artery, the facial vein, and two nerve rami: the maxillary ramus of the trigeminal nerve, and the buccal ramus of the facial nerve (now revised as the buccal ramus of the anterodorsal lateral line nerve; Northcutt and Bemis, 1993). Based on comparison with modern elasmobranchs such as *Chlamydoselachus*, Maisey (1983) provided an interpretation of the innervation and vascularization of the ethmoid region of *Egertonodus basanus*. Based on this interpretation and on CT scan images of *Tribodus limae* (AMNH 13958), small, paired foramina on the ventral surface of the internasal lamina (located directly posterior to the nasal capsules and opening into them) are interpreted as anterior openings for the orbitonasal vein canals (figs. 3A, 6B, 11: onc). These connect internally with corresponding small, ventrally located openings in the anterior of each orbit, where the orbitonasal veins presumably exited the orbit (figs. 2C, 6B–F, 11, 13: onc). The positions of these foramina for the orbitonasal vein are consistent with those described in *Egertonodus* and other elasmobranchs (e.g., *Chlamydoselachus* and *Notorynchus*; Maisey, 2004b, 1983; Shirai, 1992; Allis, 1923). Allis (1923) described the orbitonasal vein in *Chlamydoselachus* as originating in the nasal capsule and traversing the ectethmoid cham-

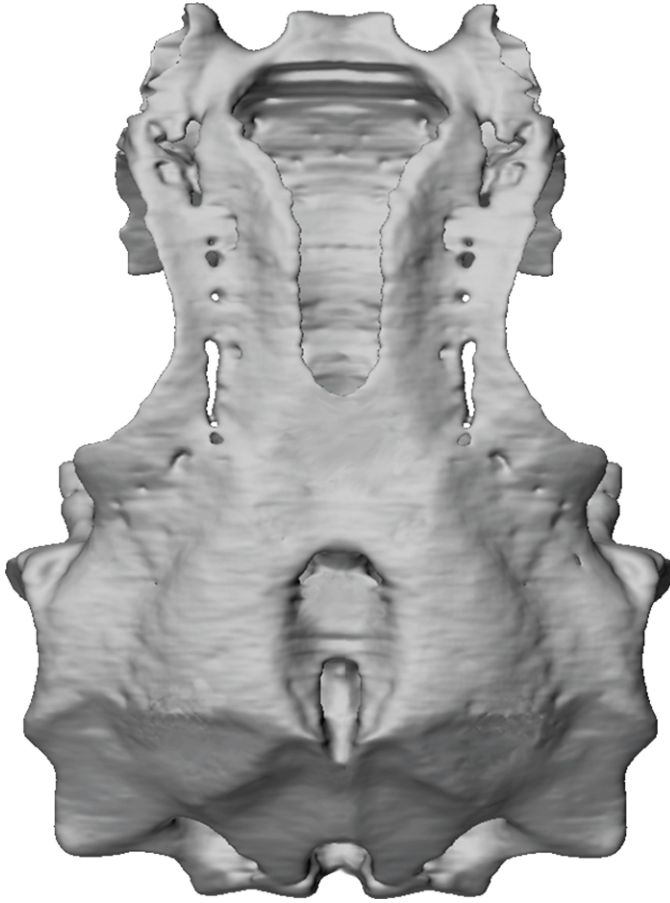

Fig. 10. Dorsal view of the *Tribodus limae* braincase, AMNH FF 13958, anterior at top (surface rendering). No scale.

ber before entering the orbit via the orbitonasal foramen. The positions of the orbitonasal foramina in *Tribodus* are consistent with this description. Based on the inferred position of the orbitonasal canal, the part of the postnasal wall lateral to the orbitonasal foramen in *Tribodus limae* is then the planum antorbitale, or antorbital process (figs. 3A, C, 10–13: ant), originating from the lamina orbitonasalis of the embryonic trabecula, according to the interpretation given by De Beer (1931).

On the ventromedial surfaces of the antorbital processes of AMNH 13958 are small, paired, rounded structures, immediately lateral to a large notch separating the distal end of the antorbital process from the interorbital wall (figs. 3A, 11, 12: pr.art). The rounded shape of these paired structures, together with their lack

of prismatic cartilage distally, indicate that they may have served as an attachment point for muscles or ligaments involved in jaw suspension. There are several examples of extant elasmobranchs in which the antorbital processes serve as muscle attachment sites: the suborbitalis (= preorbitalis, Maisey, 2007) muscle in *Chlamydoselachus*, hexanchoids, and the squalan *Echinorhinus* originates at the tip of the antorbital process, and the adductor mandibularis superficialis muscle in hexanchoids inserts on the antorbital process as well as behind the eye (Shirai, 1992). In extant carcharhinoids, the ventral head of the preorbital (= suborbitalis, Maisey, 2007) muscle originates in the anterior of the orbit or on the posterior of the nasal capsule (Compagno, 1988: fig. 8.1). Interestingly, small rounded

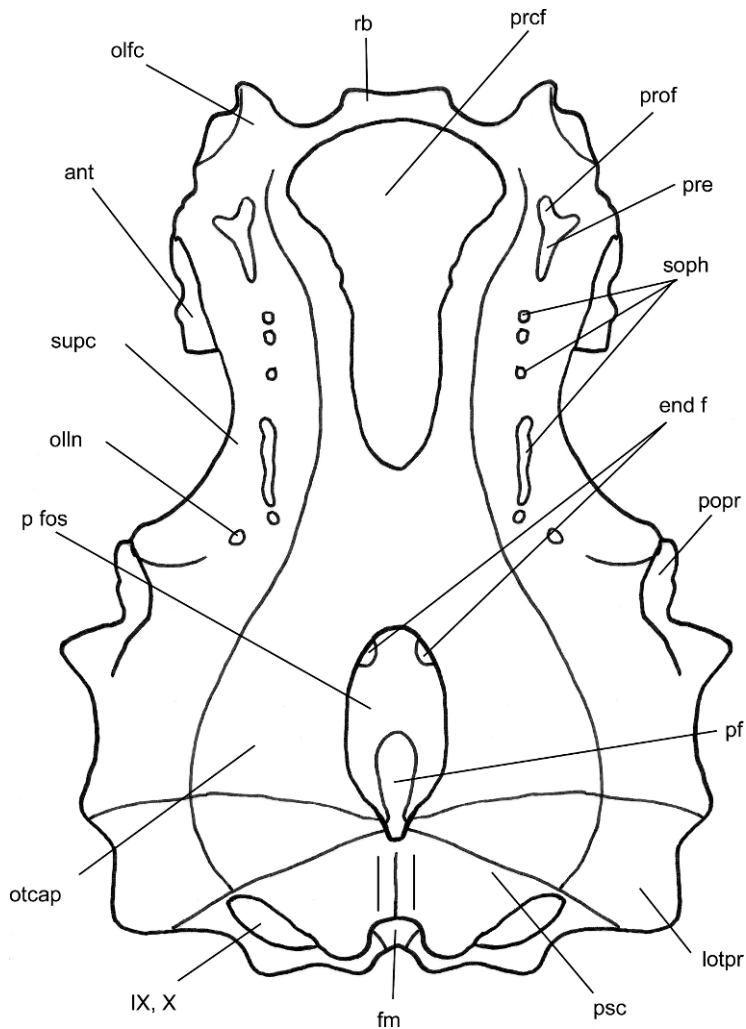


Fig. 10. *Continued.*

processes similar in appearance to those mentioned in *Tribodus* occur on the medial part of the antorbital processes in embryonic *Torpedo* (the “short, caudally directed process” described by Holmgren, 1940: 166, figs. 157, 158). According to Holmgren, these small rounded processes act as insertion points for the musculus depressor rostri, as well as another muscle that Holmgren did not identify (possibly the preorbitalis; cf. Holmgren, 1940: fig. 157).

Immediately lateral to the paired rounded processes is a smaller notch, interpreted here as possibly housing the lateral ramule of the

buccal and maxillary ramus (lr) as in *Notorynchus* (Maisey, 2004b). However, in *Notorynchus*, this ramus is more fully enclosed within the ectethmoid process (Maisey, 2004b). The maxillary artery and facial vein may also have passed through this notch, as these structures have also been described as superficially located along with the buccal and maxillary rami in extant elasmobranchs (Maisey, 1983). As these nerves and vessels generally pass lateral to the ectethmoid process, at least in extant elasmobranchs (Maisey, 1983), the small, rounded, paired processes in *Tribodus* described above (located

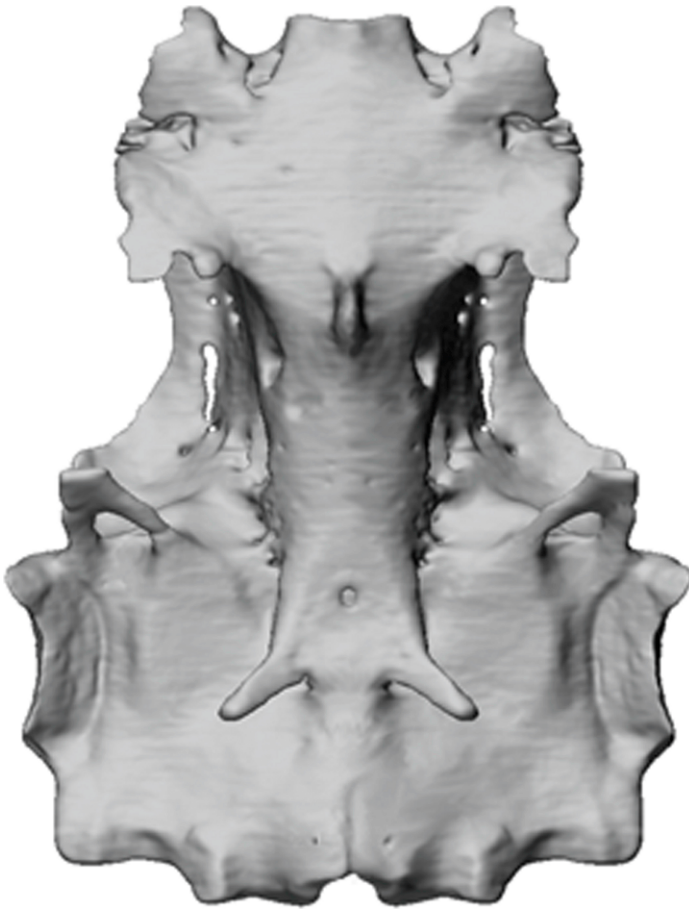

Fig. 11. Ventral view of the *Tribodus* braincase, anterior at top (surface rendering). No scale.

medial to these structures) could be homologous to the ectethmoid processes of other elasmobranchs. Anterior to passing lateral to the ectethmoid process, it is likely that the maxillary artery and facial vein would have passed mesially into the nasal capsule via a small aperture in its lateral margin, as in *Chlamydoselachus* (Jarvik, 1942; Maisey, 1983). *Egertonodus basanus* was described by Maisey (1983) as having an ectethmoid process like that of *Chlamydoselachus*, in the form of a laterally directed, pointed flange extending outward from the anterior edge of the postnasal wall. *Hybodus reticulatus* was also reconstructed as having an ectethmoid process like that of *Egertonodus*, although this part of the specimen was not preserved (Maisey, 1987).

**ORBITONASAL VEIN, ANTERIOR CEREBRAL VEIN, AND PROFUNDUS NERVE:** In the anterior of the orbit are several foramina, the ventral-most of which is considered to have contained the orbitonasal vein (see above). Dorsal to this is an additional foramen, interpreted here as possibly housing the anterior cerebral vein (figs. 6G, 13, 14: acv) as in *Egertonodus basanus* and *Orthacanthus* (Maisey, 1983). The anterior cerebral vein may have exited the orbit through this foramen, which opens into the precerebral fontanelle, and then passed along the interior edge of the fontanelle wall and into the nasal capsule via the olfactory foramen. Alternatively, the anterior cerebral vein may have passed through the profundus foramen alongside the nerve, as in some modern elasmobranchs such as *Chla-*

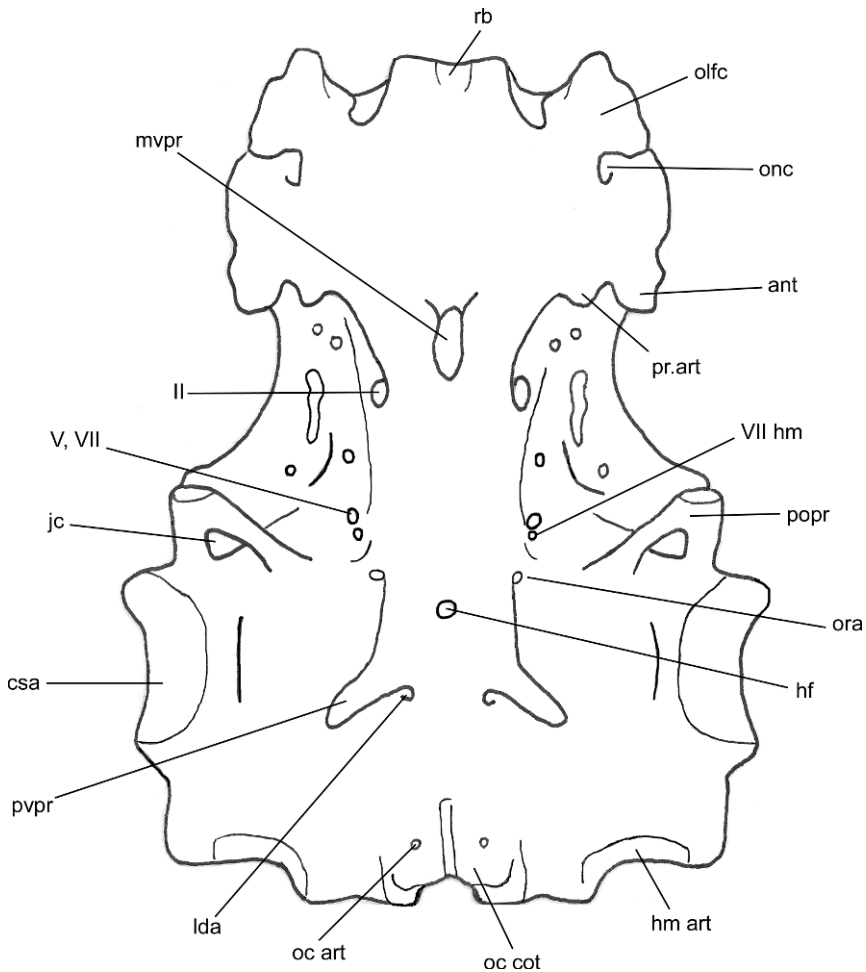


Fig. 11. *Continued.*

*mydoselachus* (Maisey, 1983; Jarvik, 1942), although this would leave this medial foramen (above the orbitonasal foramen and below the profundus foramen) without explanation. According to Maisey (1983), most extant sharks (except *Chlamydoselachus* and *Squatina*) have separate foramina for the anterior cerebral vein, orbitonasal vein, and profundus nerve. Unlike *Egertonodus* (Maisey, 1983), *Tribodus* lacks paired foramina in the floor of the precerebral fontanelle for the anterior cerebral vein.

Dorsal to the foramen for the anterior cerebral vein is an additional foramen, which appears to emerge on the dorsal surface of the braincase posterior to the nasal capsules (figs. 6B–F, 10, 13: prof). This foramen is

here interpreted as housing the profundus nerve. As Maisey (1983) concluded to be the case in *Egertonodus basamus*, it seems unlikely that the profundus nerve passed through the orbitonasal canal, because this canal emerges on the ventral side of the braincase where it appears to enter the olfactory capsule (although according to Maisey, 1983, the possibility of a common foramen for the orbitonasal vein and profundus nerve in *Egertonodus* could not be ruled out). According to Allis (1923), in *Chlamydoselachus* the profundus nerve emerges on the dorsal surface of the nasal capsule. The profundus nerve in *Tribodus* may have exited the orbit from a separate foramen dorsal to the orbitonasal



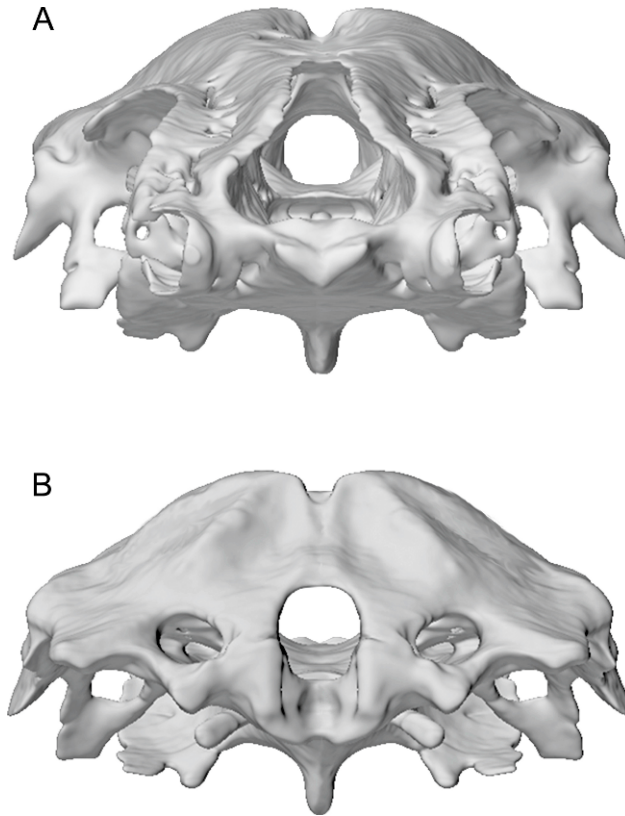


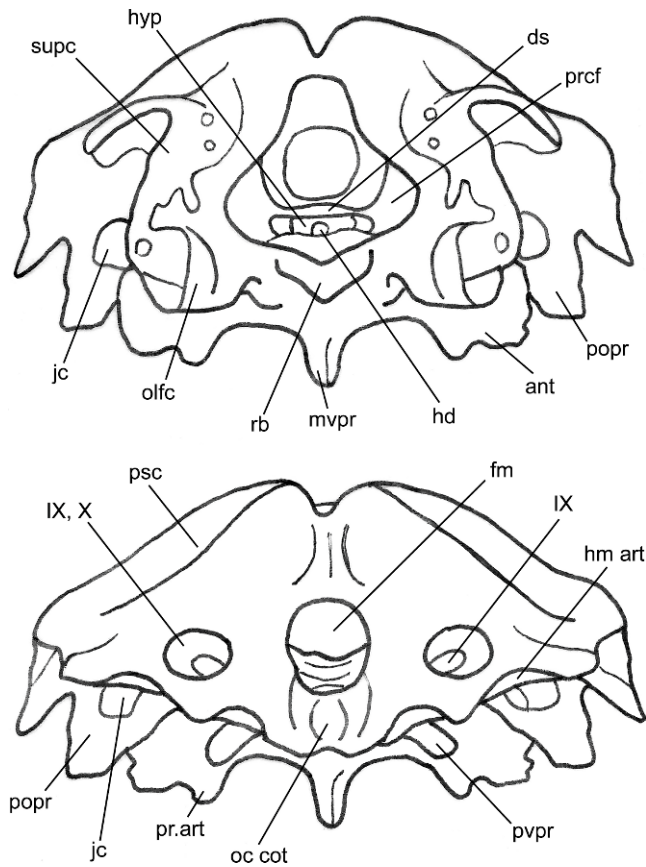
Fig. 12. Anterior (A) and posterior (B) views of the *Tribodus* braincase (surface renderings). No scale.

foramen, and emerged from a small opening visible on the dorsal surface of the nasal capsule in AMNH 13958. A large foramen located dorsal to the profundus foramen in the anterior part of the orbit of AMNH 13958 is here interpreted as the opening of the pre-orbital canal (figs. 10, 13: pre). Through this canal would have passed the orbital artery and vein and the superficial ophthalmic ramus of the anterodorsal lateral line nerve (originally referred to as the superficial or lateral ophthalmic ramus of the facial nerve; Jarvik, 1942: fig. 3: r.o.lat; Maisey, 1983: fig. 12: loph VII; Allis, 1923: 123: ramus ophthalmicus superficialis trigemini), as in *Egertonodus* and extant elasmobranchs (Maisey, 1983; Northcutt and Bemis, 1993).

As in *Egertonodus basanus* (Maisey, 1983) and *Tristychius arcuatus* (Dick, 1978), a basal communicating canal (rostral fenestra of Schaeffer, 1981) is absent in *Tribodus limae*. According to Maisey (1983), this opening is

found in squaloids, *Heptranchias*, and *Pristiophorus* (Holmgren, 1941), but not in other extant elasmobranchs, and it is also absent in *Xenacanthus*, *Tamiobatis*, “*Cladodus*” (Schaeffer, 1981; Maisey, 1983), and “*Cobelodus*” (Maisey, 1983). It has been proposed that a basal communicating canal may be a synapomorphy of some modern sharks (Maisey, 1980, 1983), and its absence in *Tribodus* and other hybodonts appears to be a conserved feature.

An epiphyseal foramen, if one had been present, is not preserved in AMNH 13958, as the dorsal midline of the braincase has been worn away from the posterior edge of the precerebral fontanelle to approximately the middle of the orbit. However, no evidence of an epiphyseal foramen was observed in any of the other specimens of *Tribodus* observed for the present paper, or in those described by Brito (1992). The epiphyseal foramen in *Egertonodus basanus* has been described as

Fig. 12. *Continued.*

located in the dorsal midline just posterior to the margin of the precerebral fontanelle (Maisey, 1983). In the absence of better specimens of *Tribodus*, it remains possible that an epiphyseal foramen may have been present and positioned similarly to that of *Egertonodus*. Alternatively, the epiphysis may have been located within the precerebral fontanelle, as in some extant elasmobranchs, in which case no foramen would be visible. According to Maisey (1983), a separate epiphyseal foramen is present in extant squaloids, hexanchoids, and scylliorhinids, while it is absent in *Heterodontus*, triakids, most carcharhinids, lamnoids, and orectoloboids. In these latter forms, the epiphysis is located near the posterior margin of the precerebral fontanelle. Maisey (1983) states that an epiphyseal foramen is also absent in *Cladodoides* (“*Cladodus*”), *Tamiobatis*, *Orthacanthus* (“*Xenacanthus*”), the

hybodontiform shark *Tristychius*, and “*Cobelodus*,” and he suggests that the epiphysis in these taxa was probably also located toward the back of the precerebral fontanelle. In the absence of any evidence of an epiphysis in *Tribodus*, even with well-preserved cranial material available, it seems very possible that the epiphysis in *Tribodus* did not have a separate foramen, and was located within the precerebral fontanelle as in the aforementioned taxa.

#### ORBITOTEMPORAL REGION

Unlike other hybodonts in which cranial material is known (e.g., *Hamiltonichthys mapeisi*, Maisey, 1989; *Egertonodus basanus*, Maisey, 1983, 1987; *Egertonodus fraasi*, Maisey, 1986, 1987; *Hybodus reticulatus*, Maisey, 1987), *Tribodus* (figs. 11, 13) lacks suborbital shelves.

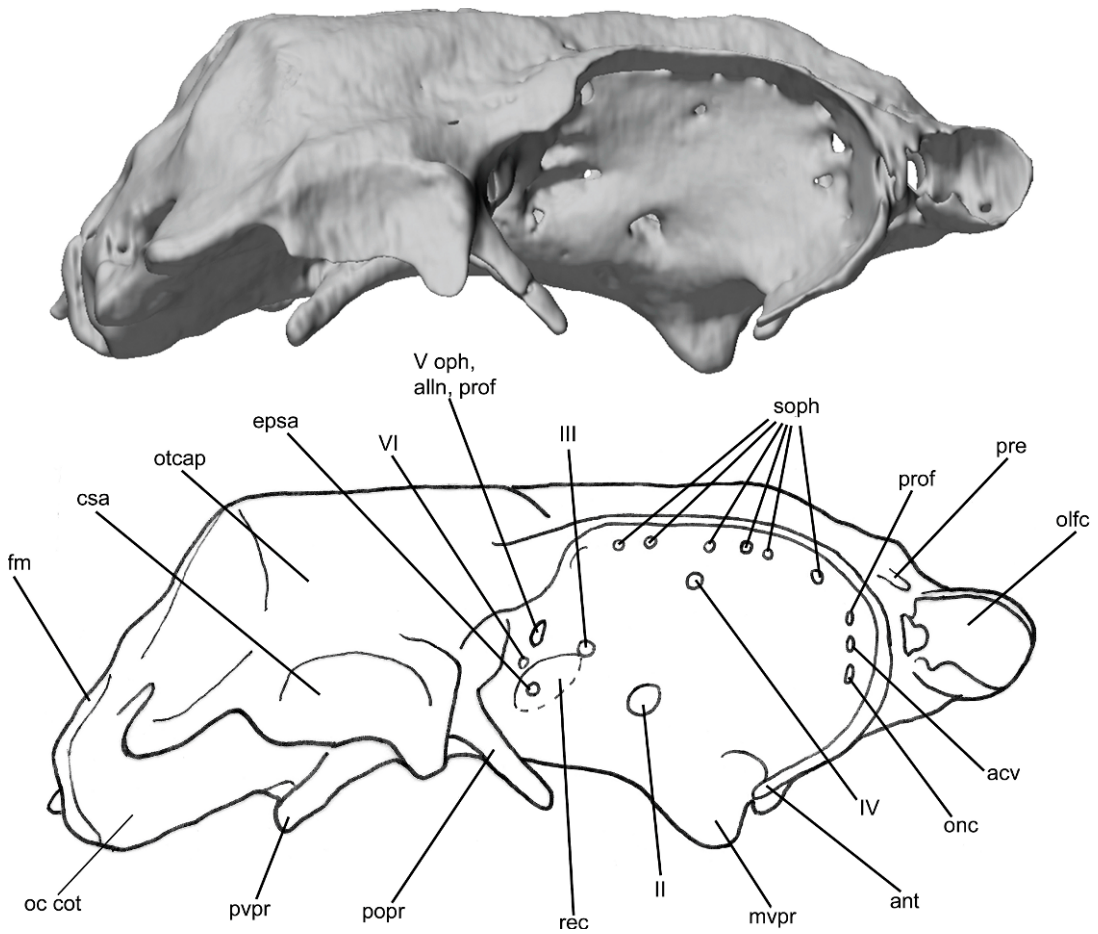


Fig. 13. Lateral view of the *Tribodus* braincase, anterior to the right (surface rendering). No scale.

Instead, the ventral part of the basicranium in the orbital region is smoothly rounded and convex, and narrower than the orbital walls farther dorsally, so that a transverse section through the braincase in this area resembles an inverted triangle with a rounded point (fig. 7B–H). Overall, the orbit in *Tribodus* is more completely enclosed by cartilage than in other known hyodonts, with large antorbital and postorbital processes (figs. 11, 13) that extend ventrally below the level of the interorbital wall, as noted by Maisey and Carvalho (1997).

**ROOF OF THE ORBITOTEMPORAL REGION:** The cranial roof in the orbitotemporal region (figs. 3B, 10, 12) is convexly domed dorsomedially, as in *Egertonodus* (Maisey, 1983). Lateral to this on either side of the cranial roof are pronounced supraorbital crests over-

hanging the orbits, which slope upward dorso-laterally in cross-sectional view (figs. 3B, 6C–H, 7A–H, 10: supc). Between the supraorbital crests and the dorsomedial dome of the braincase are narrow, anteroposteriorly elongated concave regions, which contain the foramina (figs. 3B, 7A, 10, 13: soph) for the branches of the superficial ophthalmic nerve complex (trigeminal and anterodorsal lateral line nerves) supplying the supraorbital sensory canals. These foramina form a single row extending anteroposteriorly, and this row forms a laterally concave curve, following the shape of the supraorbital crest. In most of the specimens examined the median dorsal roof of the braincase is not preserved anteriorly.

**OPTIC, TROCHLEAR, AND OCULOMOTOR NERVES:** The optic foramen is a large, round

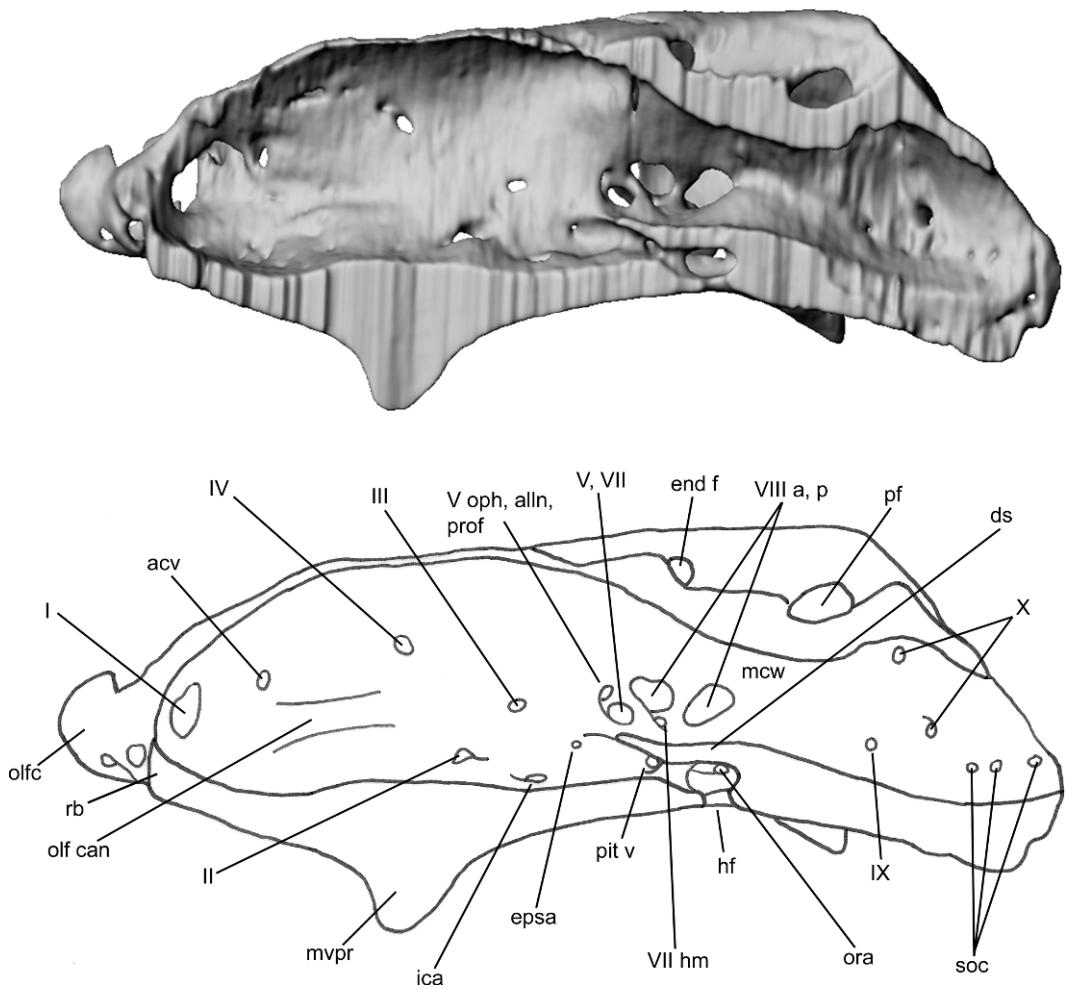


Fig. 14. Medial view of the *Tribodus* braincase sliced through the sagittal plane, anterior to the left (surface rendering). No scale.

opening ventral to the center of the orbit, and immediately posterior and dorsal to the median ventral basicranial process (figs. 3C, 7A, 11, 13, 14: II). The optic nerve and artery likely passed through this foramen together, as in many other elasmobranchs (e.g., *Chlamydoselachus*, Allis, 1923; *Cladodoides*, Maisey, 2005). The optic foramen marks the boundary between the embryonic orbital and trabecular cartilages in extant elasmobranchs (El-Toubi, 1949). The foramen for the trochlear nerve (IV), which innervates the dorsal oblique eye muscle in gnathostomes, is visible on the interorbital wall near the base of the supraorbital crest, dorsal and anterior to the optic

foramen (figs. 6H, 13, 14: IV). This position for the trochlear foramen (anterodorsal to the optic foramen) also occurs in *Egertonodus basanus* and other hybodonts, and may be of phylogenetic importance as a shared hybodont feature (Maisey, 2004a). Ontogenetically, the trochlear foramen forms within the embryonic orbital cartilage and is surrounded by it on all sides (El-Toubi, 1949).

Posterior and slightly dorsal to the optic nerve foramen is a much smaller foramen, here interpreted as housing the oculomotor (III) nerve (figs. 7B–C, 13, 14). This interpretation is further supported by CT scan images and digital reconstructions of the cranial

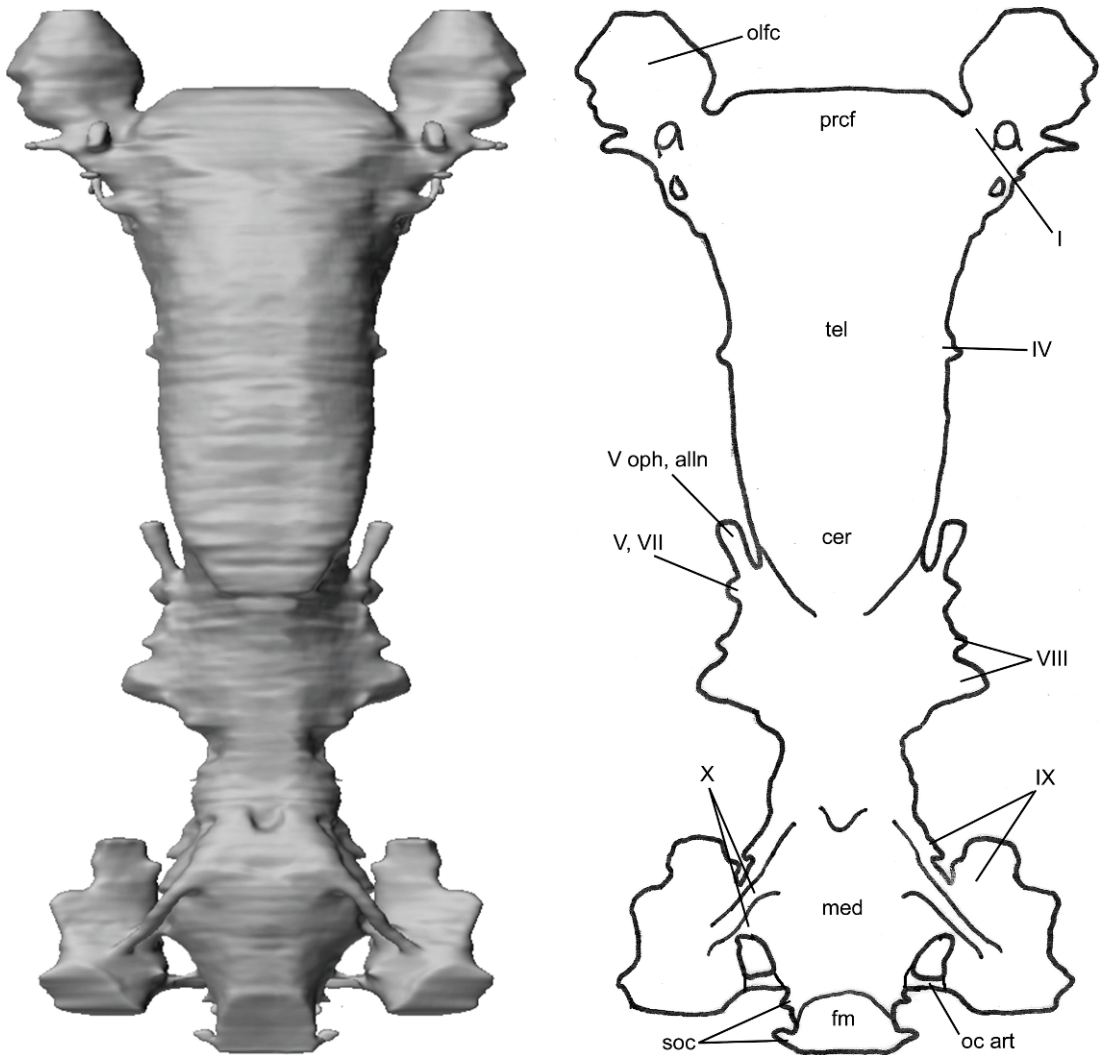


Fig. 15. Dorsal view of the *Tribodus limae* endocast with otic labyrinth removed, anterior at top (surface rendering). No scale.

endocast, which show a small outgrowth from the endocast at the approximate position of this foramen (figs. 16, 18), located behind the optic nerve and immediately dorsal to the anterior of the hypophyseal chamber (the location of the oculomotor nerve in *Notorynchus* and many other neoselachians; Maisey, 2004b). The oculomotor foramen is well preserved in UERJ-PMB-40, in which it is visible as a small foramen with an anteriorly directed opening, located posterodorsal to the optic foramen and immediately anteroventral to the

prootic foramen (see section on trigeminal and facial nerves, below). The oculomotor foramen in *Tribodus* is located slightly anterior to its inferred position in *Egertonodus basamus* (Maisey, 1983: fig. 14A), in which it is identified as dorsal and slightly posterior to the efferent pseudobranchial foramen (confirmed by CT scans of *Egertonodus*; see section on endocranial morphology of *Egertonodus basamus*, below).

There is no conclusive evidence of an optic pedicel (= eyestalk; optic stalk) in *Tribodus*,



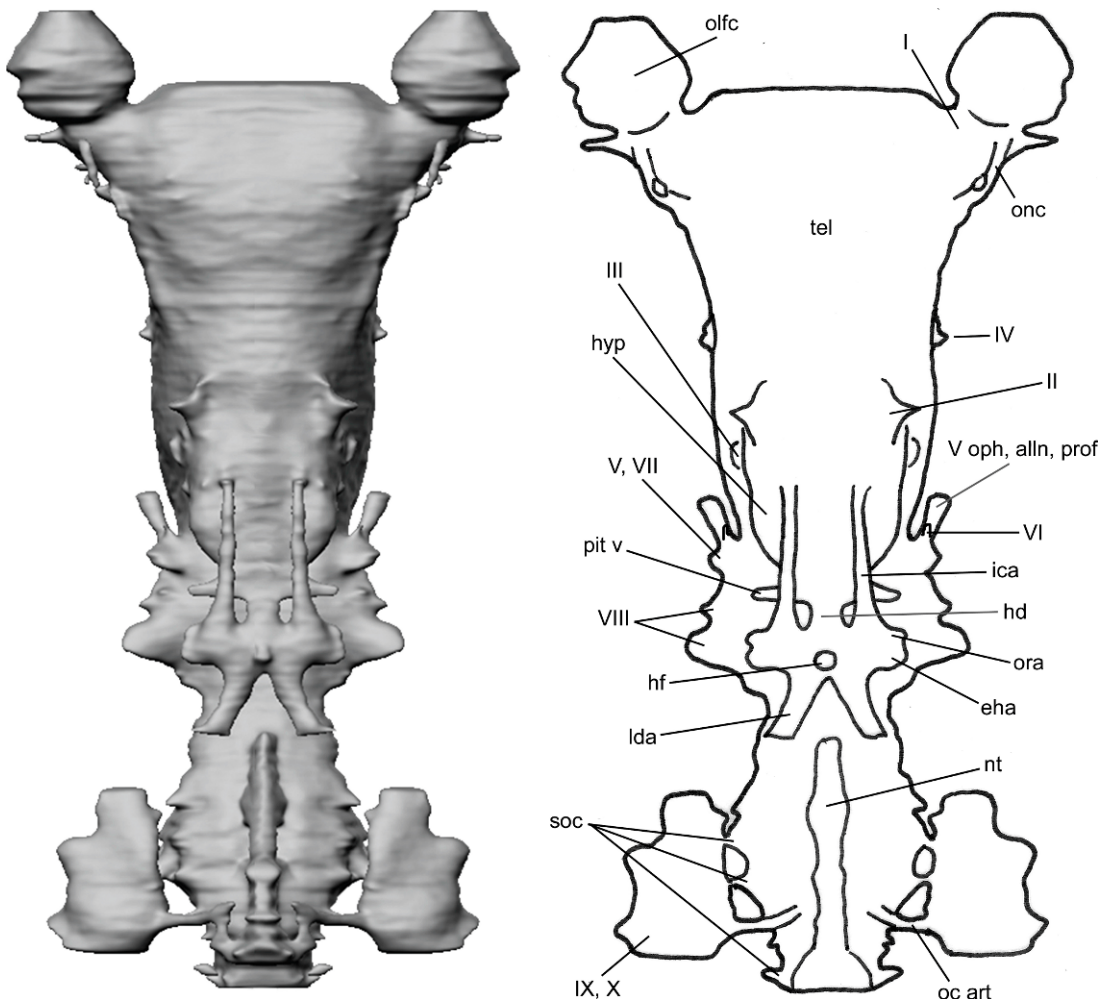


Fig. 16. Ventral view of the *Tribodus limae* endocast with otic labyrinth removed, anterior at top (surface rendering). No scale.

although it remains possible that one could have been present in the region of the oculomotor nerve, as in many other elasmobranchs. However, there is also no evidence of an optic pedicel in any other known hybodont. Optic pedicels are known in extant neoselachians (e.g., *Chlamydoselachus*, *Squalus*, Allis, 1923; Shirai, 1992; Maisey, 2007; batoids, many squaloids and galeomorphs, Shirai, 1992), as well as extinct chondrichthyans (e.g., “*Cobelodus*,” *Cladodoidea*, Maisey, 2005, 2007; *Tamiobatis*, Schaeffer, 1981; *Synechodus*, Maisey, 1985), extinct osteichthyans (e.g., *Ligulalepis*, *Psarolepis*, Basden et al., 2000; Zhu et al., 2001;

Maisey, 2007) and placoderms (Young, 1986). Presence of an optic stalk may be primitive for gnathostomes, although this feature is absent in extant osteichthyans and chimaeroids (Maisey, 2005) as well as in some extant neoselachians (e.g., many carcharhinoids and the squalan *Isistius*; Shirai, 1992). In elasmobranchs and placoderms, the optic pedicel is typically located posterior to the optic foramen and ventral to the oculomotor foramen (Maisey, 2005). Ontogenetic studies of extant elasmobranchs such as *Squalus acanthias* show that the optic pedicel forms as a separate cartilage independent of the developing braincase, with which it later joins

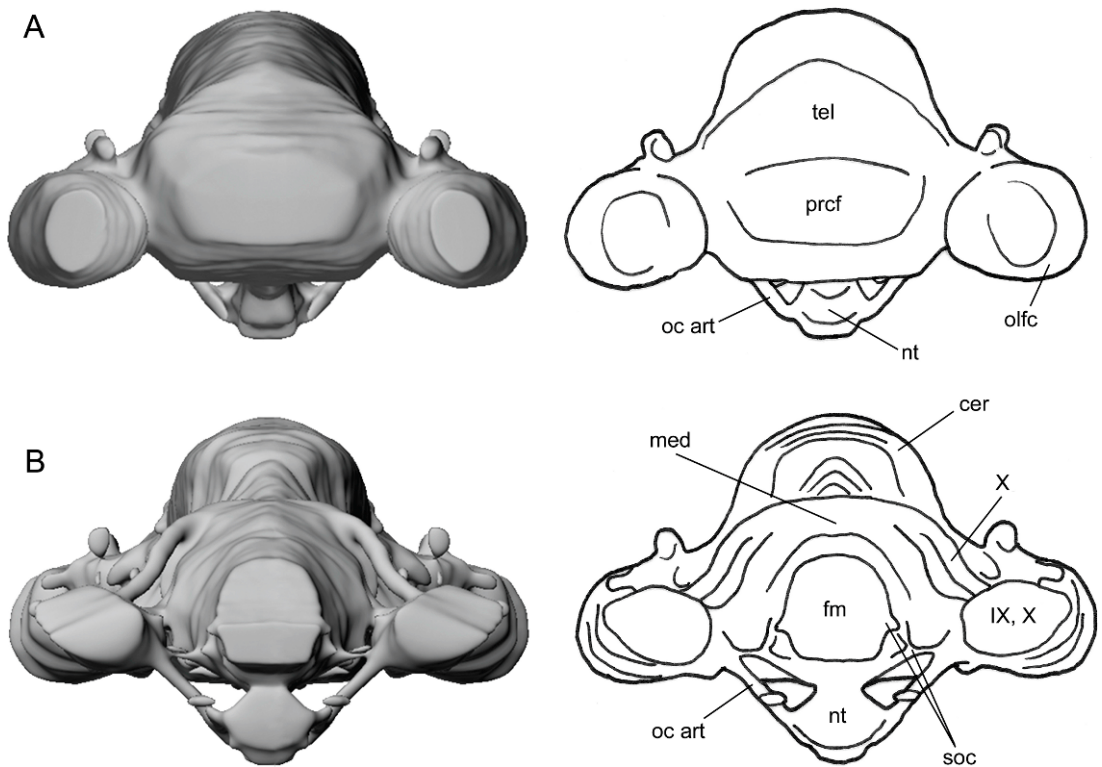


Fig. 17. Anterior (A) and posterior (B) views of the *Tribodus* endocast with otic labyrinth removed, (surface renderings). No scale.

(El-Toubi, 1949). In AMNH 13958, a laterally convex, uncalcified region is present posterior to the optic foramen and posteroventral to the oculomotor foramen on both sides of the braincase, and could possibly represent the attachment site for an optic pedicel. A similar raised, rounded, uncalcified area posteroventral to the oculomotor foramen and ventral to the foramen for the superficial ophthalmic complex is also present in UERJ-PMB-40. However, in *Egertonodus* no evidence of an eyestalk has been reported (Maisey, 1983, 1986, 1987), and in other hybodonts (e.g., *Hybodus reticulatus* and *Hamiltonichthys mapest*), as a result of poor preservation, not enough evidence exists to determine whether an optic pedicel was present.

**TRIGEMINAL, FACIAL, AND ANTERODORSAL LATERAL LINE NERVES:** According to Goodrich (1930), the foramen for the main branch of the facial nerve is closed off in adult gnathostomes by a prefacial commissure, a narrow strip of cartilage that extends from the

basal plate to the auditory capsule. This structure separates the foramina for nerves V and VII, creating an anterior (prootic) foramen and a posterior (facial) foramen. The prefacial commissure is absent in some extant chondrichthyans (Scylliodei and several others, Shirai, 1992), and also in some osteichthyans (Goodrich, 1930).

Developmentally, in extant elasmobranchs, the embryonic fenestra prootica (an opening between the orbital cartilage and otic capsules) contains the profundus, trigeminal, and abducens nerves, part of the facial nerve, and the anterior lateral line nerves (Goodrich, 1930; Holmgren, 1940; El-Toubi, 1949; Northcutt and Bemis, 1993). Generally, the prootic foramen in adult gnathostomes contains the ophthalmic rami of the trigeminal and anterodorsal lateral line nerves, the entry of the profundus nerve into the orbit, the buccal ramus of the anterodorsal lateral line nerve, and the maxillary and mandibular branches of

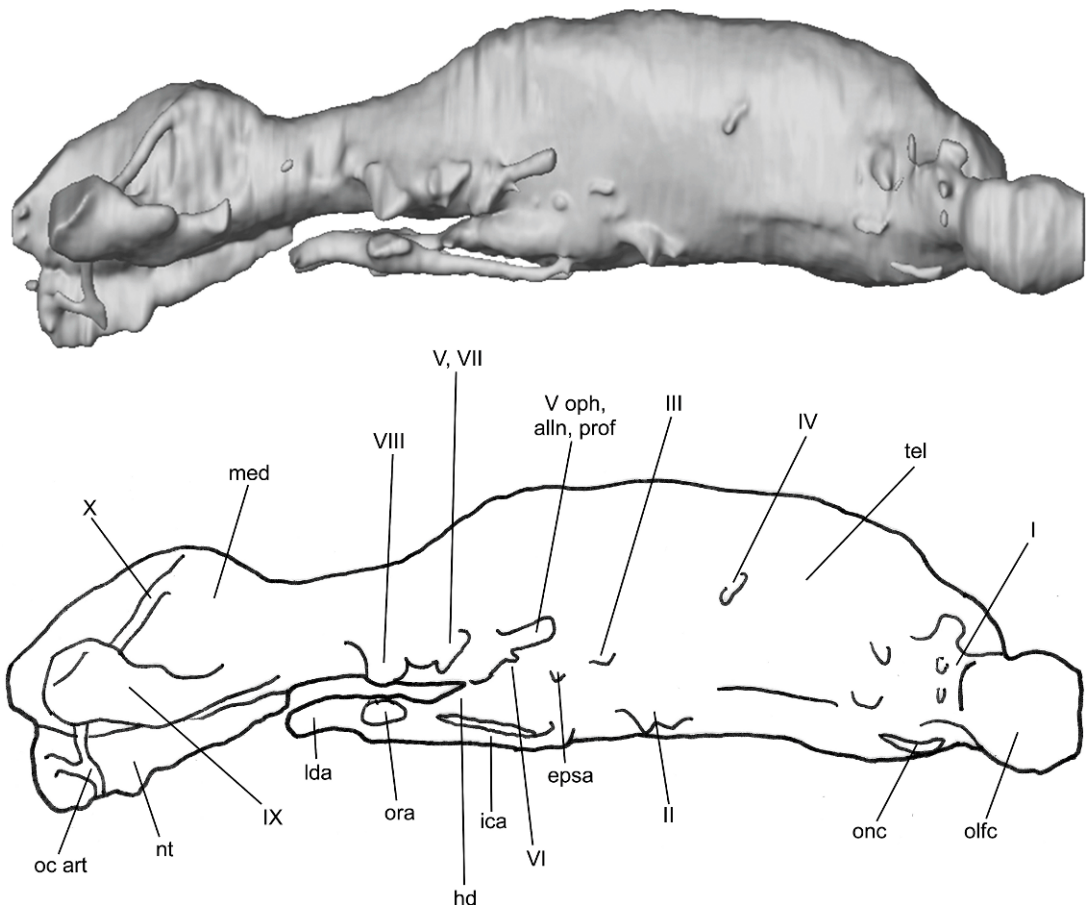


Fig. 18. Lateral view of the *Tribodus limae* endocast with otic labyrinth removed, anterior to the right (surface rendering). No scale.

the trigeminal nerve (V), whereas the palatine and hyomandibular branches of the facial nerve (VII) and the anteroventral lateral line nerve emerge from the facial foramen (Goodrich, 1930; Northcutt and Bemis, 1993). This arrangement, with two foramina for the above-mentioned nerves, occurs in squalians, *Heterodontus*, and some fossil outgroups (Shirai, 1992). However, according to Shirai (1992) at least three other patterns are observed in extant neoselachians. Among squalians, a single trigeminofacial foramen is found in *Echinorhinus*, whereas *Zameus* has three separate foramina: an anterior, containing the profundus nerve and the maxillary and mandibular rami of the trigeminal nerve; a central, containing the superficial ophthalmic complex and the buccal ramus of the ante-

rodorsal lateral line nerve; and a posterior foramen, containing the hyomandibular ramus of the facial nerve. In many galeomorphs, two foramina are present, but the more dorsal foramen contains only the superficial ophthalmic complex (Shirai, 1992).

In *Tribodus limae*, three foramina for the trigeminal, facial, profundus and anterior lateral line nerves appear to have been present: a moderately sized anterodorsal foramen (figs. 3C, 7 D–H, 13, 14: V oph, alln, prof), a larger foramen ventrolaterally (figs. 3A, 8A, 11, 14: V, VII), and a small foramen immediately posterior to the large foramen (figs. 11, 14: VII hm). The anteriorly directed foramen posterior and dorsal to the oculomotor foramen is here interpreted as having probably contained the superficial ophthalmic complex

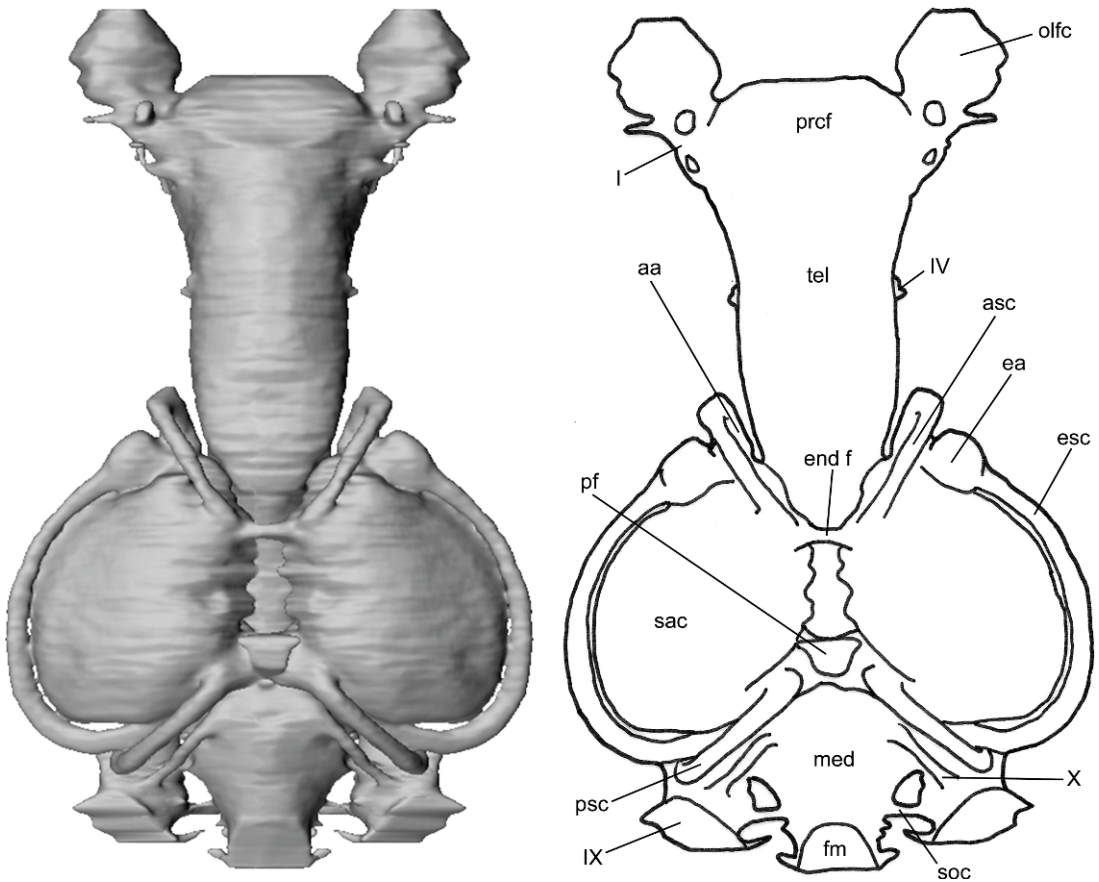


Fig. 19. Dorsal view of the *Tribodus* endocast and skeletal labyrinth, anterior at top (surface rendering). No scale.

and profundus nerve. The larger foramen immediately posteroventral to this corresponds to the “trigemino-facial” (V–VII) foramen of previous authors (e.g., Maisey, 1983; Brito, 1992), and likely contained the main trigeminal-anterodorsal lateral line complex (formerly considered the trigeminofacial complex; revised by Northcutt and Bemis, 1993), including the maxillary and mandibular rami of nerve V, and the buccal ramus of the anterodorsal lateral line nerve. In the present paper the abbreviation “V, VII” is retained for this foramen in the figures for clearer comparison with previous works. Finally, the small posteriormost foramen likely contained the main trunk of the anteroventral lateral line and facial nerves, including the hyomandibular ramus of the facial nerve (and possibly also its palatine ramus, as in *Heterodontus*;

Goodrich, 1930: fig. 284), and the mandibular ramus of the anteroventral lateral line nerve. This interpretation of the trigeminofacial foramina in *Tribodus*, if correct, indicates a noticeably different pattern from that previously described in other fossil elasmobranchs, including previous descriptions of *Tribodus* (e.g., Brito, 1992), and may indicate a shared feature of hybodonts. Comparison with *Egertonodus* (see section on endocranial morphology of *Egertonodus basanus*, below) lends some support to this hypothesis. The presence of a separate superficial ophthalmic foramen in hybodonts is at least superficially similar to the condition in some galeomorphs, although these forms lack an additional foramen for the hyomandibular ramus. However, variations in closure of the embryonic incisura prootica can produce at least four separate patterns of



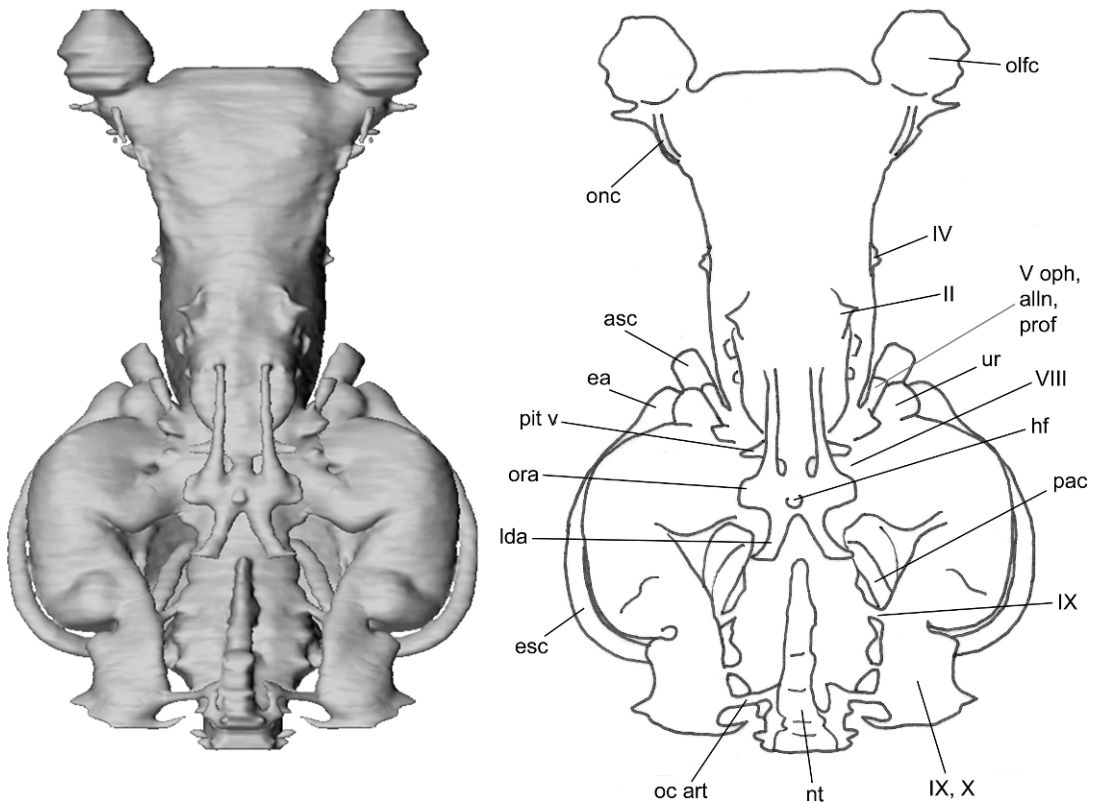


Fig. 20. Ventral view of the *Tribodus* endocast and skeletal labyrinth, anterior at top (surface rendering). No scale.

foramina in modern elasmobranchs, differing even among closely related taxa (e.g., *Zameus*, *Echinorhinus*; Shirai, 1992). Therefore, an additional pattern such as that found in *Tribodus* could probably be arrived at fairly easily, at least from an embryological perspective.

This interpretation of the foramina for the trigeminal, facial, profundus, and anterior lateral line nerves in *Tribodus* differs from that of Brito (1992), who identified the more anterodorsal foramen as the prootic foramen, as did Maisey in his description of *Eger-tonodus* (Maisey, 1983). In *Tribodus*, the prootic foramen (if one can be identified) would more properly be the largest of the three foramina, containing the main trigeminal-anterdorsal lateral line complex, identified as the hyomandibular foramen by Brito (1992). The prefacial commissure would then be the narrow strip of cartilage separating it

from the smaller hyomandibular (facial) foramen immediately posterior to it.

However, the position of the prootic foramen in *Tribodus* and *Eger-tonodus* differs from that of *Cladodoides* (Maisey, 2005) in being located anteromedial, rather than posteromedial, to the postorbital process. Directly posterior to the dorsal edge of the superficial ophthalmic foramen in UERJ-PMB-40 is a tiny foramen whose opening is directed posterodorsally. From its opening, a narrow indented furrow is distinctly visible extending dorsally, terminating just anteroventral to one of the superficial ophthalmic foramina on the ventral side of the supraorbital crest. A similar narrow furrow is visible extending dorsally from the middle of the dorsal surface of the main prootic foramen. These furrows probably represent the paths of individual rami of the superficial ophthalmic complex.

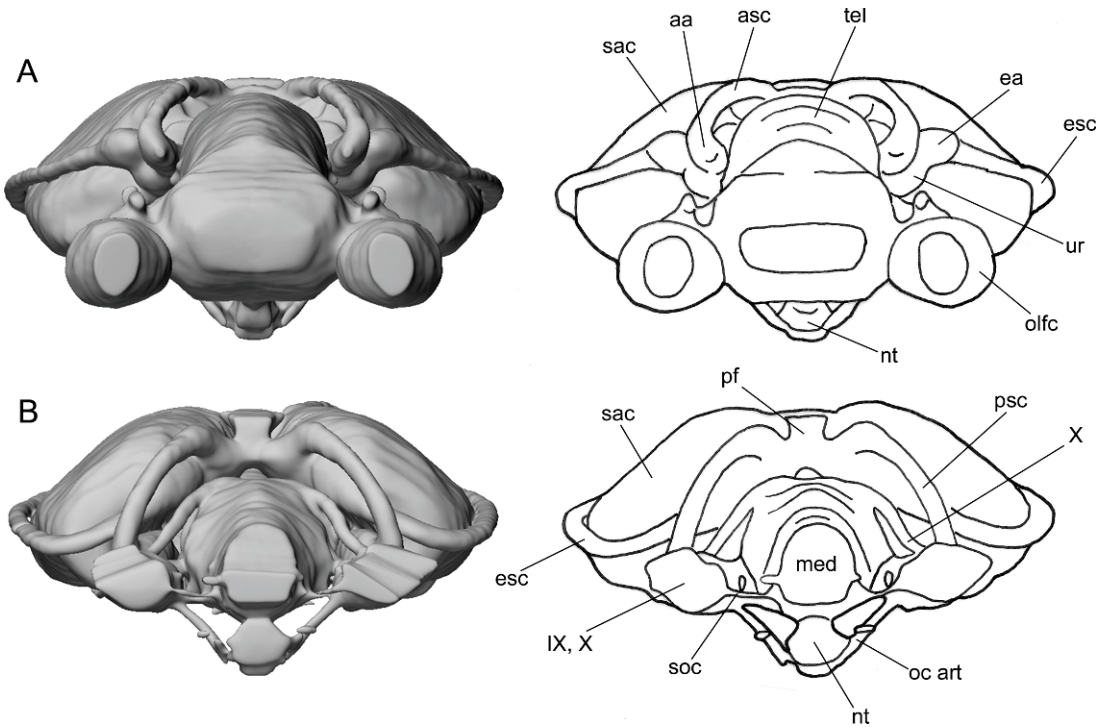


Fig. 21. Anterior (A) and posterior (B) views of the *Tribodus* endocast and skeletal labyrinth (surface renderings). No scale.

#### TRIGEMINOFACIALIS RECESS

A large recess is present on the external posterolateral surface of the orbit in *Tribodus limae* (AMNH 13958 and UERJ-PMB-40: figs. 3C, 7E, 13: rec). As in *Egertonodus* (Maisey, 1983), this recess is considered here to be homologous to the trigeminofacialis recess of Allis (1923), although (also as in *Egertonodus*, as well as *Cladodooides* and “*Cobelodus*,” Maisey, 2007) it does not contain foramina for the trigeminal or facial nerves. CT scans show that it also did not contain the pituitary vein in *Tribodus*. This recess is located posterior to the oculomotor foramen, ventral to the superficial ophthalmic foramen, and anterior to the prootic foramen. A clearly defined opening at the anterodorsal end of the trigeminofacialis recess is interpreted as the oculomotor (III) foramen, as described above. Within the recess are two additional foramina, probably for the abducens nerve and efferent pseudobranchial artery (supported by CT scan data), and a small

posterior depression that may have contained the origin of the external (= lateral or posterior) rectus eye muscle, which was innervated by the abducens nerve.

**ABDUCENS NERVE:** A small opening at the posterodorsal end of the trigeminofacialis recess is here interpreted as having contained the abducens (VI) nerve (figs. 7F–H, 13: VI). This position for the abducens foramen in *Tribodus limae* is supported by evidence from extant elasmobranchs, in which it is usually located in the vicinity of the prootic foramen (in the latter, the nerve typically exits either through the foramen (e.g., *Heterodontus*) or anterior to it (e.g., *Squalus*) (Goodrich, 1930: fig. 284). This interpretation is also supported by CT scan evidence, which shows that this foramen leads internally to a small canal that joins posteriorly with the larger canal leading to the superficial ophthalmic foramen. This canal originates at the base of the trigeminofacialis-anterodorsal lateral line nerve trunk farther posteriorly, a location consistent with the abducens nerve leaving the cranial cavity.

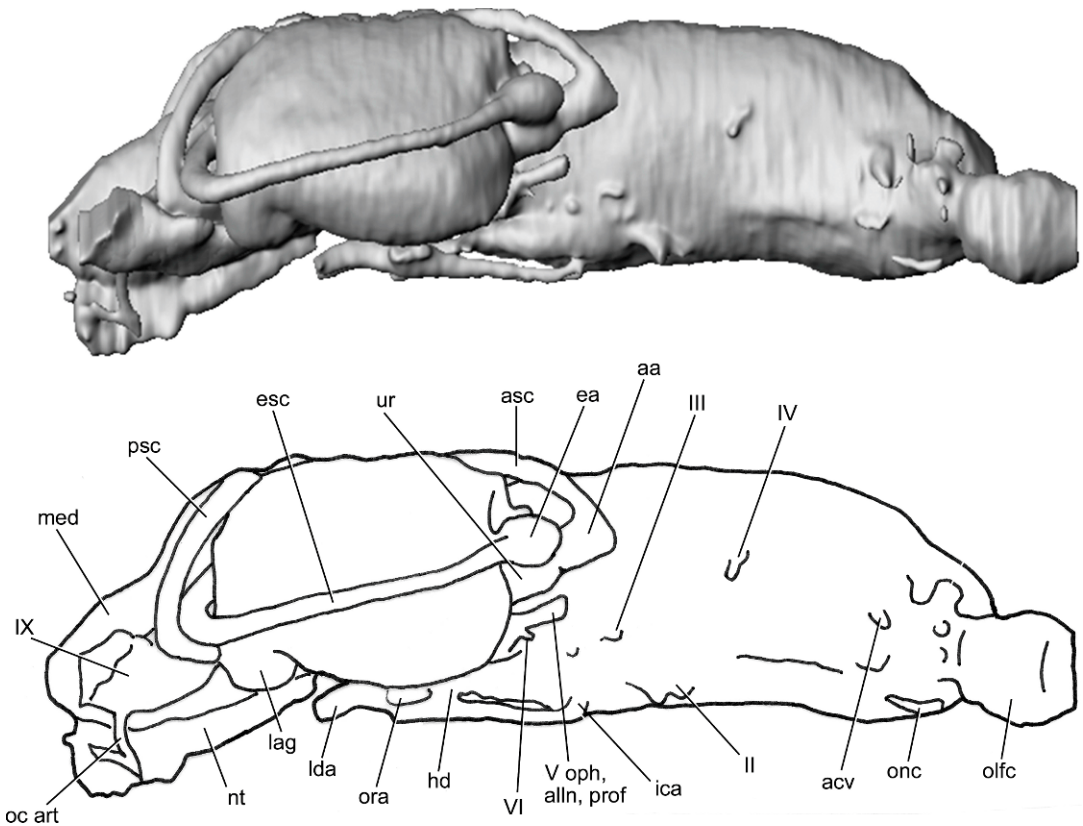


Fig. 22. Lateral view of the *Tribodus* endocast and skeletal labyrinth, anterior to the right (surface rendering). No scale.

The abducens nerve typically originates on the ventral side of the brain slightly mesial to the octaval and hyomandibular trunks, and then proceeds anterolaterally, following the pathway of the superficial ophthalmic complex and nerves V and VII (which typically exit through the prootic foramen) (Wischnitzer, 1993: fig. 8-2). Additional evidence in support of this conclusion is the position of this foramen just below the level of the oculomotor foramen, on a level with the presumed location where the optic pedicel would be if one were present. This position is consistent with the location of the abducens foramen in neoselachians and *Cladodoidea* (Maisey, 2005). It is also within the trigeminofacialis recess, close to the presumed origin of the external rectus eye muscle, which it innervated. However, although the abducens foramen was identified in a similar location (anterior to the facial foramen, in the posterodorsal rim of the

trigeminofacialis recess) in *Egertonodus* (Maisey, 1983), CT scans indicate that this foramen in *Egertonodus* probably housed the pituitary vein instead. It is possible that the abducens nerve in *Egertonodus* was contained within the prootic foramen, as in extant *Heterodontus*.

Alternatively, the fact that the above-mentioned foramen is internally connected with the superficial ophthalmic foramen could suggest a different interpretation in which this foramen is a branch of nerves V, VII, or the anterodorsal lateral line nerve (such as the mandibular ramus of nerve V), or perhaps a separate exit for the profundus nerve. An interpretation of this foramen as the profundus foramen may be supported by CT scan images, which could instead show the ophthalmic rami of the trigeminal and anterodorsal lateral line nerves diverging into two separate canals as they leave the cranial cavity

(as in extant neoselachians such as *Squalus*, Wischnitzer, 1993: fig. 8-2) and exiting separately from the braincase. The larger canal (interpreted as housing the superficial ophthalmic complex and its associated nerves) exits through the dorsal foramen, and the smaller canal (possibly the profundus nerve) exits through the more posteroventral foramen, located in the rear of the trigeminofacialis recess. This alternative interpretation is further supported by the fact that the nerve trunk that diverges into these two canals is positioned anteriorly on the cranial endocast with respect to the large trigeminofacial-anterodorsal lateral line nerve trunk that branches from the endocast laterally, and appears to correspond to the location of the superficial ophthalmic, infraorbital, mandibular, and profundus nerves in extant neoselachians such as *Squalus* (Wischnitzer, 1993: fig. 8-2). A separate profundus foramen is also present in *Cladodoides*, located anteroventral to the prootic foramen (Maisey, 2005), and one may also have existed in *Orthacanthus* (Schaeffer, 1981). This arrangement also occurs in chimaeroids (e.g., *Callorhynchus*: De Beer, 1937: pl. 22). However, a separate profundus foramen was not reported in *Egertonodus* (Maisey, 1983), and is absent in most neoselachians (Maisey, 2005). Also, this foramen in *Tribodus* is located posteroventral to the prootic foramen, rather than anteroventral to it as in *Cladodoides* (see Maisey, 2005).

The latter interpretation would also necessitate a different location for the abducens foramen. One alternative is that the abducens nerve exited the braincase through the prootic foramen as in *Heterodontus* (and possibly *Egertonodus*). It is additionally possible that a small foramen located directly posterior and ventral to the prootic foramen (discussed above, and identified as the hyomandibular foramen) is instead the abducens foramen. CT scans of the interior of the braincase show that this foramen originates on its ventrolateral wall (dorsal to the dorsum sellae and about halfway along its length), and is located between and ventral to two larger foramina, here interpreted as the anterior and posterior rami of the octaval (VIII) nerve (see section on octaval, glossopharyngeal, vagus, and spino-

occipital nerves, below). This interpretation would be supported by the fact that the abducens nerve exits the braincase in this position in *Cladodoides* (Maisey, 2005: figs. 7, 17). Also, according to Maisey (2005), having the abducens foramen located below and behind the dorsum sellae may be a primitive gnathostome feature. This feature is also found in chimaeroids and some neoselachians, and may be primitive for chondrichthyans (Maisey, 2005). However, in *Cladodoides* this foramen is level with the eyestalk (as is the abducens nerve in neoselachians), whereas in *Tribodus* this more ventral foramen is not on a level with the region where an eyestalk typically would be found. Also, in *Cladodoides* this position is within the orbit, ventral to the prootic foramen and anterior to the hyomandibular foramen, whereas in *Tribodus* the aforementioned foramen is posterior to the presumed hyomandibular foramen and far posterior to the "prootic" foramen (interpreted here as the superficial ophthalmic foramen, as discussed above). Because the abducens nerve in gnathostomes innervates the external rectus eye muscle, it seems unlikely that it would emerge this far back from the trigeminofacialis recess, where that muscle would have originated. The foramen in the posterodorsal rim of the trigeminofacialis recess is thus here considered more likely to be the abducens foramen, and the more posterior foramen is interpreted as the hyomandibular (facial) foramen.

**EFFERENT PSEUDOBRANCHIAL ARTERY:** A foramen located centrally within the trigeminofacialis recess in *Tribodus* and near its ventral margin is interpreted here as the foramen for the efferent pseudobranchial artery (figs. 7D, 13, 14, 24: epsa). Maisey (1983) identified the efferent pseudobranchial artery as occupying a similar location in *Egertonodus basanus*, also in the midventral part of the trigeminofacialis recess. However, CT scans show that the efferent pseudobranchial foramen in *Egertonodus* was located somewhat farther anteriorly (see section on *Egertonodus* endocranial morphology, below). As in *Tribodus*, smaller foramina occur anterodorsally and posterodorsally within this recess in *Egertonodus*. The more anterior of these foramina in *Egertonodus* has been



interpreted as the oculomotor foramen, as in *Tribodus* (Maisey, 1983). The more posterior foramen in *Egertonodus* was interpreted by Maisey (1983) as the abducens foramen. It is here interpreted that the efferent pseudobranchial and ophthalmic arteries in *Tribodus* diverged external to the braincase, after exiting together through a common foramen (as in many extant neoselachians).

This location for the efferent pseudobranchial foramen is supported by several factors. First, because the efferent pseudobranchial foramen marks the anterolateral margin of the embryonic polar cartilage in elasmobranchs, whereas the pituitary vein foramen marks its posterolateral end, it is generally considered that the efferent pseudobranchial artery must be located anterior to the pituitary vein (although during a brief developmental stage in embryonic *Torpedo*, the two vessels share a common foramen; Holmgren, 1940). This is certainly the case in *Tribodus*, in which the efferent pseudobranchial artery is located well in front of the dorsum sellae and pituitary vein. Second, CT scan images reveal paired foramina (fig. 14: ica) in the floor of the cranial cavity, several millimeters anterior to the anterior tip of the dorsum sellae and slightly anterior to the foramen just described. CT scans indicate that the internal carotid arteries entered the cranial cavity through these foramina, after entering the braincase farther posteriorly and tunneling through the basicranial cartilage (see section on lateral dorsal aortae, internal carotid arteries, hypophyseal foramen, and pituitary vein, below).

**FACIAL NERVE AND ACOUSTICO-TRIGEMINOFACIALIS RECESS:** Brito (1992) identified a large foramen posteroventral to his “prootic” foramen on the exterior of the braincase as representing the foramen for the hyomandibular ramus of the facial nerve (fig. 2C: VII hym). Brito’s “prootic” foramen is here interpreted as housing the superficial ophthalmic complex, and the larger, more posterior foramen is interpreted as the main trigeminofacial (V, VII) foramen (which probably contained the maxillary and mandibular rami of the trigeminal nerve, and the buccal ramus of the anterodorsal lateral line nerve, in *Tribodus*, following cranial nerve terminology of Northcutt and Bemis, 1993). Additional

support for this hypothesis is provided by CT scans and digital images of the interior of the braincase. These scans show that this foramen (fig. 14: V, VII) opens internally in the anterior part of a large recess (interpreted as the acoustico-trigeminofacialis recess), immediately posteroventral to another foramen that leads anteriorly to the superficial ophthalmic foramen (fig. 14: V oph, alln, prof) and anterior to a larger foramen interpreted as the anterior ramus of the octaval nerve (fig. 14: VIIIa). This position is consistent with the location of the trigeminofacial foramen in many neoselachians. In addition to the superficial ophthalmic and trigeminofacial foramina, the acoustico-trigeminofacialis recess contains two additional large foramina posteriorly, both of which exit the cranial cavity and enter the otic capsule. These foramina likely contained the anterior and posterior branches of the octaval (VIII) nerve (see section on endocranial space, cranial endocast, and skeletal labyrinth of *Tribodus*, below).

An additional, smaller foramen in the region of the acoustico-trigeminofacialis recess, located between and immediately ventral to the trigeminofacial-anterodorsal lateral line and octaval foramina, is here interpreted as the hyomandibular (facial) foramen (fig. 14: VII hm). However, it is alternatively possible that this foramen housed the abducens nerve, as discussed above, or perhaps the palatine ramus of the facial nerve (unlikely, because this is usually directed anteriorly, not posteriorly, and generally diverges from the hyomandibular ramus external to the cranial cavity). The foramen arises in the correct location on the floor of the cerebellar region to be consistent with the abducens nerve (above and behind the anterior of the dorsum sellae; slightly medial to the acoustico-trigeminofacialis recess). The abducens foramen is located at this position in *Squalus* (Marinelli and Strenger, 1959), *Cladodoides* (Maisey, 2005), and “*Cobelodus*” (Maisey, 2007). However, the abducens nerve usually exits the braincase farther anteriorly, in the region of the external rectus eye muscle, which it innervates (Shirai, 1992).

In *Cladodoides*, the palatine ramus of the facial nerve diverges to form separate anterior and posterior ramuli, which exit through the

floor of the braincase immediately below the base of the postorbital processes (Maisey, 2005). Although in *Cladodoides* the rami of the facial nerve diverge after exiting the braincase, it is possible that during ontogeny in *Tribodus* they could have been individually enclosed in cartilage to form separate foramina. In *Squalus*, there are separate foramina for the palatine and hyoid rami of nerve VII in the wall of the braincase (Goodrich, 1930: fig. 284). In any case, due to its position and relationship to the intracranial space (opening into the acoustico-trigemino-facialis recess), it seems fairly certain that this foramen was for a nerve ramus (probably of nerves V, VII, or the anterior lateral line nerves), rather than for an artery or vein.

#### BASICRANIUM

The basicranium in the ethmoid region, including the internasal lamina and median ventral process, were discussed in a previous section. The basicranium in the suborbital and otico-occipital regions of *Tribodus limae* is not uniformly level as in *Egertonodus basanus* (Maisey, 1983), but instead shows a concave curve ventrally, extending posteriorly from the ventral basicranial process to the occiput (figs. 3C, 13). A curved basicranium has not been described in any other hybodont, although in the fossil neoselachian *Synechodus dubrisiensis* (Maisey, 1985: figs. 2, 4E) and some batoids (e.g., *Rhinobatis*: Daniel, 1934: fig. 68) the neurocranium shows a similar ventral arch between the occiput and the anterior of the orbit. Unlike *Synechodus*, however, the neurocranium of *Tribodus* is not arched dorsally, and does not show the pronounced downward curvature of the ethmoid region seen in *Synechodus* as well as in extant *Heterodontus*, galeomorphs, and batoids (Maisey, 1985). As discussed previously, no suborbital shelves are present in *Tribodus* (unlike other previously described hybodonts, such as *Egertonodus*, Maisey, 1983), and the suborbital region of the basicranium is convexly rounded ventrally and continuous with the orbits, as in some extant squalians (Shirai, 1992). Other elasmobranchs lacking suborbital shelves include *Synechodus*, extant carcharhinid galeomorphs, *Chlamydoselachus*, hexan-

choids, squaloids, and batoids (Maisey, 1985; Shirai, 1992).

In *Tribodus limae*, there is a large median opening located directly posterior to the bases of the postorbital processes (best seen in AMNH 13958 and UERJ-PMB-40) (figs. 3A, 4B, 11, 23, 24: hf). This could either be an internal carotid foramen or a hypophyseal foramen (see Discussion). Although in AMNH 13958 it appears to be flanked by two shallow grooves in the cartilage (superficially resembling pathways for the internal carotid arteries seen in *Egertonodus* and other elasmobranchs), closer inspection and comparison with additional specimens reveal that these grooves are more likely small scratches in the surface of the fossil.

Several millimeters posterior to this median foramen and lateral to it are paired ventral processes, whose distal ends point posterolaterally (figs. 3A, C, 4B, 9B, 11–13, 23, 24: pvpr). Although only the left process is preserved in AMNH 13958; both processes are well preserved in UERJ-PMB-40 (figs. 4B, 23, 24). These structures are located directly posterior to a notch in the ventrolateral surface of the basicranium that originates immediately below the postorbital process, and when the palatoquadrates are placed against the neurocranium they appear to fit loosely into the anterior part of this notch between the ventral process and postorbital process. This indicates that these paired ventral processes may have helped to align the upper jaw where it contacted the neurocranium.

LATERAL DORSAL AORTAE, INTERNAL CAROTID ARTERIES, HYPOPHYSEAL FORAMEN, AND PITUITARY VEIN: In *Tribodus limae* (UERJ-PMB-40 and AMNH 13961), paired foramina are visible immediately dorsal to the paired ventral processes in posterior view (located on the ventromedial side of the base of each process, figs. 11, 23: lda). They are especially well preserved in UERJ-PMB-40 (fig. 23). These probably represent the points of entry of the lateral dorsal aortae into the braincase.

If the lateral dorsal aortae entered the braincase here and continued anteromedially within the basicranial cartilage, then the median basicranial foramen is not an entry point for the internal carotids, and requires

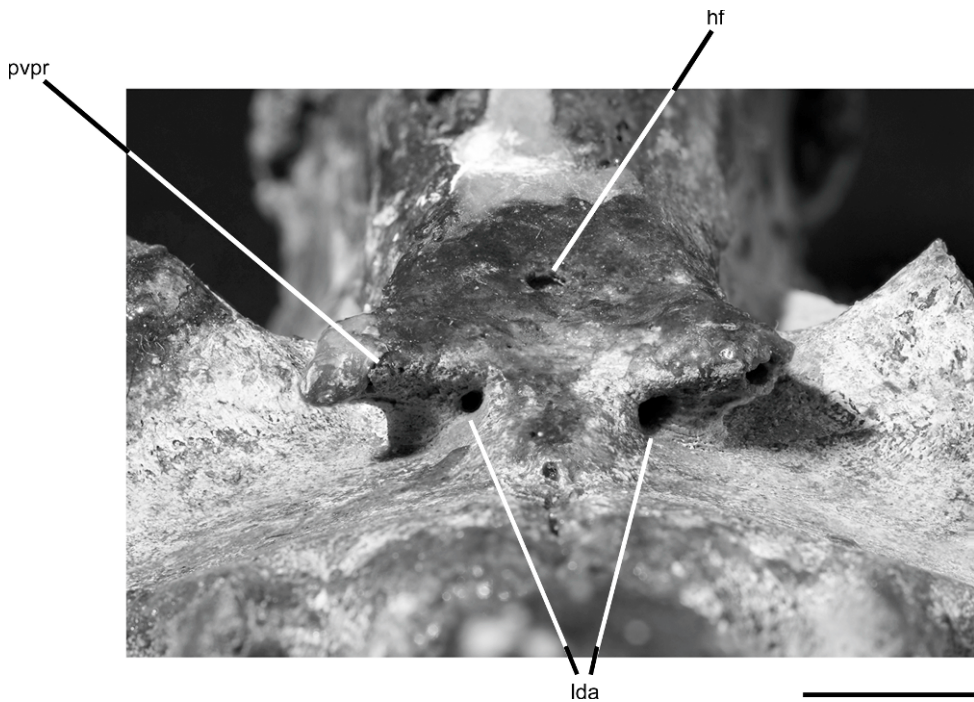


Fig. 23. Close-up of posterior basicranial foramina in *Tribodus limae* (UERJ-PMB-40). Scale bar is 1 cm.

further explanation. The most obvious explanation is that this latter opening is a hypophyseal foramen. This explanation is supported by CT scans and digital reconstructions of the braincase, which show that this foramen opens internally into a large cavity posterioventral to the main endocranial space (in the rear of the hypophyseal chamber) (figs. 8E, F, 14). This cavity is connected anteriorly with the endocranial space by a narrow medial canal (figs. 8C, 12, 16, 18: hd), indicating that it may represent the posterior lobe of a bipartite hypophysis as in some extant elasmobranchs (Daniel, 1934: 233). According to Maisey (1983), an open hypophyseal duct occurs in *Egertonodus basamus*, and also in *Xenacanthus*, *Tamiobatis*, “*Cladodus*,” and *Cladoselache*, but is lacking in adult neoselachians.

A small foramen located beneath the anterior part of the dorsum sellae and visible in digitally reconstructed sagittal sections of the braincase likely represents the interorbital canal, through which the pituitary vein passed to exit the braincase laterally through a small

foramen ventromedial and posterior to the opening for the facial and anteroventral lateral line nerves (figs. 8B, 14, 16, 24: pit v). This location for the pituitary vein is in keeping with the typical elasmobranch arrangement, in which the pituitary vein foramen is located posterior to the efferent pseudobranchial foramen and marks the boundary between the embryonic polar cartilage and the parachordal cartilage posteriorly.

**EFFERENT HYOIDIAN AND ORBITAL ARTERIES:** In *Tribodus limae*, anterior to the paired ventral processes and posterolateral to the hypophyseal foramen are two additional, larger pairs of foramina, best preserved in UERJ-PMB-40 (fig. 24). The more posterior pair of foramina exit the floor of the braincase posterolateral to the hypophyseal foramen, and open into the anterior part of an elongated, posterolaterally extending groove (fig. 24: eha). These foramina are here interpreted as housing the efferent hyoidian arteries, which passed posterolaterally from the lateral dorsal aortae to supply the hyoid arch. The more anterior pair of foramina is






Fig. 24. Close-up of lateral basicranial foramina in *Tribodus limae* (UERJ-PMB-40). Scale bar is 1 cm.

directed anterolaterally, and CT scan images of AMNH 13958 show that both these and the aforementioned pair of foramina is connected internally to the posterior foramina dorsal to the paired ventral processes. Based on these considerations, the anterolateral pair of foramina are here interpreted as representing the exits of the orbital (= stapedia) arteries from the braincase (fig. 24: ora). Narrow grooves in the cartilage extending anteriorly from these foramina toward the orbit further support the interpretation that the passage for the orbital arteries was located here. However, this interpretation is unusual in comparison with the typical pattern of cranial circulation in other elasmobranchs, and requires further explanation (see Discussion). It is unlikely that these foramina contained any cranial nerve rami, because CT scans do not show them connecting internally with any nerve passages, and they are located beneath the dorsum sellae where no cranial nerves originate. The only possible alternative is that these

paired lateral foramina could represent the interorbital canal containing the pituitary vein. However, CT scans indicate that the pituitary vein was probably located slightly farther anteriorly, in front of the narrow canal leading to the posterior chamber of the hypophysis (as described above), and the presence of external foramina in that location interpreted as the pituitary vein foramina in UERJ-PMB-40 further support that hypothesis. Additionally, because the pituitary vein typically joins the lateral head vein anterior to the postorbital processes (through which the latter vein passes on its way to the orbit), the large lateral foramina mentioned previously may well be located too far posteriorly to represent the pituitary vein.

In UERJ-PMB-40 (fig. 4), the posteroventral part of the braincase is well preserved, including both of the paired ventral processes. In this specimen, small, paired foramina are present just posterior to the occiput in ventral view, at the same level as the base of the small



pointed posterior processes located immediately lateral to the occiput. Similar paired foramina are also visible in UERJ-PMB-114 and AMNH 13961. Although it may appear at first glance that the paired lateral dorsal aortae entered the braincase here, as previously reconstructed in *Egertonodus* (Maisey, 1983), CT scan slices of *Tribodus* show no evidence of paired canals for the lateral dorsal aortae passing within the basicranial cartilage in the occipital region. However, CT scans do reveal the presence of paired narrow canals extending dorsomedially within the occipital region from these paired foramina, and opening dorsally into the posteromedial floor of the glossopharyngeal-vagus foramen on both sides of the braincase (figs. 9E, F, 11, 15–18: oc art). These canals may represent occipital arteries branching from the main trunk of the lateral dorsal aorta ventrally and entering the cartilage of the braincase to supply structures located farther dorsally. The paired ventral foramina just anterior to the occiput in *Tribodus* are thus interpreted here as entry points for the occipital arteries into the braincase. CT scans of *Egertonodus* show that its corresponding set of paired foramina also open into a similar pair of dorsally extending canals that also enter the glossopharyngeal-vagus foramen, changing the previous interpretation and indicating that at least two hybodonts (*Tribodus* and *Egertonodus*) have this arrangement of the occipital arteries and their foramina. Similarly positioned foramina for the occipital arteries have also been reported in the Carboniferous (Viséan-Namurian) hybodontiform *Tristychius arcuatus* (Dick, 1978). In *Tristychius arcuatus*, according to Dick (1978: 80; fig. 2), the ventral foramina of the occipital arteries are located within anteroposteriorly elongated, narrow indents for the “common carotid arteries” or lateral dorsal aortae. This is very similar to the arrangement found in *Egertonodus* (see Discussion), in which similar indents for externally located lateral dorsal aortae also contain the occipital artery foramina. In *Tribodus*, no external indents for the lateral dorsal aortae are visible, but it is likely that they traveled exterior to the braincase in the occipital region, connecting with the occipital arteries in an arrangement similar to that of *Egertonodus*

and *Tristychius*. In *Tristychius*, the occipital arteries emerge dorsolaterally posterodorsal to the vagus nerve foramina (Dick, 1978).

#### OTICO-OCCIPITAL REGION

**POSTORBITAL PROCESSES:** The postorbital processes in *Tribodus limae* (figs. 3A, C, 11–13: popr) are long, narrow, and tapered toward their distal ends; and are generally much more slender and gracile than those of *Egertonodus* (Maisey, 1983). Most of the left postorbital process is preserved in *Tribodus limae*, AMNH 13958 (although its distal part is missing), whereas the right postorbital process is not preserved except for its base. This is typical of most fossil hybodont specimens, in which the postorbital processes are often broken off or missing, and may reflect that these processes were only weakly attached to the braincase (Maisey, 1982, 1983). The postorbital processes originate on the lateral wall of the otic capsule, and extend anteroventrally at an angle of approximately 45° to the horizontal aspect of the braincase, defining the posterior margin of the orbit. These processes also extend farther laterally than the antorbital processes. Unlike *Egertonodus*, the widest part of the braincase in *Tribodus* is not the postorbital processes but the otic region farther posteriorly, at the point where the cephalic spines articulated. A large fenestra in the proximal part of the postorbital process is interpreted here as the jugular canal (figs. 3A, 8B, 11, 12: jc), through which passed the jugular or lateral head vein, and possibly also the hyomandibular ramus of the facial nerve (after exiting the braincase through the facial foramen). The supraorbital crest ends dorsal to the anterior margin of the base of the postorbital process, and is separated from it by a rounded notch.

According to Maisey (2008) and Holmgren (1940), the postorbital process in chondrichthyans forms ontogenetically from two structures: a primary process (which is a posterolateral outgrowth of the supraorbital shelf), and the lateral commissure (fused in part with the side wall of the otic capsule, and fused dorsally either with the otic capsule to enclose the hyomandibular trunk of the facial nerve, or with the ventrolateral margin of the

primary process to enclose the lateral head vein). Based on the structure and position of the postorbital process in *Tribodus*, it is concluded here that it was formed at least in part by the embryonic lateral commissure, which was chondrified in the adult. This interpretation is based on the fact that the postorbital process in *Tribodus* is fused dorsally and medially with the otic capsule and encloses the jugular canal, which presumably housed the lateral head vein. In the same way, a chondrified lateral commissure was probably also present in *Egertonodus*, as was suggested previously by Maisey (1983).

A postorbital articulation was absent in most hybodontiforms (including *Tribodus*), whose jaw suspension is hyostylic (except for *Tristychius*, which had a postorbital articulation; Dick, 1978; Maisey, 2008). Thus, unlike other fossil chondrichthyans with a lateral commissure (e.g., *Cladodoides*, Maisey, 2005; “*Cobelodus*,” Maisey, 2007), the postorbital process in most hybodonts lacks an articular facet for the palatoquadrate.

**OCTAVAL, GLOSSOPHARYNGEAL, VAGUS, AND SPINO-OCCIPITAL NERVES:** CT scan images of the interior of the braincase show two large foramina located posterior to the foramen for the hyomandibular ramus of the facial nerve, both of which exit into the otic capsule. These are here interpreted as having housed the anterior and posterior rami of the octaval nerve, respectively (figs. 8B, D–G, 14: VIII a, p). Posterior to the octaval nerve foramina and located ventrolaterally on the endocranial wall is a much smaller foramen (fig. 14: IX). This foramen is here interpreted as having housed the glossopharyngeal nerve, and joins the glossopharyngeal-vagus canal at a location ventral to the preampullary canal. It is positioned similarly to the glossopharyngeal nerve of neoselachians (e.g., *Squalus*, Marinelli and Strenger, 1959; Gegenbaur, 1872). After exiting the cranial cavity, the glossopharyngeal nerve traveled through a narrow canal beneath the otic capsule, which widens posteriorly (figs. 15, 16, 17B, 18: IX). This canal exits on the posterior of the braincase together with the vagus nerve through a single, shared foramen lateral to the foramen magnum on either side (figs. 3B, 9D–F, 10, 12B: IX, X). Each of these shared foramina is located

immediately anterior to the hyomandibular articulation, and is oval in outline.

In sagittal view, foramina for rami of the vagus nerve are visible as two small openings in the mesial wall of the braincase, posterior to the glossopharyngeal foramen (fig. 14: X). They are located beneath the domed roof of the medullary chamber, similar to the position of the internal vagus foramen in neoselachians (e.g., *Notorynchus*, Maisey, 2004b), and are arranged one above the other. These foramina open into canals that exit the braincase through the glossopharyngeal-vagus foramen.

**ROOF OF THE OTIC REGION:** The otic region of *Tribodus limae* (AMNH 13958) is relatively complete, although the right postorbital process is missing. As in *Egertonodus basanus*, the paired otic capsules in *Tribodus* constitute approximately one-third of the total length of the braincase. The parietal (endolymphatic) fossa is large, elongated, and ovate, and is located centrally between the otic capsules (figs. 3B, 10: p fos). An anterior pair of small, rounded foramina located laterally within the parietal fossa represent the endolymphatic foramina (figs. 10, 14: end f), and a more posterior pair represent the perilymphatic fenestrae (figs. 9A, 14: pf). Other than these two pairs of foramina, the parietal fossa has a continuous cartilaginous floor, probably formed by an embryonic taenia medialis, as in extant elasmobranchs (Holmgren, 1940) (fig. 8B: t med). In extant elasmobranchs, this structure can be produced either as a posterior outgrowth from the synotic tectum (e.g., *Squalus*), or as an anterior outgrowth from the posterior tectum (where one is present, e.g., *Scyllium*) (Holmgren, 1940). Paired elevated ridges in the cartilage located laterally, anterior and posterior to the parietal fossa, indicate the location of the anterior and posterior semicircular canals, respectively. The ridge overlying the anterior semicircular canal extends anterolaterally at an angle of approximately 35° from the midline of the specimen, while the posterior ridge extends laterally at about 45° to the midline.

As discussed previously, paired rectangular laterally concave areas located on the lateral part of the otic region represent the points of articulation for the cephalic spines (Maisey and Carvalho, 1997), indicating that AMNH




Fig. 25. Close-up of the head region of *Tribodus limae* (AMNH 13959) showing right cephalic spine in situ, after acid preparation. Anterior to the left. Scale bar is 1.5 cm.

13958 was a male (female specimens of *Tribodus* lack cephalic spines, as well as the paired platforms for their articulation; the posterolateral part of the braincase is instead smoothly rounded). The convex platforms for the cephalic spines in AMNH 13958 lack a covering of prismatic cartilage, and appear fibrous. A photograph of the original specimen immediately after acid preparation shows that the cephalic spines sat in these convex platforms with their cusps directed posteroventrally (fig. 25: csp). Posteromedial to the cephalic spine platforms are two lateral processes, here interpreted as lateral otic processes as in *Egertonodus* (Maisey, 1983) (figs. 3B, C, 10: lotpr). It has been suggested that the hyomandibula articulated on these processes (Maisey and Carvalho, 1997). This interpretation is supported by the new material of *Tribodus*,

which shows a rounded concave notch for the dorsal head of the hyomandibula on the medial surface of the lateral otic process on each side of the specimen, between the lateral otic process and a small, triangular, posteriorly directed process posteromedial to it (figs. 3A, 11, 12: hm art). The hyomandibular articulation is posterior and lateral to the glossopharyngeal-vagus foramen, and the lateral otic process is located entirely lateral to this foramen. Paired posterior triangular processes are located immediately posterior to the glossopharyngeal-vagus foramina, flanking the occiput laterally.

**CEPHALIC SPINES:** Cephalic spines of *Tribodus limae* have not previously been described or illustrated in any of the published literature (e.g., Brito and Ferreira, 1989; Brito, 1992), and the present paper represents the



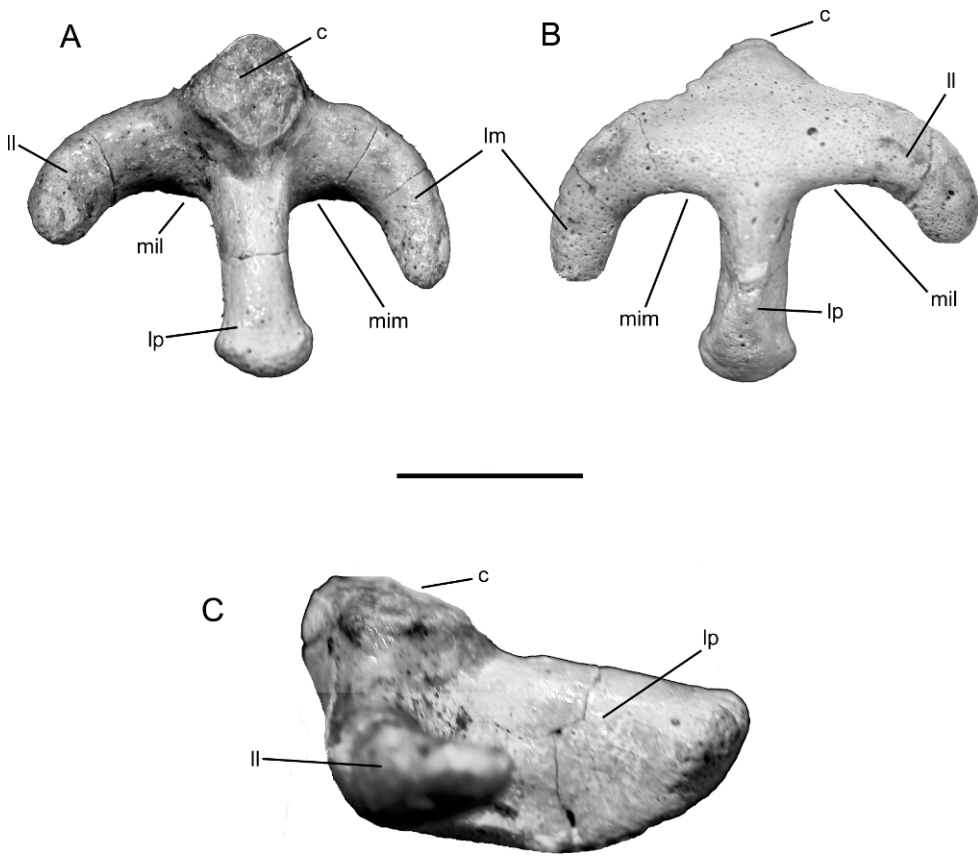


Fig. 26. (A) top, (B) bottom, and (C) lateral views of left cephalic spine of *Tribodus limae* (UERJ-PMB-40). Scale bar is 1 cm.

first description of the cephalic spines in this taxon (figs. 25–28). Spines are preserved in AMNH 13957 (figs. 27, 28A–C) and 13959 (figs. 25, 28D–E), and in UERJ-PMB-40. Cephalic spines of *Tribodus limae* are unicuspid, with a single, large, posteriorly recurved principal cusp and no accessory cusps (fig. 25–28). In AMNH FF 13959 (an exceptionally well-preserved right cephalic spine associated with a fragmented cranium and partial scapulocoracoid), the spine base is constricted and triradiate, with paired anterior lobes (medial and lateral) and a narrow posterior lobe (figs. 25, 28D–E). The cephalic spine base is also well preserved in UERJ-PMB-40, although the spine cusp is missing (fig. 26). When viewed from above, the spine base can best be described as anchor shaped. All three

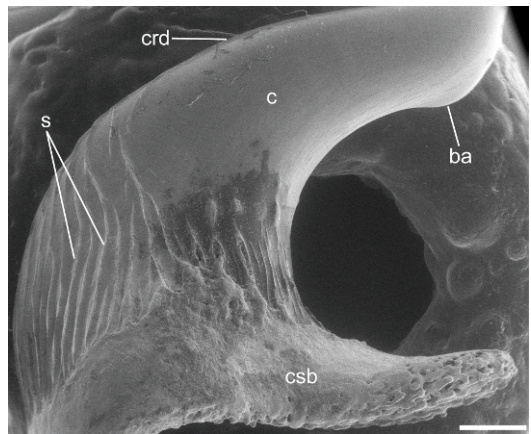


Fig. 27. SEM of *Tribodus limae* cephalic spine, AMNH 13959. Scale bar is 1 mm.



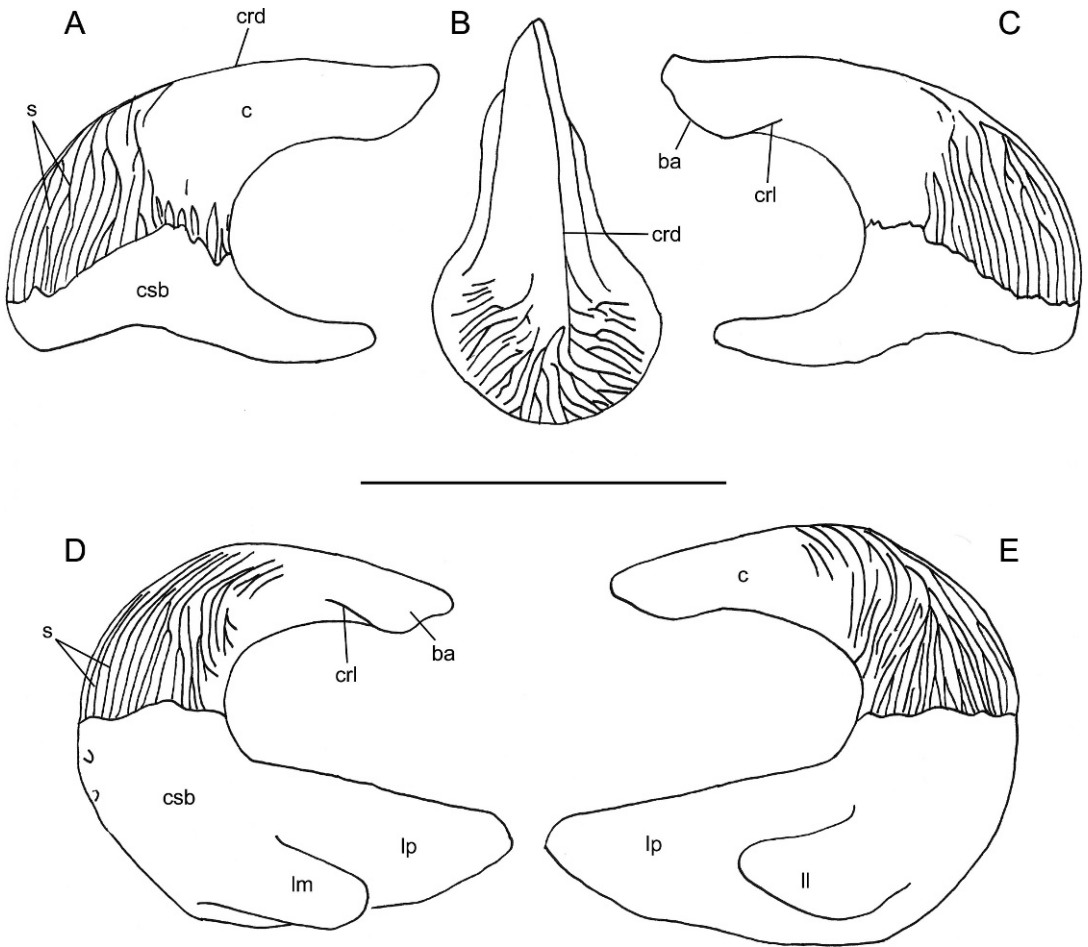


Fig. 28. *Tribodus limae* cephalic spines. A–C, AMNH 13957, left cephalic spine. A, lateral; B, dorsal; C, mesial views. D–E, AMNH 13959, right cephalic spine. D, mesial; E, lateral views. Scale bar is 1 cm.

basal lobes are of approximately equal length and are slender and elongate in shape. The medial (fig. 26: lm) and lateral (fig. 26: ll) lobes taper distally, whereas the distal part of the posterior lobe (fig. 26: lp) first narrows, then expands into a broader rounded distal tip. The medial and lateral lobes are posteriorly recurved, so that the entire spine when viewed from above (e.g., lateral view, if the spine were in situ) appears nearly symmetrical on both sides. The base of the cephalic spine is composed of a porous, spongy tissue, presumably osteodentine, whereas the cusp is covered with a thin, glossy layer of enameloid, as in most other hybodonts (Maisey, 1982, 1983).

The cephalic spine cusp in *Tribodus* is slender but not acuminate, in that it shows a

distal barb apically (fig. 27: ba). The proximal part of the cusp is strongly ornamented with a series of vertical ridges anteriorly, some of which bifurcate toward the cusp base. These ridges converge approximately halfway up the spine cusp, where they join a sharp, narrow ridge, located slightly off center, which extends from here to the spine apex. The posterior and laterodistal sides of the spine cusp are unornamented except for a few faint parallel ridges on the posterior proximal end of the cusp, just above the spine base. In AMNH FF 13957, a left cephalic spine associated with a nearly complete fish, most of the spine base is lacking, showing the presence of a large pulp cavity in the interior of the cusp. In side view, all three lobes of the

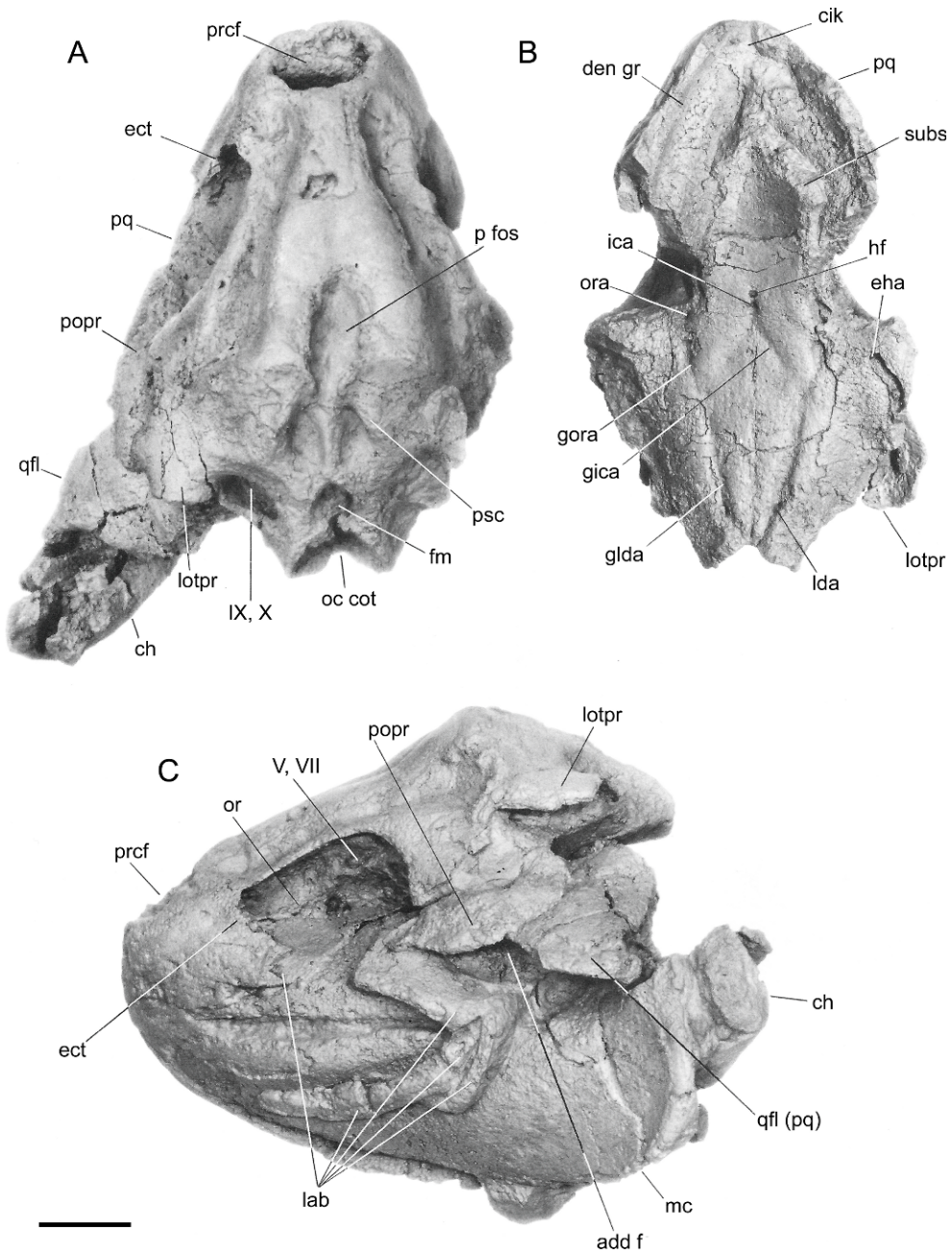


Fig. 29. Braincase of *Egertonodus basanus* BM(NH) P60110, which was CT scanned for the present study. A, dorsal; B, ventral, and C, left lateral views. After Maisey, 1983. Features labeled according to Maisey's (1983) original description; an alternative interpretation is presented in figs. 29–33 and in the text of the present paper. Scale bar is 2 cm.

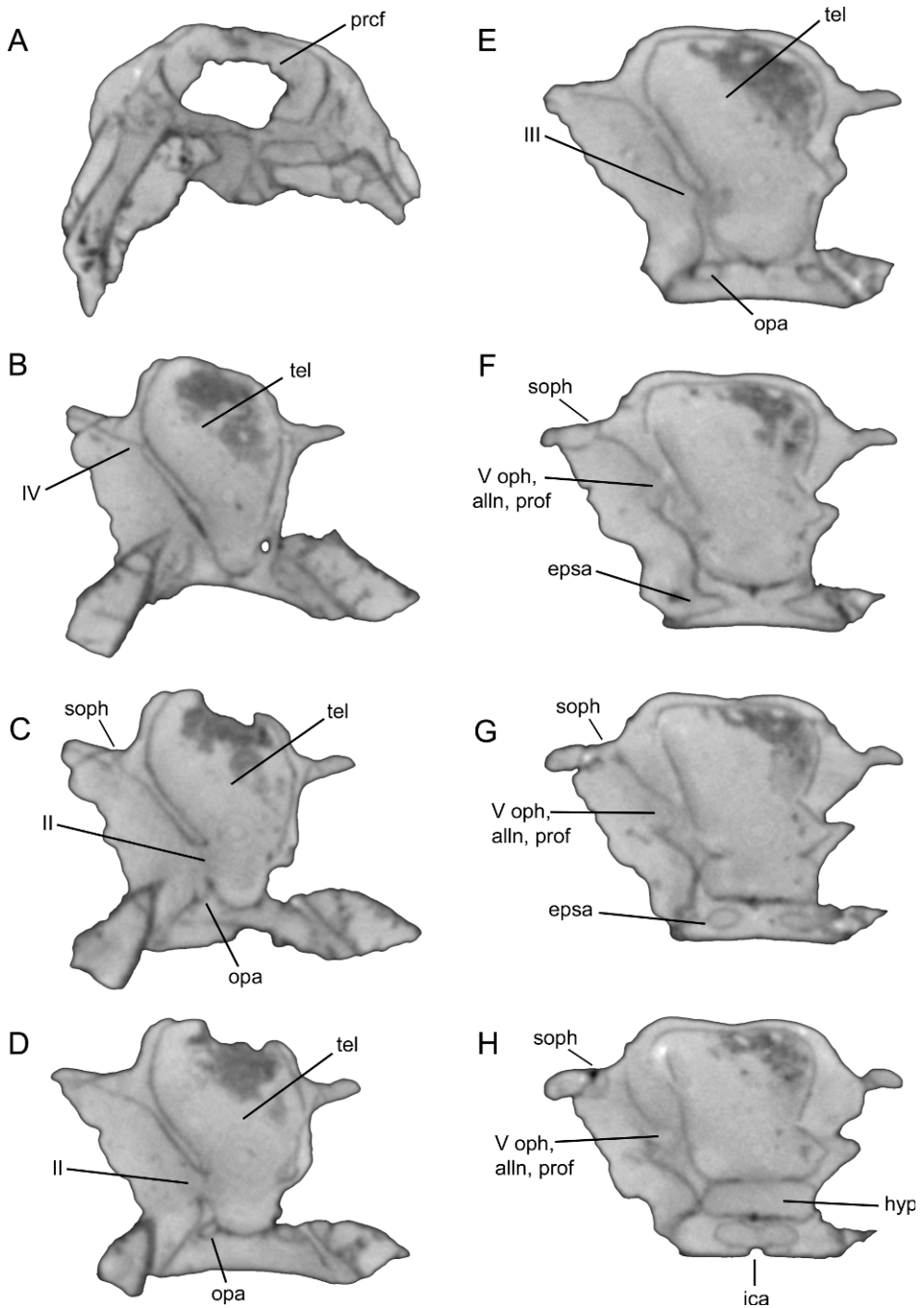


Fig. 30. Transverse CT scan slices of the *Egertonodus* braincase, BM(NH) P60110. Ethmoidal and orbital regions. No scale.

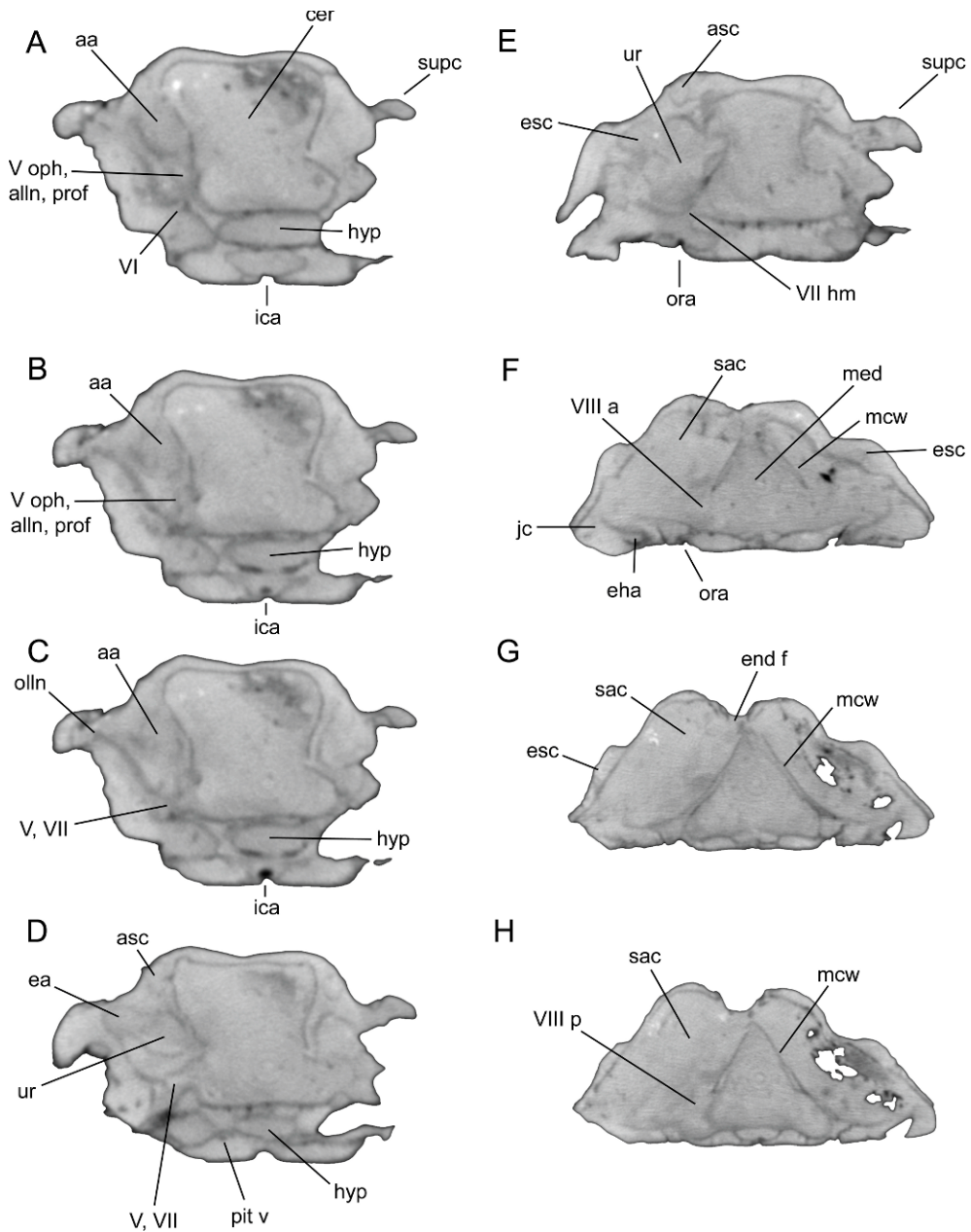


Fig. 31. Transverse CT scan slices of the *Egertonodus* braincase, BM(NH) P60110. Orbital and otic regions. No scale.

spine base slope downward posteroventrally. In *Tribodus*, the posterior lobe of the spine base extends slightly farther posteriorly than the spine apex. The distal part of the cusp is approximately horizontal in side view.

As originally preserved (prior to preparation), the cephalic spine of AMNH FF 13959 was located nearly in situ, allowing its approximate life position to be determined (fig. 25). This specimen shows that the cephal-



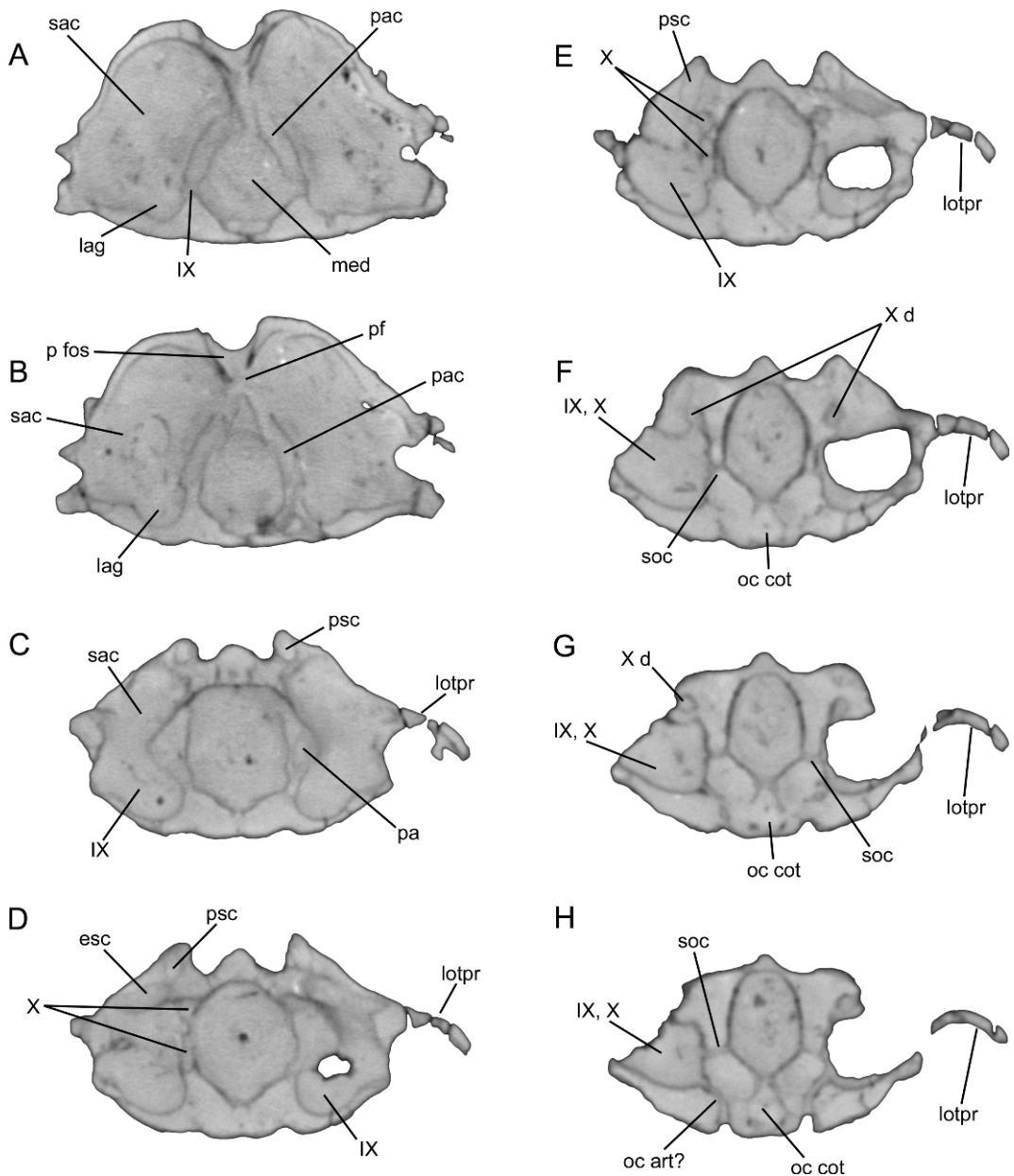


Fig. 32. Transverse CT scan slices of the *Egertonodus* braincase, BM(NH) P60110. Otic and occipital regions. No scale.

ic spine in *Tribodus limae* was located on the lateral surface of the otic region just behind the postorbital process, in a broad, rectangular, concave platform (best preserved in AMNH FF 13958). Its location most closely approximates that of the cephalic spines

located above the lateral otic process in *Egertonodus basanus*, *Egertonodus fraasi*, *Hybodus hauffianus*, and *H. delabechei*, although in *Tribodus* the spine platform is located much farther ventrally, possibly representing a ventral elongation of the lateral

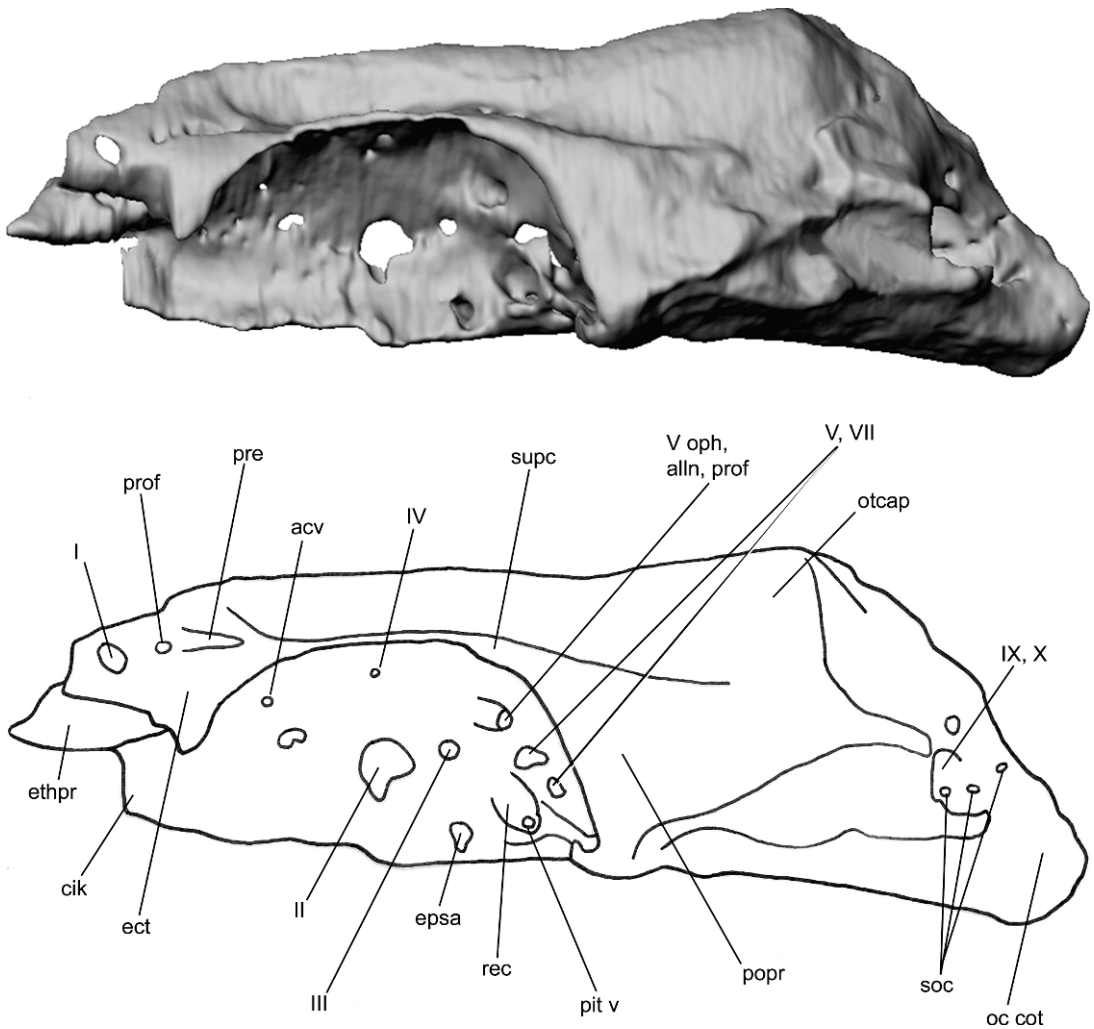


Fig. 33. Lateral view of the *Egertonodus* braincase (NHM P60110), anterior to the left (surface rendering). No scale.

otic process. There is no evidence of more than a single pair of cephalic spines in *Tribodus*, as is also the case in *Egertonodus basanus*.

Cephalic spines of *Tribodus limae* differ from those of *Hybodus*, *Egertonodus*, *Acrodus*, and *Asteracanthus* (e.g., genera having “*Sphenonchus*”-type cephalic spines) in that the latter taxa have a much thicker and more robust spine base, in which the lobes are much less constricted. However, *Tribodus* cephalic spines are similar to spines of these taxa in having a barbed tip, and a dorsal, mesial, lateral, and posterior crest (see Maisey, 1982, 1987). They also differ in that the spine base in *Tribodus* is

more bilaterally symmetrical than in these taxa. *Tribodus* cephalic spines are morphologically very different from those of *Hamiltonichthys mapei*, which has an unconstricted spine base, multiple accessory cusps, and no ornamentation (Maisey, 1989). They also differ considerably from cephalic spines of *Onychoselache*, which have more than one principal cusp and a broad, unconstricted spine base.

**FORAMEN MAGNUM AND OCCIPUT:** Situated directly between the paired glossopharyngeal-vagus foramina on the posterior of the braincase is the foramen magnum, through which the spinal cord exited the braincase

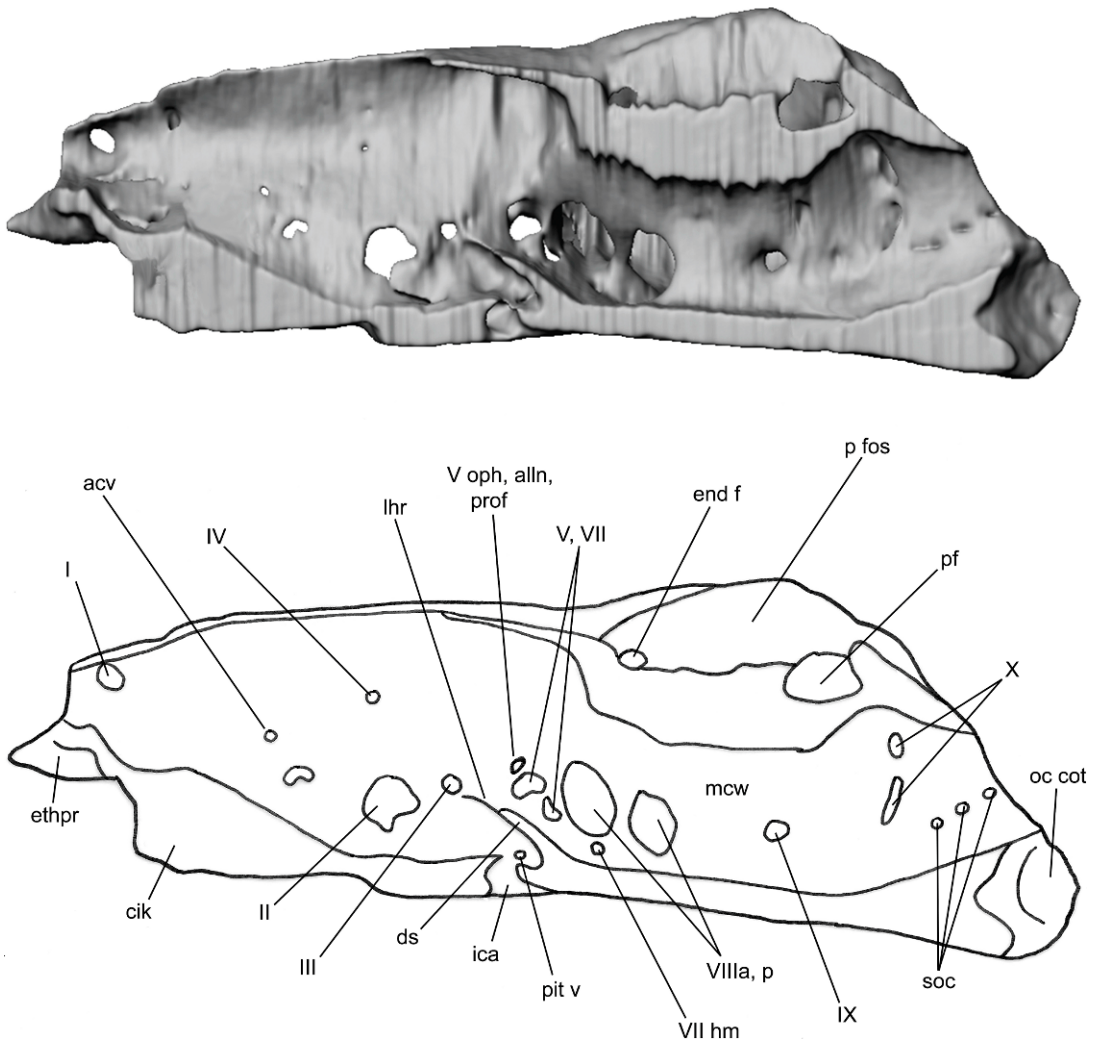


Fig. 34. Medial view of the *Egertonodus* braincase (NHM P60110), sliced through the sagittal plane, anterior to the left (surface rendering). No scale.

(figs. 3B, 10, 12B, 13: fm). The foramen magnum is a rounded opening, slightly elongated dorsoventrally. Above the foramen magnum is a dorsally extending occipital crest, which terminates at the posterior margin of the parietal fossa, representing the point of closure of the occipital arch during ontogeny. A similar crest is seen in *Notorynchus* (Maisey, 2004b). The occipital cotylus, located directly ventral to the foramen magnum (figs. 3A, 9C–F, 11, 12B, 13: oc cot), is fibrous and has a concave posterior surface, as in *Egertonodus* (Maisey, 1983). The lateral sides of the occiput

are fully formed, but the dorsal and ventral sides are not well developed and the occipital cotylus opens dorsally into the foramen magnum. Like other hybodonts (such as *Egertonodus*, Maisey, 1983), and unlike the condition in extant neoselachians, there is no occipital hemicentrum in *Tribodus* (and this form also lacks calcified vertebral centra, as do other non-neoselachian elasmobranchs). The occipital region in *Tribodus* is broader than in *Egertonodus*, and the occiput does not extend as far posteriorly behind the otic capsules as it does in *Egertonodus*. This feature

of *Tribodus* is similar to many modern sharks, in which the occiput is also situated between the otic capsules (Maisey, 1983).

#### ENDOCRANIAL SPACE, CRANIAL ENDOCAST, AND SKELETAL LABYRINTH

**CRANIAL ENDOCAST AND ENDOCRANIAL SPACE:** A generalized description of endocranial morphology in *Tribodus* was provided by Maisey (2004a) as part of a comparative study of elasmobranch neurocrania. However, a detailed description of endocranial morphology in *Tribodus* has not yet been provided, and a reconstruction of the cranial endocast in *Tribodus* (or any other hybodont) has not been presented until now. The cranial endocast of *Tribodus* is similar in many respects to that of some extant neoselachians such as *Notorynchus*, particularly in dorsal and lateral views. As in *Notorynchus* and *Squalus*, the telencephalic chamber broadens anteriorly, with proportionally thick olfactory canals and widely spaced olfactory chambers (figs. 15, 16: tel). This condition is unlike that of *Cladodoides* (Maisey, 2005), in which the telencephalic region is more narrow and uniform in width from side to side, and actually narrows anterior to the cerebellar chamber. It is also considerably different from “*Cobelodus*” (a tropibasic form), in which the endocast is extensively foreshortened and the telencephalic region also tapers anteriorly in dorsal view. As Maisey (2004a) also pointed out, in both *Tribodus* and *Egertonodus* the floor of the telencephalic chamber above the median ventral process is flat to slightly convex and does not follow the shape of the underlying external morphology (fig. 14), a feature shared with neoselachians. As noted by Maisey (2004a), no constriction between the telencephalic and mesencephalic regions (such as that found in *Squalus*) is present in *Tribodus*. Also, the myelencephalic (medullary) chamber of *Tribodus* is domed as in *Notorynchus* and *Squalus*, as pointed out by Maisey (2004a). The vagus (X) nerve exits the cranial cavity in a similar location to that of *Notorynchus* and *Squalus*, near the center of the medullary chamber (figs. 14, 15, 17, 18: X).

Maisey (2004a) noted that in both *Tribodus* and *Egertonodus*, the optic foramen is posi-

tioned centrally within the orbit and the trochlear foramen is located anterior and dorsal to the optic foramen, which he describes as an unusual configuration for elasmobranchs (in which the trochlear foramen is typically dorsal, but posterior to the optic foramen). This is confirmed by CT scans and digitally reconstructed endocasts of both *Tribodus* and *Egertonodus* that show a lateral outgrowth in the correct position on the endocast to correspond to the trochlear nerve (figs. 15, 16, 18: IV). The optic artery also probably exited the braincase through the optic foramen, alongside the optic nerve.

Posterodorsal to the optic foramen on the *Tribodus* endocast is a smaller outgrowth, located directly above the anterior part of the infundibular region. This is in the correct position to correspond to the oculomotor nerve of many extant neoselachians (figs. 16, 18: III). It exits the braincase through a small foramen immediately anterior to the trigeminofacialis recess. Ventral to this, the infundibular region extends posteriorly to form a hypophyseal chamber (figs. 8A, B, 12A: hyp), visible in ventral and lateral views of the endocast (figs. 16, 18). At the rear of the infundibular/hypophyseal region immediately anterior to the dorsum sellae are paired lateral extensions, here interpreted as the pituitary veins (fig. 16: pit v), and comparable to those of *Cladodoides* (Maisey, 2005). Posterior to this, the hypophyseal chamber constricts to form a narrow medial tube, which joins posteriorly with a large chamber beneath the dorsum sellae (figs. 16, 18: hd). A median ventral extension from this chamber (fig. 16: hf) may represent either an open hypophyseal duct or a foramen for the internal carotid arteries, although the former interpretation is considered here more likely (see above discussion). From the anterolateral sides of this chamber, paired elongated tubes extend forward, joining the cranial endocast posterior to the optic nerve and below the oculomotor nerve (figs. 16, 18: ica). These paired canals were probably for the internal carotid arteries, which tunnel through the basicranial cartilage before entering the braincase and joining two additional vessels, the efferent pseudobranchial/ophthalmic arteries and the optic arteries (in order anteriorly). From the lateral sides of



this chamber extend two additional sets of openings that exit the braincase laterally. Of these, the anterior pair of openings is here interpreted as the orbital arteries (figs. 16, 18: ora), and the posterior pair is interpreted as the efferent hyoidean arteries (fig. 16: eha). From the posterior part of this chamber, paired canals extend posterolaterally (figs. 16, 18: lda). These are here considered to represent the lateral dorsal aortae, which entered the braincase through paired posterior foramina (at the base of the paired ventral basicranial processes) and traveled anteriorly to enter the aforementioned chamber. They then joined the orbital arteries, and continued anteromesially as shortened internal carotid arteries before joining inside the chamber and dividing again to progress anteriorly.

An acoustico-trigemino-facialis recess (De Beer, 1937: 56) is visible on the internal lateral wall of the sagittally sectioned half braincase of *Tribodus* (fig. 14), and a corresponding lateral extension appears on each side of the cerebellar region in the endocast (figs. 15, 16, 18). This recess contained the proximal trunks of the trigeminal, facial, anterior lateral line, and octaval nerves. According to De Beer (1937) and Allis (1914), this space is intramural (mesial to the wall of the braincase) in modern *Squalus* but not intracranial, because it is located external to the dura mater, which may have also been the case in *Tribodus*. In the anterior-most part of this recess on the endocast is a forward-directed canal. This canal divides immediately anterior to exiting the cranial cavity, forming a large dorsal canal and a narrower ventral canal. The larger canal is here interpreted as having housed the superficial ophthalmic complex, and possibly also the profundus nerve (figs. 15, 16, 18: V oph, alln, prof).

The smaller canal may represent the abducens nerve (figs. 16, 18: VI), originating on the ventral surface of the brain and extending anterodorsally to exit the braincase into the orbit in the vicinity of the trigemino-facialis recess. It may alternatively represent the profundus nerve (discussed above); however, this interpretation is considered less likely because the abducens nerve would then have to exit the braincase farther posteriorly, away from the external rectus muscle, which it innervates. Posteroventral to the superficial

ophthalmic and abducens canals is a second lateral extension from the acoustico-trigemino-facialis recess, interpreted as the main trunk of the trigeminal and anterodorsal lateral line nerves (which exit through the trigemino-facial foramen; figs. 15, 16, 18: V, VII). Two larger lobes immediately posterior to this on the endocast are here considered to be the anterior and posterior branches of the octaval nerve, respectively (figs. 15, 16: VIII).

Posterior to the acoustico-trigemino-facialis recess and hypophyseal chamber, the dorsal surface of the endocast slopes downward, forming a saddlelike depression into which the skeletal labyrinth fits (figs. 15, 18, 19, 21, 22). Posterior to this, the medullary chamber again expands dorsally, forming a rounded dome (figs. 14, 15, 18). The notochord is visible as an elongated median extension from the ventral surface of the medullary region (figs. 16–18: nt). Dorsolateral to the notochord, at the anterior end of the medullary dome, a small, paired extension from each side of the endocast represents the glossopharyngeal nerve (figs. 15, 16, 18: IX). Posterior to these, two additional pairs of canals extending from the dorsal and lateral sides of the medullary dome represent the vagus nerve (figs. 15, 17B, 18: X). These canals extend posterolaterally and exit the braincase posteriorly together with larger, more laterally located canals (emerging from the ventral sides of the skeletal labyrinth, and containing the glossopharyngeal nerves) inside the large glossopharyngeal-vagus foramina. However, although the two nerves share a common foramen to exit the braincase, they do not share a single canal opening into this foramen, and instead enter the lumen of the glossopharyngeal-vagus foramen through separate smaller foramina. Posteromedial to the glossopharyngeal-vagus foramina, the medullary chamber narrows, terminating posteriorly at the foramen magnum. At least three pairs of spino-occipital nerve canals extend laterally from the sides of the medullary chamber (figs. 14–17: soc), and several of them enter the glossopharyngeal-vagus foramen. Posteriorly, small canals extending dorsolaterally from the floor of the braincase and opening into the glossopharyngeal-vagus foramina represent paired occipital arteries (figs. 15–18: oc art).

**SKELETAL LABYRINTH:** The skeletal labyrinth of *Tribodus limae* was figured and briefly described by Maisey (2005). Digital imaging of CT scans for the present work confirm Maisey's description for the most part, except that the foramen for the octaval nerve appears to have been divided by a narrow band of cartilage to form separate foramina for the anterior and posterior rami of the octaval nerve (figs. 8B–G, 14, 15–16, 18, 20). As in neoselachians and *Egertonodus* (and unlike many Paleozoic chondrichthyans such as *Cladodoides* and *Cobelodus*; Maisey, 2005, 2007), a medial capsular wall is present in the otic region, separating the skeletal labyrinth from the main endocranial cavity housing the brain (figs. 8B–H, 14: mcw). This wall is fused with the parachordal-derived floor of the braincase ventrally, and with the roof of the otic region, except where it is penetrated by foramina. Anteriorly, two large foramina in the mesial wall of the braincase open into the otic capsule. These are here interpreted as separate passages for the anterior and posterior branches of the octaval nerve, which supplies the inner ear. In most gnathostomes, the anterior branch of this nerve innervates the utricular macula and the cristae of the anterior and external ampullae, whereas its posterior ramus innervates the posterior of the ear, including the preampullary canal, saccular and lagenar maculae, and macula neglecta (Cordier, 1954: 228; Maisey, 2001a).

As in all gnathostomes (Maisey, 2001a; Liem et al., 2001: 414), the skeletal labyrinth of *Tribodus limae* includes three semicircular canals: the anterior, external (or horizontal), and posterior canals (figs. 19–22). These canals are narrow and elongate. As in other gnathostomes, the ampullae of the anterior and external canals are directly connected to the utriculus anteriorly. As in neoselachians and most gnathostomes, a utricular recess is present (fig. 20, 21A, 22: ur). The saccular chamber is large and rounded, and a small lagena is present posteroventrally (figs. 9B, 22: lag). Dorsally, the labyrinth opens externally via two foramina, the endolymphatic foramen anteriorly (fig. 19: end f) and the perilymphatic foramen posteriorly (figs. 19, 21B: pf). These are paired structures, occurring on either side of the parietal fossa. The positions of the

endolymphatic and perilymphatic ducts are similar to those of neoselachians, with the endolymphatic duct originating near the base of the anterior semicircular canal dorsally, and the perilymphatic duct originating from the dorsal margin of the posterior semicircular canal. As in neoselachians, the posterior semicircular canal of *Tribodus* forms an almost complete circuit, with a narrow preampullary canal (fig. 20: pac) connecting the posterior ampulla with the sacculus and perilymphatic fenestra. However, the preampullary canal is tilted upward anterodorsally, rather than almost vertical as it is in *Notorynchus* (Maisey, 2005: fig. 36). As in most gnathostomes, the semicircular canals are arranged at right angles to one another, with the two vertical canals aligned at a 90° angle to each other and both of them perpendicular to the horizontal (external) canal. The external canal extends laterally beyond the margin of the saccular chamber, leaving a narrow space between it and the sacculus. The semicircular canals appear proportionally narrower than those of neoselachians such as *Notorynchus* (Maisey, 2005: fig. 36), whereas the saccular chamber is proportionally larger, forming nearly half the antero-posterior length of the skeletal labyrinth. Like neoselachians and unlike most other craniates, a crus commune and sinus superior are absent in *Tribodus*, as Maisey (2001a, 2005) previously pointed out.

#### ENDOCRANIAL MORPHOLOGY OF *EGERTONODUS BASANUS*

In addition to the material of *Tribodus limae* already mentioned, a braincase of *Egertonodus basanus* (NHM P60110, originally described by Maisey, 1983; this paper: fig. 29), was also CT scanned for the present study. These CT scans (figs. 30–32) of the braincase and cranial endocast of *Egertonodus basanus*, as well as 3-D digital images made from these CT scans for the present study (figs. 33–35, 36A–C), confirm many of Maisey's (1983) interpretations based on its external structure, providing a clearer understanding of cranial morphology in a hybodont other than *Tribodus*.

Although the braincase of *Egertonodus* examined here is not as well preserved as that of *Tribodus*, and is partly crushed, enough

detail is preserved to allow useful comparisons with *Tribodus*. A digitally reconstructed sagittal section (fig. 34) reveals that *Egertonodus*' internal cranial morphology was similar to that of *Tribodus*, but with several notable differences. The overall shape of the cranial cavity is similar to that of *Tribodus*, with a telencephalic region that broadens anteriorly in dorsal view (although less so than in *Tribodus*), a narrowing beneath the otic region, and a domed medullary chamber. As in *Tribodus*, there is a large optic foramen some distance anterior to the tip of the dorsum sellae (fig. 34: ds), and centrally located within the orbit (figs. 33, 34: II). A narrow groove posteroventral to the ventral edge of the optic foramen (fig. 34) probably represents the path of the optic artery, which may have exited the braincase through the optic foramen alongside the optic nerve as in *Tribodus*. Anterodorsal to the optic foramen is a small foramen, interpreted here as the trochlear nerve (figs. 33, 34: IV) and positioned similarly to that of *Tribodus*, but unlike that of most nonhybodont chondrichthyans.

The dorsum sellae (fig. 34: ds) is shorter anteroposteriorly than that of *Tribodus* (fig. 14: ds), and slants upward dorsally to form a larger angle (approximately 45°) with the floor of the braincase than in *Tribodus*. As in *Tribodus*, the oculomotor foramen is located above and anterior to the tip of the dorsum sellae, but it is closer to the dorsum sellae in *Egertonodus*. At the posterior of the hypophyseal chamber beneath the dorsum sellae is a small foramen, interpreted here as housing the pituitary vein (fig. 34: pit v). It exits the braincase externally through a small foramen in the trigeminofacialis recess at the back of the orbit (fig. 33: pit v), in the position that Maisey (1983) interpreted as containing the efferent pseudobranchial artery. In *Tribodus*, the pituitary vein exits the braincase farther posteriorly relative to the orbit, at the level of the postorbital processes. Beneath the pituitary foramen in *Egertonodus* is a small chamber in the basicranial cartilage, which opens ventrally through the median basicranial foramen. This chamber connects anterolaterally with paired canals, which travel a short distance anteriorly before exiting the braincase through ventrolaterally positioned

foramina (fig. 30 F, G, 33: epsa). These foramina are located posteroventral to the optic foramen, anteroventral to the pituitary foramen, and directly below the oculomotor foramen, and are interpreted here as the efferent pseudobranchial foramina. Here the morphology departs somewhat from that of *Tribodus*, in which a similarly positioned chamber below the dorsum sellae houses the orbital arteries, and the efferent pseudobranchial arteries are located more anteriorly. However, as in *Tribodus* (and most other chondrichthyans except embryonic *Torpedo*: Holmgren, 1940), the efferent pseudobranchials are located anterior to the pituitary vein foramina. Unlike *Tribodus*, the median basicranial foramen opens at the convergence point of external grooves in the basicranial cartilage (fig. 29B), and it seems fairly certain that in *Egertonodus* these grooves contained the internal carotid arteries and other vessels of the basicranial arterial circuit, which traveled external to the basicranial cartilage. Unlike *Tribodus*, the median ventral foramen probably contained the internal carotid arteries (possibly alongside an open hypophyseal duct), and there are no ventral canals within the cartilage posterior to the median foramen in *Egertonodus*.

Directly above and behind the tip of the dorsum sellae in *Egertonodus* is a laterally located acoustico-trigeminofacialis recess. At the anterior end of this recess are two large foramina, one anterior and slightly dorsal to the other. The more dorsally located foramen leads to an anteriorly directed canal (fig. 34: V oph, alln, prof). This opens into the orbit via a foramen (fig. 33) designated by Maisey (1983) as the main trigeminofacialis (V, VII) foramen (fig. 29C). Its position is identical to that of the superficial ophthalmic canal in *Tribodus*, and is also interpreted here as housing the superficial ophthalmic complex and profundus nerve. As in *Tribodus*, a smaller canal diverges ventrally from the former, but it travels through the cartilage for a much shorter distance (fig. 31A: VI), and exits at the anterodorsal end of a larger foramen (figs. 33, 34: V, VII) located posteroventral to the superficial ophthalmic foramen. This foramen was originally designated by Maisey (1983) as housing the hyomandibular ramus of nerve VII. It is similar in position to that of

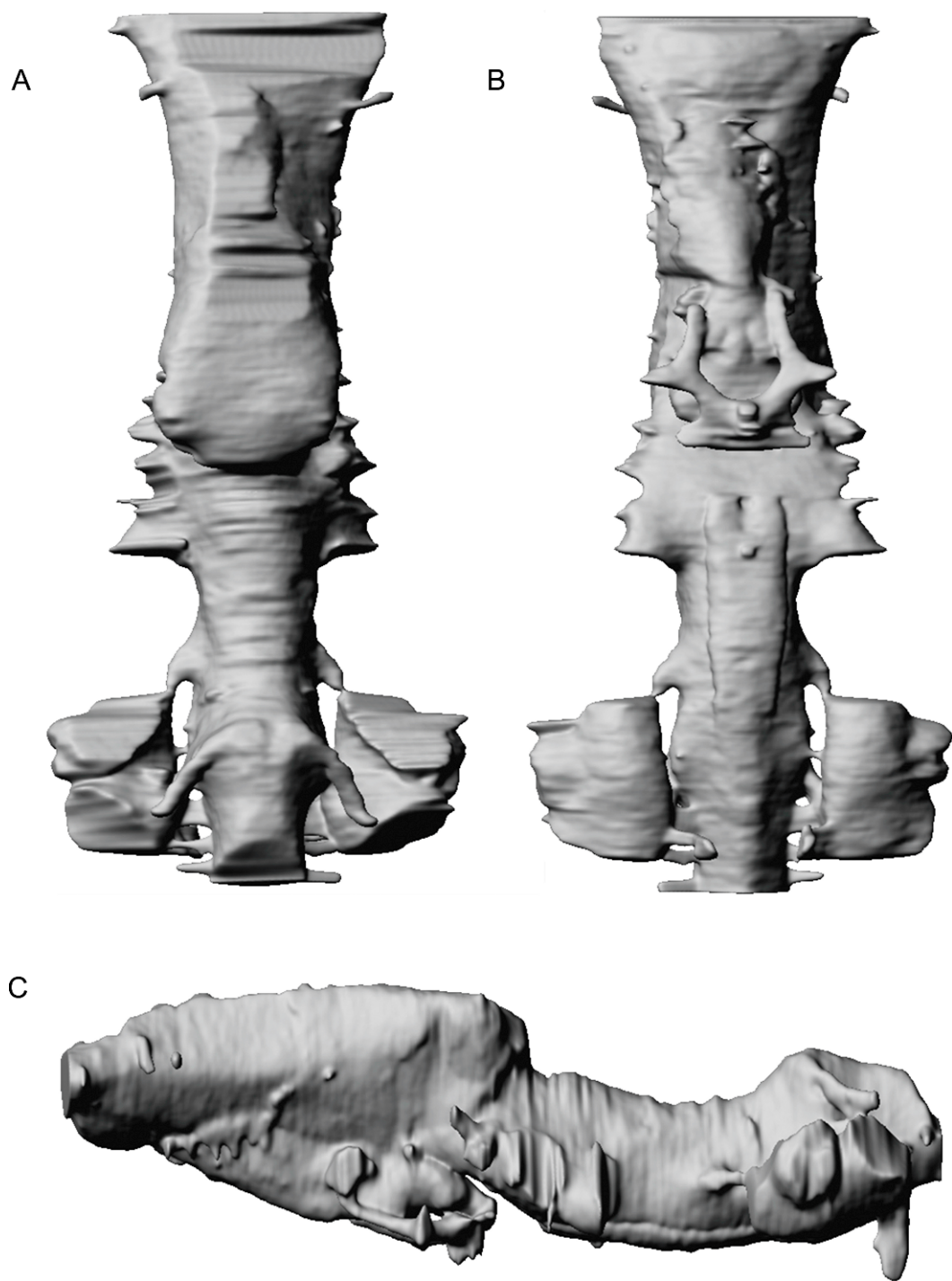


Fig. 35. **A**, dorsal; **B**, ventral; and **C**, lateral views of the *Egertonodus* endocast (surface renderings). No scale.



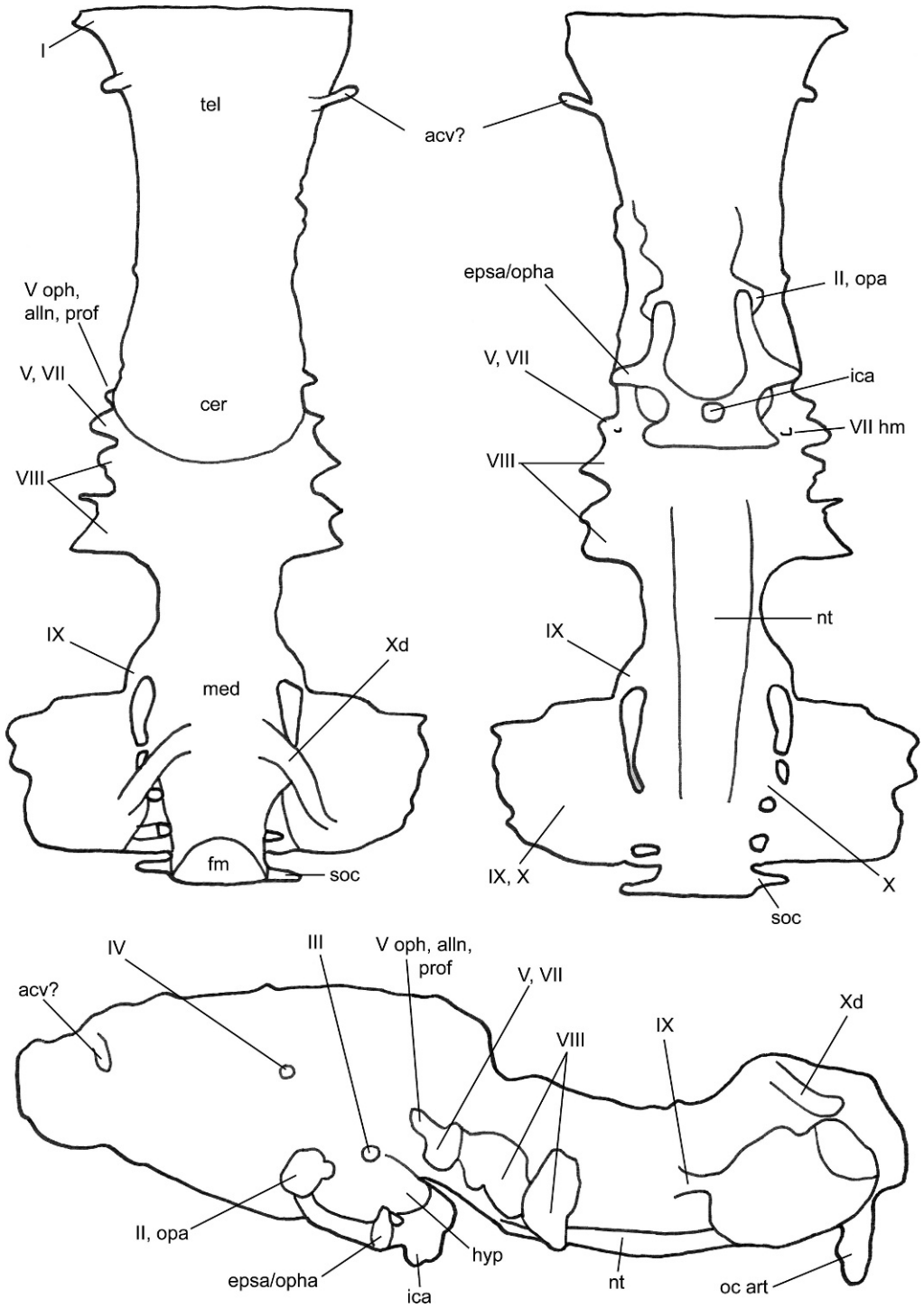


Fig. 35. *Continued.*

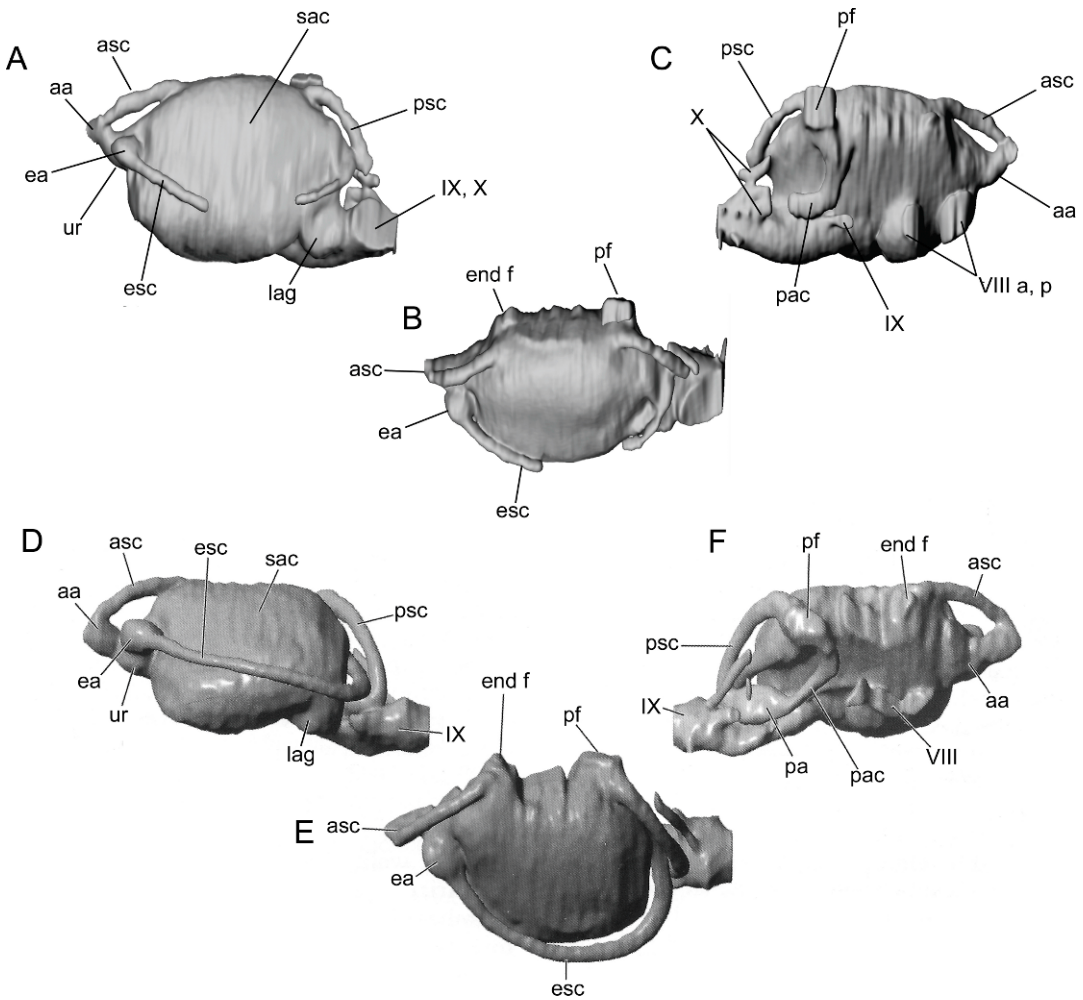


Fig. 36. A–C, Skeletal labyrinth of *Egertonodus basanus* (surface renderings), A, lateral; B, dorsal; C, medial views. D–F, Skeletal labyrinth of *Tribodus limae*, reconstructed by Maisey (2005), D, lateral; E, dorsal; F, medial views. No scale.

the main trigeminal-anterodorsal lateral line nerve canal of *Tribodus*, and is here interpreted as also representing the main trunk of those nerves (as in *Tribodus*).

An additional foramen located posteroventral to the main V–VII foramen in *Egertonodus* is here interpreted as housing the hyomandibular ramus of the facial nerve (figs. 31E, 34, 35: VII hm). Its position in relation to the main V–VII foramen is similar to that of the hyomandibular foramen in *Tribodus*. In *Egertonodus*, this foramen (fig. 31E: VII hm) is directed posteroventrally, and is located directly dorsal to a small

foramen in the suborbital shelf (fig. 31E: ora), identified by Maisey as the anterior foramen for the orbital artery (fig. 29B: ora). It is possible that the palatine ramus of the hyomandibular trunk passed ventrally through this foramen to reach the roof of the mouth, whereas the hyoid ramus may have curved posterolaterally to enter the jugular canal on its way to the hyoid arch.

Immediately posterior to the hyomandibular foramen in medial view of the braincase is a pair of much larger foramina, which open into the otic capsule (fig. 34: VIII). These are interpreted as representing the anterior and

posterior rami of the octaval nerve, as in *Tribodus*. A smaller foramen posterior to the octaval foramina, and ventral to the anterior edge of the perilymphatic fenestra, is interpreted as the glossopharyngeal foramen (fig. 34–35: IX). As in *Tribodus*, it opens into the posterior floor of the otic capsule, and continues posteriorly. Paired foramina for rami of the vagus nerve are located beneath the dome of the medullary region, as in *Tribodus* (figs. 34–35: X, X<sub>d</sub>) and the canals leading from the vagus and glossopharyngeal foramina also converge to exit externally through a common glossopharyngeal-vagus foramen. At least three spino-occipital nerves are present posteroventrally within the medullary region, as in *Tribodus* (figs. 32F–H, 34–35: soc).

**SKELETAL LABYRINTH OF *EGERTONODUS*:** The otic region of *Egertonodus basanus* examined for the present paper is not as well preserved as that of *Tribodus limae*. The skeletal labyrinth is best preserved on the right side of the specimen, but in the CT scans its lining of prismatic cartilage is faint and difficult to trace, particularly in the ventrolateral part of the saccular chamber and the proximal part of the preampullary canal. Nevertheless, it is well enough preserved to allow the skeletal labyrinth of *Egertonodus* to be reconstructed via digital imaging (fig. 36A–C). As in *Tribodus*, a medial capsular wall is present in the otic region of *Egertonodus* (fig. 31F–H, 34: mcw), separating the skeletal labyrinth from the rest of the endocranial cavity and containing foramina for the octaval, glossopharyngeal, and vagus nerves. Like *Tribodus*, there are two large foramina anteriorly that open into the otic capsule, which probably housed the anterior and posterior branches of the octaval nerve. The presence of two octaval foramina in *Tribodus* and *Egertonodus* may indicate a hyodont synapomorphy, and is lacking in neoselachians. As in *Tribodus* and neoselachians, the glossopharyngeal nerve passes through the wall of the endocranium in the medullary region, ventral to the preampullary canal and anterior to the vagus nerve. As in *Tribodus* and neoselachians, the glossopharyngeal nerve is located ventrally in the endocranial wall. After exiting the endocranial space, it passes via a narrow canal into the glosso-

pharyngeal-vagus foramen, as in *Tribodus*. Posterior to the glossopharyngeal foramen is a pair of additional foramina, here interpreted as housing rami of the vagus nerve. One of these is located dorsally near the dome of the medullary region, and the other is located ventrally below it. Both of these foramina join canals that connect with the glossopharyngeal-vagus foramen, and the more dorsal canal continues farther laterally, exiting the braincase dorsal to the glossopharyngeal-vagus canal.

The skeletal labyrinth of *Egertonodus* (fig. 36A–C) is similar to that of *Tribodus* (fig. 36D–F) and other gnathostomes (fig. 37) in its overall structure. The anterior, external, and posterior semicircular canals are arranged as in *Tribodus*, and a utricular recess is present anteriorly communicating directly with both the anterior and external ampullae as in many gnathostomes. A crus commune and sinus superior are absent in *Egertonodus*, as in *Tribodus* and neoselachians, and the anterior and posterior semicircular canals are widely spaced dorsally. Like *Tribodus* and neoselachians, in *Egertonodus* an endolymphatic foramen is present anterodorsally, and a perilymphatic foramen is present posterodorsally (fig. 36B: end f, pf). The posterior semicircular canal forms a complete circuit, with a preampullary canal (figs. 32A, B, 36C: pac) connecting the posterior ampulla with the saccular chamber and perilymphatic fenestra. A small lagenar chamber is present in the posterior of the saccular region (figs. 32A, B: lag), as in *Tribodus*. In both *Egertonodus* and *Tribodus*, the external semicircular canal passes mesial to the posterior canal.

## DISCUSSION

### COMPARISON OF CRANIAL CIRCULATION IN ELASMOBRANCHS

A reconstruction of the cranial circulation and relevant vascular foramina of *Tribodus* (figs. 38, 39) is presented here and discussed below in comparison to that of other fossil and extant elasmobranchs (fig. 40). Information from CT scan images and the positions of external foramina indicate that the configuration of the cranial circulation in *Tribodus* was complicated, and appears to have differed in several major respects from that of *Egertonodus*

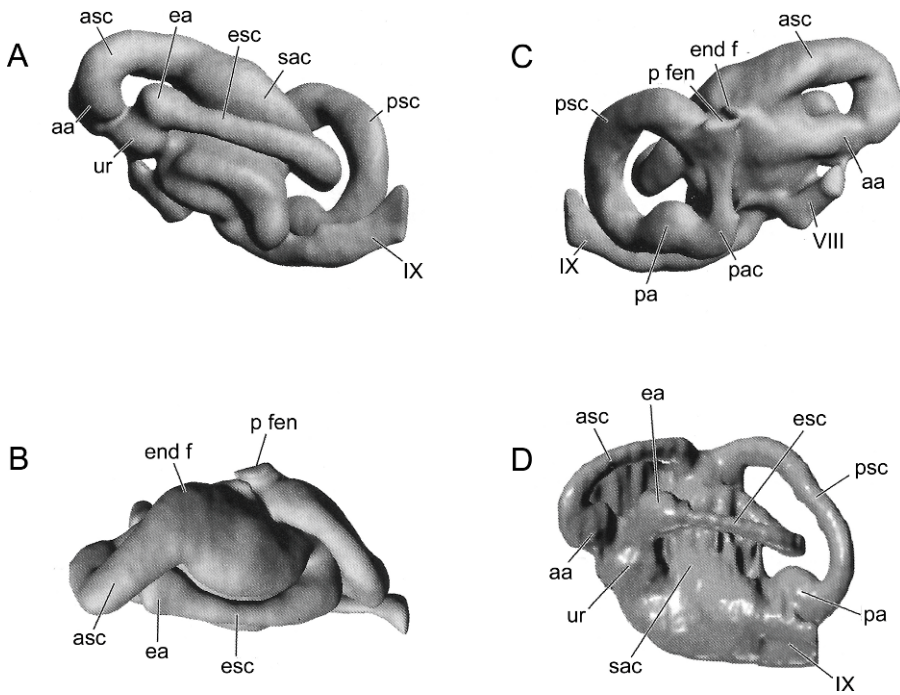


Fig. 37. Skeletal labyrinth structure in other elasmobranchs. A–C, extant *Notorynchus*, A, lateral; B, dorsal; C, medial views; D, *Cladodoides*, lateral view. After Maisey, 2005. No scale.

*basanus* (Maisey, 1983), the only other hyodont whose cranial anatomy is known in comparable detail.

**EXTANT ELASMOBRANCHS:** In most extant elasmobranchs, the cranial circulation follows what is probably a highly conserved pattern, in which the dorsal aorta divides into left and right branches (= lateral dorsal aortae), each of which gives off an efferent hyoidean artery posteriorly, and an orbital artery more anteriorly, before anastomosing to form a single internal carotid artery. This artery generally enters the braincase either after or just prior to anastomosing, producing either a single median internal carotid foramen (e.g., *Raja*: Allis, 1912; *Heterodontus*: Maisey, 1983; Shirai, 1992; *Squalus*: Ashley and Chiasson, 1988; *Squatina*; *Pristiophorus*; batoids: *Rhynchobatus*; hexanchoids: *Hexanchus*; many squaloids; Shirai, 1992) or a pair of foramina (e.g., *Chlamydoselachus*, Allis, 1911, 1923; many squaloids; galeomorphs: *Proscyllium*; Shirai, 1992; Compagno, 1988). As the above-listed taxa show, this feature (presence of one vs. two internal carotid foramina) is highly

variable in extant neoselachians, and does not appear at present to have much taxonomic significance. Soon after anastomosing and entering the braincase, the internal carotid artery again divides into left and right branches. Each of these gives off a lateral branch (which divides to produce the efferent pseudobranchial and ophthalmic arteries), and an anterior branch, which gives rise to the optic and cerebral arteries. In neoselachians, the posterior part of the basicranial arterial system forms what has been referred to as a “bell-shaped” circuit (Schaeffer, 1981), due to the outwardly/laterally curving position of the lateral dorsal aortae, which form the concave “base” of the “bell,” while the V-shaped proximal area where the lateral dorsal aortae merge posteromedially as the median dorsal aorta forms the bell’s “clapper.”

This bell-shaped area is mainly external to the braincase in neoselachians, particularly in its posterior part. However, Allis (1911) describes the efferent hyoidean artery of *Chlamydoselachus* as passing briefly through a short canal in the cranial cartilage before



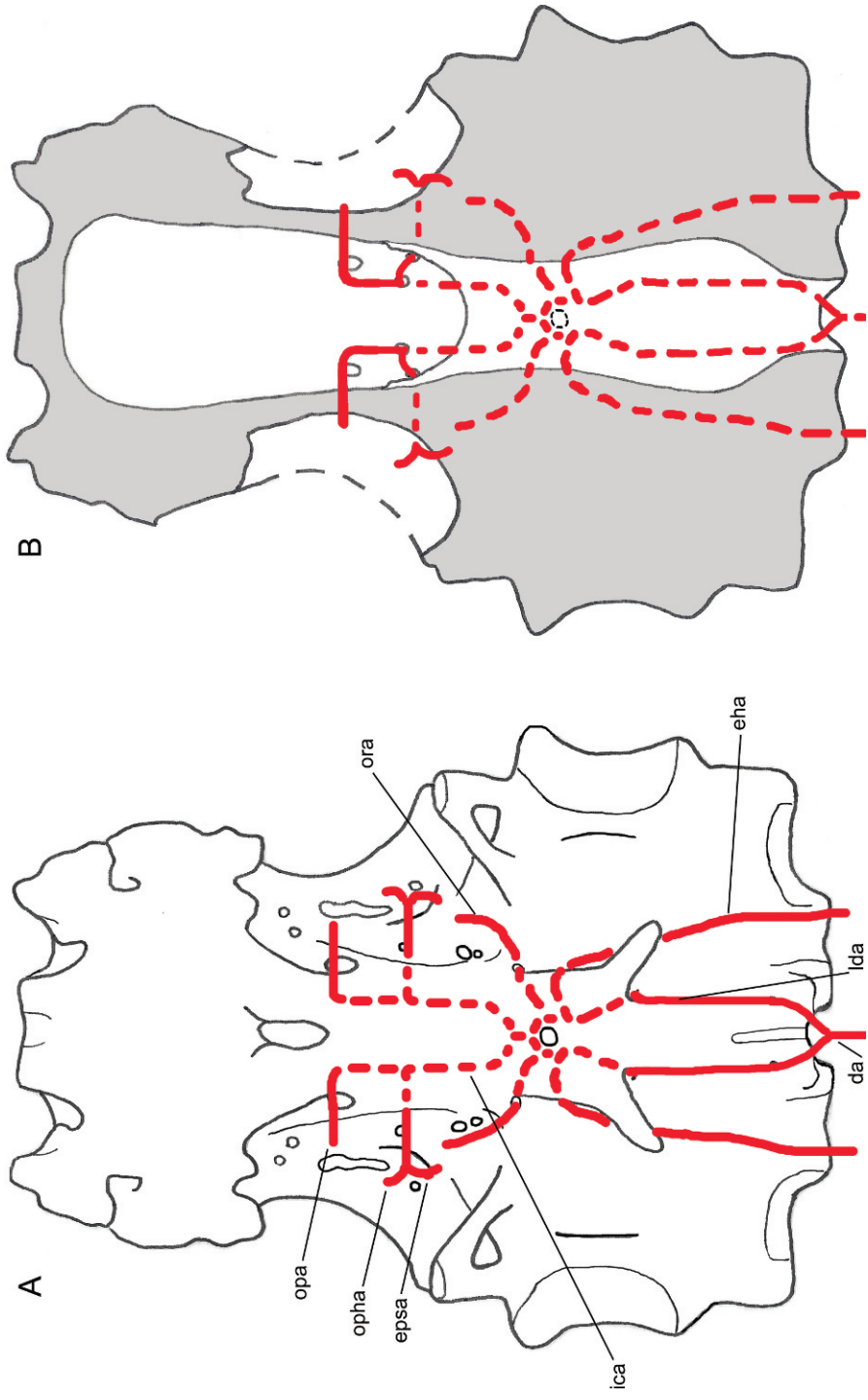


Fig. 38. Reconstructions of the basicranial circulation in *Tribodus lima*. **A**, ventral (external) view of the braincase showing the basicranial arterial circuit; solid lines represent vessels visible on the surface or external to the cartilage, and dashed lines represent those internal to the cartilage or endocranial space; **B**, dorsal cutaway (interior) view of the floor of the cranial cavity, showing the same vessels as seen from above; note the internal carotid arteries emerging from the basicranial cartilage through paired foramina in the floor of the braincase anterior to the dorsum sellae, and then diverging to form the optic artery anteriorly and the efferent pseudobranchial/ophthalmic artery posteriorly (the latter divides after exiting the braincase). Solid lines represent vessels visible on the surface of the cutaway (on the floor of the cranial cavity), and dashed lines represent vessels internal to the cartilage or ventral to the basicranium (compare with A). No scale.

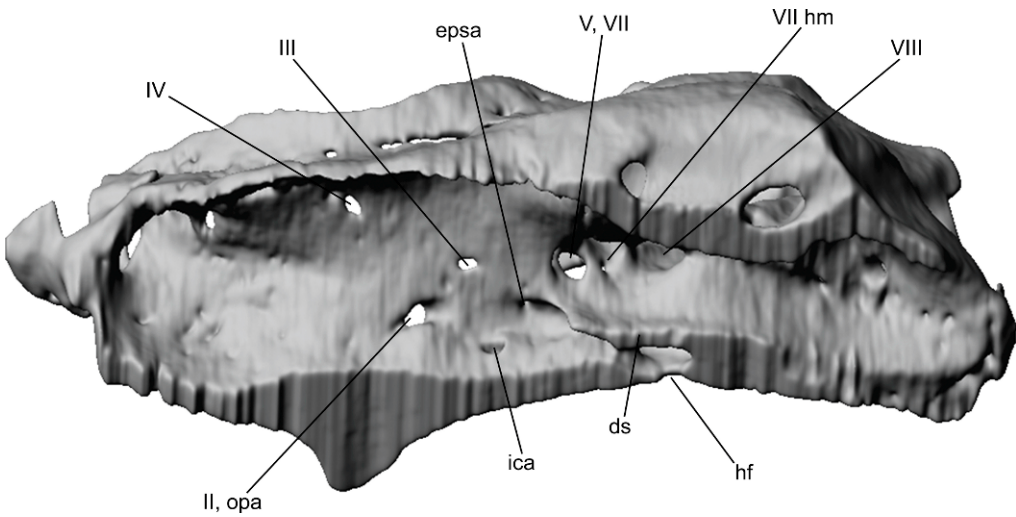


Fig. 39. Oblique medial view of the *Tribodus* braincase showing the foramina for the efferent pseudobranchial and ophthalmic arteries. The internal carotid arteries emerge on the internal floor of the braincase after tunneling through the basicranial cartilage, and diverge to form a posterolaterally curving branch, which further diverges into the efferent pseudobranchial and ophthalmic arteries external to the cartilage, and an anterolaterally curving branch, the optic artery, which exits through the optic foramen. Compare with figure 38. No scale.

emerging again to join the lateral dorsal aorta. More anteriorly, the orbital artery can be external to the braincase (e.g., *Chlamydoselachus*, Allis, 1923), or can pass through the cranial cartilage, as in *Heterodontus* (Maisey, 1983). Compagno (1988: fig. 6.8) illustrates several extant galeomorphs in which the efferent hyoidean and orbital (stapedial) arteries meet the lateral dorsal aortae within the basicranial cartilage, anterior to the point where the lateral dorsal aortae enter the braincase (i.e., hemigaleine hemigaleids; *Hemipristis*). Anterior to the entry of the internal carotids into the braincase, the efferent pseudobranchial and ophthalmic arteries typically exit the braincase through a single foramen, and diverge afterward (Allis, 1911, 1912, 1923; Holmgren, 1942: fig. 18). The optic artery typically exits the braincase farther anteriorly, alongside the optic nerve.

**FOSSIL CHONDRICHTHYANS:** In fossil sharks, the pattern of cranial vascularization has been reconstructed based on the arrangement of basicranial foramina (and, where present, external grooves on the surface of the braincase) (e.g., *Orthacanthus*, *Cladoselache*, Schaeffer, 1981; *Cladodoides*, *Tamiobatis*, Maisey, 2005; “*Cobelodus*,” Maisey, 2007). The pattern in

these fossil forms is broadly similar to that of extant neoselachians in having a posterior circuit formed from the lateral dorsal aortae and internal carotids, and in the positions of the efferent hyoidean and orbital arteries relative to this circuit. In general, the basicranial circuit in fossil chondrichthyans is narrower and more elongate than it is in neoselachians, and lacks the bell-shaped curve posteriorly. In many forms (e.g., *Orthacanthus*, *Cladoselache*, *Tamiobatis*, *Cladodoides*; Schaeffer, 1981; Maisey, 2005, 2007), the lateral dorsal aortae enter the basicranial cartilage posteroventrally through paired foramina and travel anteriorly through enclosed canals. In others (e.g., “*Cobelodus*”; Maisey, 2007), the dorsal aorta enters the braincase through a single posteroventral foramen and divides within the cartilage, but the lateral dorsal aortae also travel anteriorly through enclosed canals. This is notably different from the pattern in hybodonts and many neoselachians, in which the posterior part of the lateral dorsal aortae and arterial circuit are external to the cartilage. Also, the part of the arterial loop posterior to the efferent hyoidean artery is longer in xenacanth and “ctenacanth” than in other chondrichthyans, a feature that is probably related to the elongated otico-occipital

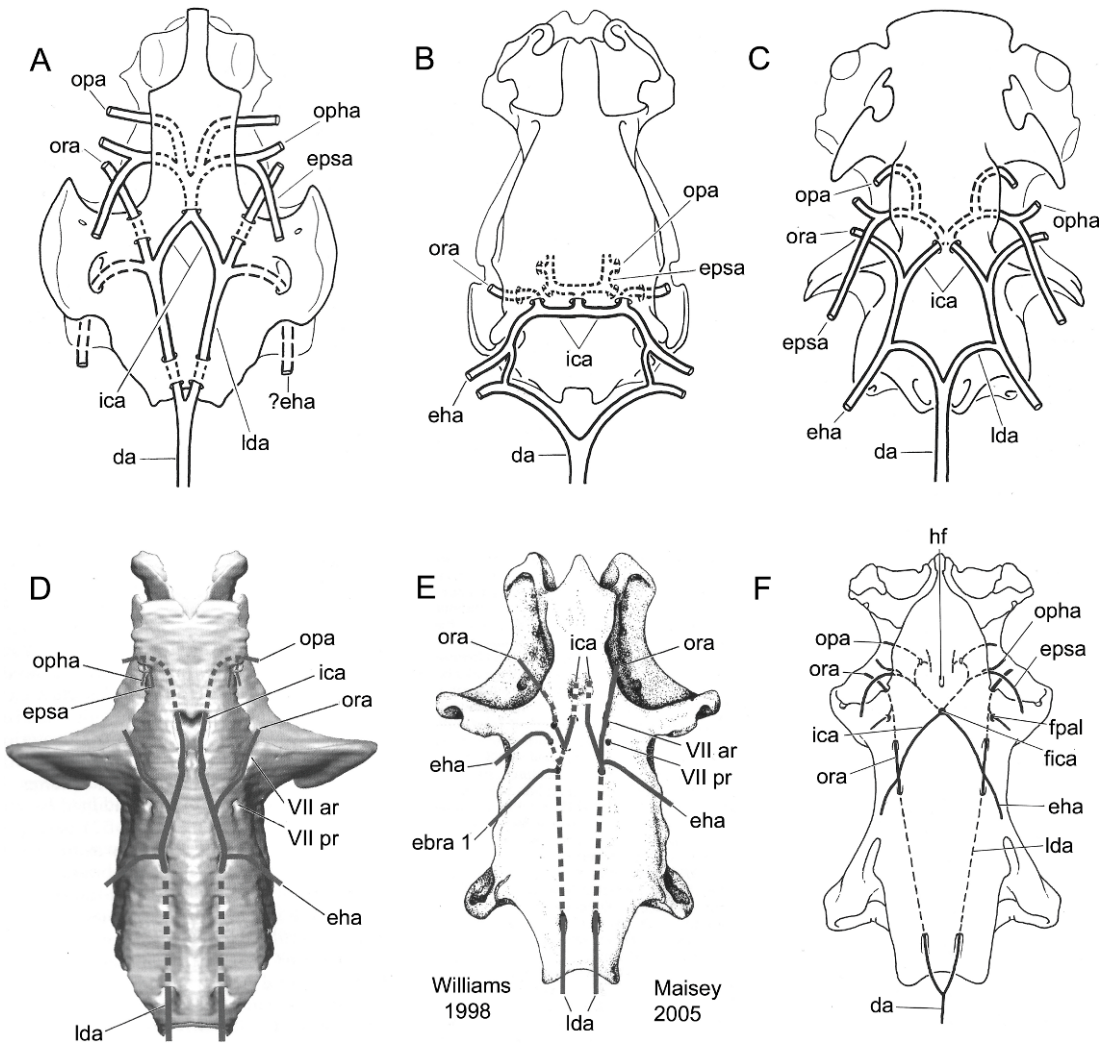


Fig. 40. Basicranial circulation in other elasmobranchs. **A**, *Egertonodus (Hybodus) basanus*, after Maisey, 1983; **B**, extant *Heterodontus*, after Maisey, 1983; **C**, extant *Chlamydoselachus*, after Allis, 1923 (reproduction from Maisey, 1983: fig. 25; positions of “ora” and “opha” changed from original figure to reflect their correct positions); **D**, *Cladodoides*, after Maisey, 2005; **E**, *Tamiobatis*, after Maisey, 2005 (left side: interpretation of Williams, 1998; right side: interpretation of Maisey, 2005); **F**, *Orthacanthus*, after Schaeffer, 1981. No scale.

regions of these taxa. Another noticeable difference between many fossil and extant chondrichthyans is the anterior extent of the arterial system: in fossil forms including hybodonts and Paleozoic sharks, the cranial arterial system (from lateral dorsal aortae to optic arteries; based on the positions of foramina) appears to have extended nearly the entire length of the braincase, whereas in extant elasmobranchs (e.g., *Heterodontus*, *Chlamydoselachus*; Maisey,

1983) it extends anteriorly only about two-thirds the length of the braincase. This may also be related to the general shift in braincase proportions in neoselachians, with the otico-occipital regions shortening and the orbital and ethmoidal regions forming a larger proportion of overall braincase length. In many fossil sharks, the orbital and efferent hyoidean arteries have been reconstructed branching from the lateral dorsal aorta in very close proximity (*Tamiobatis*, *Ortha-*

*canthus*, *Egertonodus*, *Cladoselache*, “*Cobelodus*”; Schaeffer, 1981; Maisey, 1983, 2005, 2007), whereas in *Cladodoides*, *Tribodus*, and neoselachians there is apparently some distance between their branch points (Maisey, 1983, 2005; and the present paper). However, many of these observations rely on the accuracy of previous reconstructions, which necessarily involve at least some degree of speculation.

**TRIBODUS:** Based on CT scans and digital images of the braincase of *Tribodus* (AMNH 13958), its cranial circulation can be reconstructed according to several possible scenarios, described below. In all of these, it is considered likely that the optic artery passed through the optic foramen together with the optic nerve, as in *Cladodoides* and extant neoselachians (Maisey, 2005). It is also considered probable that the efferent pseudobranchial and ophthalmic arteries divided external to the cranial wall, as in many neoselachians and as Maisey (1983) reconstructed in *Egertonodus* (and confirmed in *Egertonodus* by CT scan images in the present study). The efferent pseudobranchial arteries are here interpreted as having passed through paired canals in the basicranial cartilage (visible in CT scan images), which emerge into the cranial cavity just anterior to the dorsum sellae. They then would have curved posterolaterally and slightly dorsally, to exit the cranial wall through a small foramen in the lateral wall of the orbit immediately anterior and ventral to the lateral hypophyseal ridge, before diverging into separate efferent pseudobranchial and ophthalmic arteries external to the braincase.

The remaining aspects of the cranial circulation are more problematic, due to the presence of several foramina not found in other fossil or extant elasmobranchs whose significance is difficult to interpret. However, the likelihood of each morphological scenario can be weighed according to a number of ontogenetic and phylogenetic considerations, allowing the most likely configuration of cranial vascularization to be identified.

On the basicranium there is a single median foramen located between the paired postorbital processes. This might normally be considered a foramen for the internal carotid arteries, as in some extant neoselachians (e.g., *Heterodontus*) in which the internal carotids

meet external to the basicranial cartilage and enter the cartilage as a single vessel. This interpretation has also been suggested for *Egertonodus* (Maisey, 1983). However, unlike *Egertonodus*, *Tribodus* lacks any obvious indentations on the basicranium that could be interpreted as external arterial pathways. Also, *Tribodus* has several additional foramina in the basicranium that require explanation, casting doubt on the interpretation of the median foramen as an internal carotid opening. These include a pair of posterior foramina (located on the undersides of the paired posterior basicranial processes) and two pairs of lateral foramina (immediately lateral to the median foramen). CT scans show that all of these foramina are interconnected by internal canals. The posterior foramina lead to paired canals which continue anteromedially, converging to open into a large chamber overlying the median basicranial foramen, and continuous with it. This chamber is also continuous with the two pairs of lateral foramina, which open ventromedial to the postorbital processes. This configuration indicates that the structures contained within these foramina may have been continuous with one another, and suggest a system of branched arteries.

In most extant elasmobranchs, the basicranial circulation forms a loop or circuit posteriorly. The dorsal aorta divides into paired lateral dorsal aortae, which diverge to form the posterior part of the loop. They meet the paired posterolaterally directed efferent hyoidean arteries slightly farther anteriorly, continue forward as the common carotid arteries, and meet with the paired anterolaterally directed orbital arteries before turning medially as the internal carotid arteries to converge and enter the basicranial cartilage (whether the internal carotids meet immediately prior to, or after, entering the braincase is variable in many extant elasmobranchs). Indentations on the basicranium in *Egertonodus* strongly suggest a similar configuration, as proposed by Maisey (1983). Moreover, most fossil chondrichthyans currently known exhibit a more or less similar pattern (e.g., *Orthacanthus*, *Tamiobatis*, Schaeffer, 1981; *Cladodoides*, Maisey, 2005; “*Cobelodus*,” Maisey, 2007), with a comparable circuit and arterial arrangement (the main differences being in the



shape of the circuit—bell shaped in neoselachians vs. more narrow and elongated in other elasmobranchs—and whether the circuit is entirely external or partly contained in cartilage, which varies greatly even among extant neoselachians; e.g., Compagno, 1988). Thus, the general pattern of basicranial circulation in elasmobranchs appears to be highly conserved, and it would seem most likely that *Tribodus* would conform to that paradigm, at least in terms of overall structure.

The internal carotid arteries extend forward within the basicranial cartilage beginning immediately anterior to the median foramen, and would have to enter the braincase somewhere posteriorly, either through the median foramen or through the foramina anterodorsal to the paired basicranial processes. The orbital arteries and efferent hyoidean arteries must also be accounted for.

In the first possible scenario of cranial circulation in *Tribodus*, the median basicranial foramen is interpreted as the internal carotid foramen (as in many extant neoselachians and *Egertonodus* as interpreted by Maisey, 1983), located where the internal carotid arteries converge to enter the braincase. Before entering the braincase, the internal carotid arteries diverge from a single median dorsal aorta posteriorly, which then divides into paired lateral dorsal aortae prior to anastomosing immediately external to the internal carotid foramen. According to this scenario, paired canals diverging posteriorly from the chamber above the internal carotid foramen are then explained as containing the efferent hyoidean arteries, the first pair of vessels to branch from the (now merged) internal carotid artery after its entry into the braincase. These canals emerge externally at the foramina above the paired basicranial processes. Immediately anterior to the junction with the efferent hyoidean arteries, the pair of canals originating in the space above the internal carotid foramen and exiting the braincase anterolaterally are then interpreted as having contained the orbital arteries. However, the posterolateral pair of foramina are then left without explanation. Anterior to the origin of the orbital arteries, the internal carotid artery would have again divided before continuing anteriorly as paired arteries tunneling through

the basicranial cartilage beneath the hypophyseal chamber, which emerge on the floor of the cranial cavity to meet the efferent pseudobranchial/ophthalmic arteries, and the optic arteries farther anteriorly.

After entering the cranial cavity and giving rise to the efferent pseudobranchial and ophthalmic arteries, the paired internal carotid arteries again continue anteriorly, diverging one more time to produce first the optic arteries, which curved laterally and exited the braincase through the optic foramen alongside the optic nerve, and finally the cerebral artery, which curved dorsally to supply the brain. The difficulty with accepting this scenario is that the efferent hyoidean and orbital arteries in chondrichthyans do not typically meet the internal carotids after they merge and enter the braincase, and such a pattern is unknown in any other fossil or extant elasmobranch. Also, the posterolateral foramina in the hypophyseal region remain unexplained. Additionally, there are no observable indentations on the external surface of the basicranium that could be consistent with the path of the internal carotids entering the median ventral foramen, although this does not necessarily mean they were not present.

In the second scenario of cranial arterial circulation, the paired posterior canals converging above the paired ventral processes are interpreted as containing the lateral dorsal aortae. After entering the braincase, the lateral dorsal aortae continue forward anteromedially and enter the median basicranial chamber above the hypophyseal foramen, giving rise first to the efferent hyoidean arteries (posteriorly) and then the orbital arteries (anteriorly) before turning mesially and anastomosing above the median ventral foramen (the “internal carotid” foramen of the previously described scenario). The efferent hyoidean arteries then curve outward posterolaterally, exiting the braincase and passing along the posterolaterally directed grooves anterolateral to the paired ventral processes on their way to the hyoid arch. The orbital arteries exit the braincase through the paired foramina anterolateral to the median ventral foramen, as in the previous interpretation, and turn outward anterolaterally to enter the orbit. After anastomosing, the internal carotid ar-

teries again diverge anteriorly, meeting the efferent pseudobranchial/ophthalmic, optic, and cerebral arteries as in the previous scenario. Because in this second scenario the internal carotid arteries enter the braincase through the paired posterior foramina, the medial basicranial foramen is left without explanation. Two possible interpretations are: (1) this foramen represents a hypophyseal duct that remained open externally; (2) the specimen is a juvenile in which the embryonic hypophyseal fenestra has not yet closed. Because other features of the braincase suggest that the specimen more likely represents an adult, the explanation that an open hypophyseal duct was present in *Tribodus* seems on the surface more likely. This interpretation is supported by the presence of a narrow internal canal (visible in CT scans) connecting the main hypophyseal chamber with the more posteroventral space beneath the dorsum sellae that opens ventrally through the median ventral foramen.

Nevertheless, each of the above-described scenarios is problematic. In scenario (1), although the internal carotid arteries enter the braincase through a central foramen as previously hypothesized in other hybodonts (i.e., *Egertonodus*, Maisey, 1983), the efferent hyoidean and orbital arteries join the internal carotid artery only after it anastomoses and enters the braincase, a key difference from most extant neoselachians and fossil chondrichthyans. Also, the pair of posterolateral foramina remain unexplained. In scenario (2), an open hypophyseal foramen is considered to have been present (unlike adult extant neoselachians). However, although the efferent hyoidean and orbital arteries join the lateral dorsal aortae after the latter structures enter the braincase (unlike most neoselachians), they do so posterior to the anastomosis of the internal carotids (as in most elasmobranchs). Therefore, the second scenario of cranial circulation in *Tribodus* is accepted here as the more plausible of the two.

*EGERTONODUS*: Digital reconstructions of the braincase of *Egertonodus basanus* made from CT scan slices as part of the present paper confirm Maisey's (1983: fig. 25) reconstruction of its basicranial circulation. These images show that the internal carotid arteries

in *Egertonodus* most likely entered the braincase through the median basicranial foramen (Maisey, 1983: fig. 9b; this paper, fig. 40A), converging into a single vessel just prior to entering the braincase. They then diverged anteriorly into left and right branches. These branches then diverged again a few millimeters anterior to the internal carotid foramen, producing a laterally directed branch (the combined ophthalmic/efferent pseudobranchial artery, which exited the braincase via a common foramen, and then presumably diverged as in extant neoselachians), and an anterior branch (giving rise to the optic artery, which exited the braincase via the optic foramen alongside the optic nerve).

#### PROBABLE EXTENT OF EMBRYONIC CARTILAGE IN *TRIBODUS* AND *EGERTONODUS*

A reconstruction of the embryonic cartilage in *Tribodus* and *Egertonodus* is presented in figure 41, on the basis of morphological landmarks described by Holmgren (1940) and Maisey (2005, 2007). The positions of the efferent pseudobranchial artery and pituitary vein foramina have been considered of developmental significance, in marking the anterior and posterior extent of the embryonic polar cartilage, respectively (Maisey, 2007). These foramina are usually situated in the posterior of the orbit, in the region between the optic nerve foramen and the postorbital process. In neoselachians, the efferent pseudobranchial foramen is nearly always anterior to that of the pituitary vein (however, in embryos of the batoid *Torpedo ocellata* the two vessels briefly share a single foramen; Holmgren, 1940: 204–227, fig. 162; and in *Torpedo* the embryonic polar cartilage is limited to a relatively narrow strip and never contacts the parachordals; Holmgren, 1940). The efferent pseudobranchial foramen is also typically located posterior to the optic and oculomotor foramina, at the same level as the optic foramen and ventral to the oculomotor foramen.

The general position of the efferent pseudobranchial foramen in *Tribodus* and *Egertonodus* is similar to that of neoselachians, with some variation between the two taxa (i.e., in *Tribodus* the efferent pseudobranchial foramen is on a level with the optic foramen,

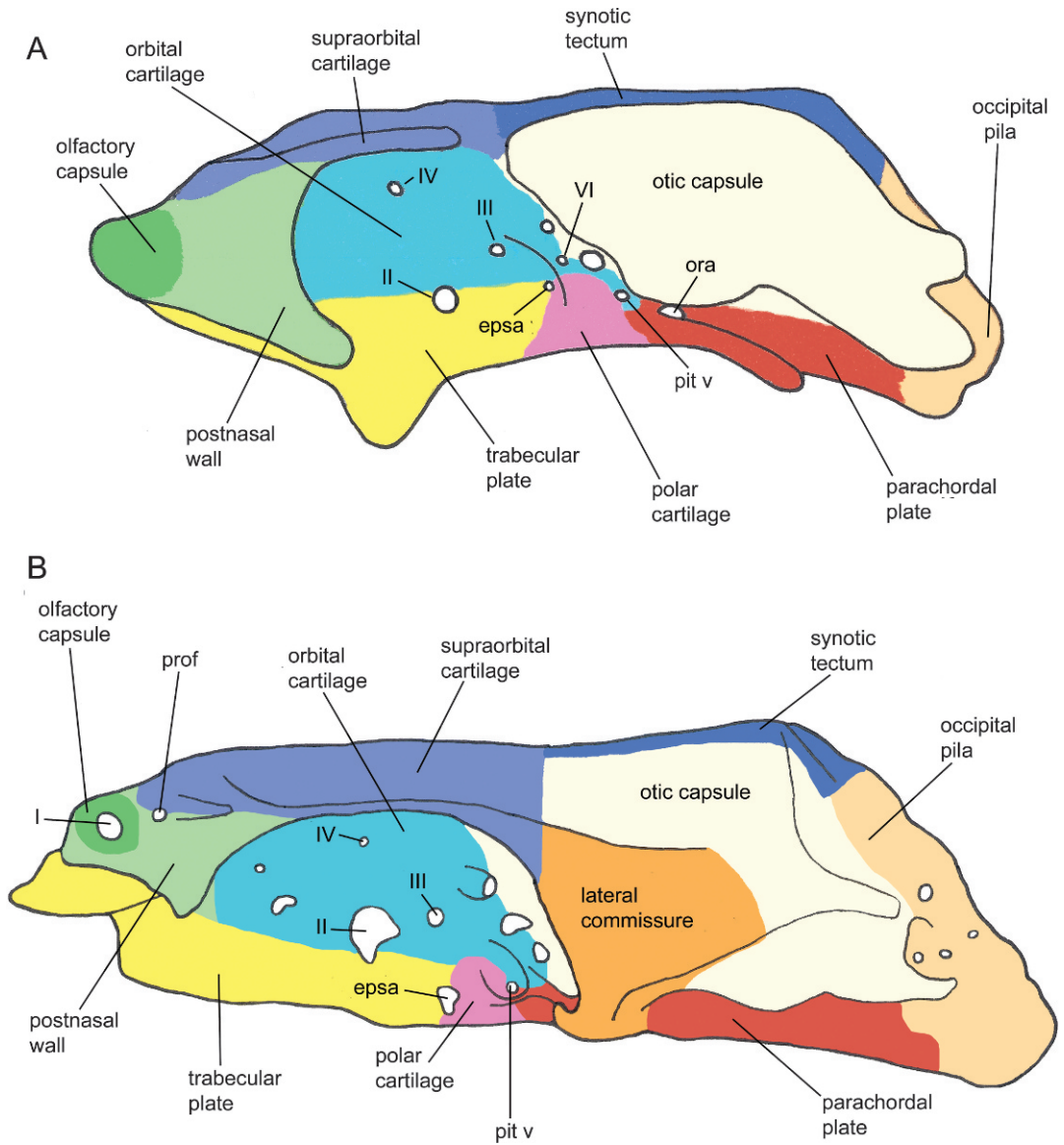


Fig. 41. **A**, Composite reconstruction showing probable extent of embryonic cartilages in *Tribodus limae*; the postorbital process, otic capsule, and antorbital process have been cut away to show the foramina. **B**, Reconstruction showing probable extent of embryonic cartilages in *Egertonodus basanus*. Color scheme based on Maisey (2005), for easier comparison with his reconstructions of the embryonic cartilages in other elasmobranchs. No scale.

whereas in *Egertonodus* it is ventral to the optic foramen). Externally, the efferent pseudobranchial foramen in neoselachians is often located ventrally within an ovoid depression on the lateral surface of the braincase, interpreted as corresponding to the “trigeminopituitary fossa” (De Beer, 1937; Allis,

1914). This is also the case in *Tribodus*, in which the efferent pseudobranchial artery (but not the pituitary vein) is located within the external trigeminofacialis fossa. In *Egertonodus*, the efferent pseudobranchial foramen is located slightly anterior to the main trigeminofacialis fossa. Although an opening

for the pituitary vein in *Egertonodus* was not found previously (Maisey, 1983), digital reconstructions indicate that its pituitary vein was located within the trigeminofacialis recess, somewhat above and posterior to the efferent pseudobranchial foramen and slightly anterior to the internal carotid foramen. This indicates that the polar cartilage in *Egertonodus* probably had a somewhat limited anteroposterior extent. In contrast, the pituitary vein in *Tribodus* is more posteriorly located, medial to the postorbital process on a level with the anterior part of the otic region. The hypophyseal foramen is located even farther posteriorly, indicating that the polar cartilage (which typically surrounds the hypophyseal foramen) was probably more extensive in *Tribodus* than in *Egertonodus*. In extant neoselachians, the dorsal margin of the polar cartilage is usually indicated by the position of the optic pedicel. Because this structure is absent in *Tribodus* and *Egertonodus*, the dorsal extent of the polar cartilage is estimated here based on the approximate location of the optic pedicel, if one were present.

The parachordal plate generally forms the basicranial floor, from the back of the dorsum sellae posteriorly to the occipital arch. It appears to have been less extensive in *Tribodus* than in *Egertonodus*, based on the more posterior position of the hypophyseal foramen and dorsum sellae in *Tribodus*. Anteriorly, the trabecular cartilage generally extends forward from the efferent pseudobranchial foramen, and its dorsal margin is delimited by the optic foramen. The trabeculae extend anteriorly to the rostrum, along the medioventral portion of the braincase. In *Tribodus* and *Egertonodus*, the trabeculae probably formed the median basicranial process and caudal internasal keel, respectively, as well as the rostral bar. The trabeculae probably also contributed to the ethmopalatine processes in *Egertonodus*. The dorsal part of the orbit (between the optic foramen and superficial ophthalmic foramina) is typically formed by the orbital cartilage in extant elasmobranchs (El-Toubi, 1949). It contains the trochlear and oculomotor foramina, and its posterior margin is formed by the trigeminofacial foramina (marking the position of the embryonic incisura prooticum). Dorsal to this,

the supraorbital crest (lateral to the dorsal row of superficial ophthalmic foramina) is formed by the supraorbital cartilage in *Squalus* (El-Toubi, 1949). The anterior roof of the braincase is usually formed by that cartilage and by the orbital cartilage (El-Toubi, 1949). The lamina orbitonasalis (lateral to the trabeculae) forms the anterolateral wall of the braincase lateral to the orbitonasal canal, including the antorbital or ectethmoid process (El-Toubi, 1949; De Beer, 1937). The latter is much more extensive in *Tribodus* than in *Egertonodus*, curving downward and posteriorly in the former to encircle most of the anterior portion of the orbit and forming an anteroventral attachment point for the pre-orbitalis muscle. The olfactory capsule forms as a separate, independent cartilage, which typically chondrifies fairly late in ontogeny (El-Toubi, 1949). Its presence in the *Tribodus* braincase adds support to the conclusion that this specimen represents a mature individual.

Much of the posterolateral part of the braincase is formed by the otic capsule, which contains the skeletal labyrinth including the semicircular canals. It extends from the level of the anterior ampulla posteriorly to the lateral otic process, and includes the dorsolateral margin of the glossopharyngeal foramen. Medial to this is the parietal fossa, whose anterior margin is formed by the synotic tectum. The taenia medialis, which forms the floor of the parietal fossa, can be formed in extant elasmobranchs by either a posterior extension of the synotic tectum, or an anterior extension of the posterior tectum, where one is present (Holmgren, 1940). Whether a posterior tectum was present in hybodonts is difficult to determine. The posteriormost part of the braincase, including the occipital cotylus, was formed by the occipital arch (a derivative of the embryonic hyoid somite, together with the parachordals; Holmgren, 1940). Both *Tribodus* and *Egertonodus* have postorbital processes probably formed at least in part by a chondrified embryonic lateral commissure (as discussed above). This inference is based on the presence of a jugular foramen contained within the postorbital process in both of these forms, as well as on the pronounced ventral extent of their postorbital processes. The contribution of the lateral commissure was probably greater in



*Egertonodus*, in which the ventral margin of the postorbital process merges with the basicranium (as in other known hybodonts, *Tristychius*, and many Paleozoic sharks). As discussed by Maisey (2008), the embryonic lateral commissure is most pronounced in Paleozoic chondrichthyans in which a postorbital articulation is present. Its contribution is significantly less in extant neoselachians (in which a postorbital articulation is generally absent except among hexanchiforms, i.e., *Notorynchus*). The lateral commissure of *Tribodus* is not shown in fig. 41A (because the postorbital process and otic capsule are cut away to show the posterior of the orbit), but probably contributed to the ventrolateral portion of the postorbital process.

#### FORMATION OF THE MEDIAL CAPSULAR WALL IN HYBODONTS AND NEOSELACHIANS

*Tribodus* is similar to *Egertonodus* and neoselachians in several aspects of its endocranial and skeletal labyrinth morphology, some of which have been addressed previously (Maisey and Carvalho, 1997; Maisey, 2004a, 2005, 2007). One of the most striking similarities is the presence of a medial capsular wall separating the skeletal labyrinth from the rest of the endocranial cavity. This structure is absent in Paleozoic chondrichthyans including *Cladodoidea* and *Cobelodus* (Maisey, 2005, 2007), as well as in chimaeroids and osteichthyans (e.g., *Mimia*: Gardiner, 1984; Maisey, 2005), and may represent a synapomorphy of hybodonts and neoselachians (although a medial capsular wall is also present in placoderms). In embryonic neoselachians, the anterior part of the medial capsular wall (anterior to the glossopharyngeal nerve) is formed primarily by a dorsal outgrowth of the basicapsular lamina, the “processus dorsalis” of De Beer (1937). Holmgren (1940) describes this process in 25 mm *Etmopterus*. The basicapsular lamina is in turn connected ventrally to the lateral margin of the parachordals, and laterally to the anterior rudiment of the otic capsule (Holmgren, 1940). Posterior to the glossopharyngeal nerve is the posterior part of the basicapsular lamina, and the posterior rudiment of the auditory capsule. Later in development (30 mm *Etmopterus*), a lamella from the anterolateral wall of the otic capsule extends

downward medially, contributing to the anterior part of the medial capsular wall, and caudad to join the processus dorsalis. This cartilage and the dorsal process fuse to form the foramen for the octaval nerve. Posterior to the glossopharyngeal nerve, the medial capsular wall is formed by the cartilage of the posterior semicircular canal (“cartilage of Källberg”; Holmgren, 1940), which grows downward to fuse with the parachordals ventrally. The occipital column rises anterodorsally, and together with the parachordal forms a foramen for the vagus nerve. This nerve marks the boundary between the cartilage of Källberg and the occipital column (Holmgren, 1940). In *Scyliorhinus*, the part of the medial capsular wall forms much as in *Etmopterus*, but with some developmental differences (e.g., in *Scyliorhinus* the cartilage of Källberg has a much lesser extent; Holmgren, 1940). In *Torpedo* and other rays (Holmgren, 1940), the cartilage of Källberg is apparently lacking, and an anterior and posterior processus dorsalis form the medial capsular wall anterior to the vagus nerve. Comparison of these representatives of extant rays, galeomorphs, and squalians indicates that certain aspects of medial capsular wall formation are conserved among these groups (e.g., presence of a dorsal process anterior to the glossopharyngeal nerve; presence of a vagus foramen at the boundary between the occipital column and cartilage of Källberg [or posterior dorsal process in rays]). This suggests that similar embryonic structures and processes may also have been present in hybodonts, including *Tribodus* and *Egertonodus*. It also indicates an absence of these developmental (and related genetic) pathways in Paleozoic chondrichthyans, holocephalans, and other outgroups (with the possible exception of placoderms).

#### GENERAL COMPARISON OF *TRIBODUS* WITH *EGERTONODUS* AND OTHER ELASMOBRANCHS

Maisey (2004a, 2005) noted a number of additional similarities of the otic region between *Tribodus*, *Egertonodus*, and neoselachians (isolation of the posterior semicircular canal and its pre-ampullary extension to form a nearly complete circuit; absence of a crus commune and sinus superior; presence of perilymphatic fenestrae; out-of-plane orientation of the exter-

nal canal; complete parietal fossa in the cranial roof; complete closure of the otico-occipital fissure dorsally; complete closure of the embryonic metotic fissure ventrally; presence of a lateral otic process; anterior ampulla positioned between or in front of postorbital processes; occipital block wedged between otic capsules posteriorly; saccular floor in the same plane as cranial cavity). All of these features are confirmed by the present study. Maisey (2004a) also noted features that could not be detected in these fossil hybodonts because they involve soft anatomical structures (e.g., elaboration and enlargement of the crista neglecta; separation of utricular and saccular regions). Hybodontiforms and neoselachians differ from many Paleozoic chondrichthyans in that the latter have paired posterior foramina for the lateral dorsal aortae located far back on the basicranium near the occiput (e.g., *Tamiobatis*, *Orthacanthus*, *Cladodoides*; Schaeffer, 1981; Maisey, 2005). Presence of these structures may represent a synapomorphy uniting these and similar taxa as a group; or may alternatively represent a primitive condition of chondrichthyans.

Cranial features shared by *Tribodus* and *Egertonodus* (which may represent hybodont synapomorphies) include: presence of separate foramina for the anterior and posterior rami of the octaval nerve; trochlear foramen anterior to optic foramen (noted by Maisey, 2004a); presence and arrangement of three foramina for the trigeminofacial-anterodorsal lateral line complex (superficial ophthalmic complex, trigeminal-anterodorsal lateral line complex, and hyomandibular ramus of the facial nerve); presence of cephalic spines in males (e.g., Brito and Ferreira, 1989; Antunes et al., 1990; Brito, 1992; Maisey, 1982, 1983, 1987, 1989; Maisey and Carvalho, 1997); shared glossopharyngeal-vagus foramina (previously noted by Maisey, 2004a); absence of an optic pedicel. The Carboniferous “hybodontiform” *Tristychius* shares some features with *Tribodus* and *Egertonodus*, but lacks others: like hybodonts and neoselachians, in *Tristychius* the embryonic otico-occipital, ventral, and metotic fissures are closed in the adult, and posterior ventral foramina for the lateral dorsal aortae are lacking. As in hybodonts, there is no evidence of an optic pedicel, and according to Dick (1978) the

trochlear nerve foramen may have been located anterior to the optic nerve. However, unlike hybodonts, there is no evidence of cephalic spines in *Tristychius*; its glossopharyngeal and vagus foramina are separate as in neoselachians; and there appears to have been only a single, shared foramen for the trigeminal and facial nerves (Dick, 1978). Whether or not two foramina for the octaval nerve were present in *Tristychius* remains unknown. *Tristychius* also retains several conserved chondrichthyan features, including an elongate otico-occipital region not telescoped between the postorbital processes; a postorbital articulation of the palatoquadrate (although this differs somewhat from the “archaeostylic” articulation found in other Paleozoic sharks, Maisey, 2008); and possibly even a crus commune and sinus superior (Dick, 1978). These details, along with additional postcranial features (e.g., the presence of two nonmedial denticle rows on the posterior of the dorsal fin spines, and the posteriorly concave shape of the spines in cross section, as in “ctenacanth”), support the view that *Tristychius* was basal to the main hybodontiform lineage (either as a basal hybodontiform, or as an outgroup to euselachians, which includes hybodonts and neoselachians).

*Tribodus* is unique in having paired ventral basicranial processes, and also differs from other known hybodonts in lacking the following structures: a suborbital shelf; ethmopalatine processes; a caudal internasal keel; an ethmoidal articulation of the palatoquadrate; postorbital processes that contact the braincase ventrally; and a basicranial arterial circuit mainly external to the cartilage. The postorbital processes of *Tribodus* are very short anteroposteriorly compared to *Egertonodus* and other hybodontoids. *Tribodus* is also unusual in having its median basicranial foramen (hypophyseal foramen) positioned far posteriorly, indicating a similar posterior extension of the polar cartilage, and suggesting a very short parachordal region. *Tribodus* and *Egertonodus* also share numerous primitive chondrichthyan features (e.g., presence of an open hypophyseal duct; presence of an elongated basicranial arterial circuit; postorbital processes formed largely by the lateral

commissure; presence of a precerebral fontanelle; presence of a parietal fossa; jugular vein passes through postorbital process; occipital hemicentrum absent). These features are also present in *Tristychius* and Paleozoic outgroups. Further study, particularly involving CT scanning to examine internal cranial anatomy of *Tristychius* and other outgroups (where possible), is necessary to reveal additional similarities and differences between these forms and crown-group elasmobranchs. A phylogenetic analysis of hybodonts based on the characters here described (as well as postcranial features) is beyond the scope of the present work, but is currently under way (Lane, in prep.).

#### ACKNOWLEDGMENTS

This work was done as part of my doctoral dissertation at the City University of New York and the American Museum of Natural History. I am grateful to many people who helped to make this project a reality. Among them, I thank my advisor, J. Maisey (AMNH), for providing materials for this project and for numerous helpful discussions; and my committee members, R. Carr (Ohio University), V. Schawaroch (AMNH/CUNY), J. Wahlert (AMNH/CUNY), and S. Schaefer (AMNH), for many helpful suggestions. I also thank M. Colbert (University of Texas, Austin) for CT scanning and preliminary image processing of specimens described here. At AMNH, I thank I. Rutzky for help with locating specimens in the collections; J. Kelly for help with fossil preparation; R. Rudolph and E. Griffiths for assistance on SEM; and L. Meeker, for her help with photography and useful advice on preparing figures. I am also very grateful to Z. Johanson, A. Longbottom, and M. Richter for allowing access to fossil material at NHM in London, and for providing specimen loans. In Brazil, P. Brito (UERJ), A. Kellner (UFRJ/MN), and D. Henriques (MN) kindly provided access to *Tribodus limae* material in their collections, and L. Crivano (UERJ) helped with photography. L. Bergqvist (UFRJ) and M.G.P. de Carvalho assisted with travel arrangements. R. Cuffey (Pennsylvania State University) provided additional helpful comments and suggestions. I thank R. Carr (Ohio University) and P. Janvier

(MNHN, Paris) for reviewing the manuscript. This research project was supported by an AMNH Graduate Student Fellowship, the AMNH Axelrod Fund, and a Grant-in-Aid of Research from Sigma Xi, the Scientific Research Society. Additional funding was provided by a Graduate Science Fellowship from the City University of New York.

#### REFERENCES

- Allis, E.P. 1911. The pseudobranchial and carotid arteries in *Chlamydoselachus anguineus*. *Anatomischer Anzeiger* 39: 511.
- Allis, E.P. 1912. The branchial, pseudobranchial and carotid arteries in *Raja radiata*. *Anatomischer Anzeiger* 41: 579.
- Allis, E.P. 1914. The pituitary fossa and trigemino-facialis chamber in selachians. *Anatomischer Anzeiger* 46: 225–253.
- Allis, E.P. 1923. The cranial anatomy of *Chlamydoselachus anguineus*. *Acta Zoologica* 4: 123–221.
- Antunes, M.T., J.G. Maisey, M.M. Marques, B. Schaeffer, and K.S. Thomson. 1990. Triassic fishes from the Cassange Depression (R.P. de Angola). *Ciências da Terra (UNL)*, Número Especial: 1–64.
- Ashley, L.M., and R.B. Chiasson. 1988. *Laboratory anatomy of the shark*. 5th ed. New York: McGraw-Hill, 84 pp.
- Basden, A.M., G.C. Young, M. Coates, and A. Ritchie. 2000. The most primitive osteichthyan braincase? *Nature* 403: 185–188.
- Bonaparte, C.L. 1832. *Selachorum tabula analytica*. *Nuovi Annali Scienze Naturali (Bologna)* 1: 195–214.
- Brito, P.M. 1991. Systematic atlas: *Tribodus* Brito and Ferreira, 1989. In J.G. Maisey (editor), *Santana fossils: 108–190. an illustrated atlas*. Neptune City, NJ: T.F.H. Publications.
- Brito, P.M. 1992. Nouvelles données sur l'anatomie et la position systématique de *Tribodus limae* Brito and Ferreira, 1989 (Chondrichthyes, Elasmobranchii) du Crétacé Inférieur de la Chapada do Araripe (N-E Brésil). *Géobios* 14: 143–150.
- Brito, P.M., and P.L.N. Ferreira. 1989. The first hybodont shark, *Tribodus limae* n. g., n. sp., from the Lower Cretaceous of Chapada do Araripe (north-east Brazil). *Anais da Academia Brasileira de Ciências* 61 (1): 53–57.
- Cappetta, H., E. Buffetaut, G. Cuny, and V. Suteethorn. 2006. A new elasmobranch assemblage from the Lower Cretaceous of Thailand. *Palaeontology* 49: 547–555.

- Cavin, L., L. Boudad, S. Duffaud, L. Kabiri, J. Le Lœuff, I. Rouget, and H. Tong. 2001. L'évolution paléoenvironnementale des faunes de poissons du Crétacé supérieur du bassin du Tafilalet et des régions avoisinantes (sud-est du Maroc): implications paléobiogéographiques. *Comptes Rendus de l'Académie des Sciences Series 2 Sciences de la Terre et des Planètes* 333: 677–683.
- Coates, M.I., and S.E. Sequeira. 1998. The braincase of a primitive shark. *Transactions of the Royal Society of Edinburgh Earth Sciences* 89: 63–85.
- Coates, M.I., and S.E.K. Sequeira. 2001. A new stethacanthid chondrichthyan from the Lower Carboniferous of Bearsden, Scotland. *Journal of Vertebrate Paleontology* 21 (3): 438–459.
- Compagno, L.J.V. 1988. *Sharks of the order Carcharhiniformes*. Princeton, NJ: Princeton University Press, 486 pp.
- Cordier, R. 1954. Le système nerveux central et les nerfs cérébro-spinaux. In Grassé, P.-P. (editor), *Traité de zoologie: anatomie, systématique, biologie*. Tome 12. Vertébrés: 202–332. Paris: Masson et Cie, 1145 pp.
- Cuny, G., M. Ouaja, D. Srarff, L. Schmitz, E. Buffetaut, and M.J. Benton. 2004. Fossil sharks from the Early Cretaceous of Tunisia. *Revue de Paleobiologie* 9: 127–142.
- Daniel, J.F. 1934. *The elasmobranch fishes*. 3rd ed. Berkeley: University of California Press, 332 pp.
- De Beer, G.R. 1931. The development of the skull of *Scyllium (Scylliorhinus) canicula*. *Quarterly Journal of Microscopic Science* n. ser. 74: 591–645.
- De Beer, G.R. 1937. *The development of the vertebrate skull*: Oxford University Press, xxiv + 552 pp.
- Dick, J.R.F. 1978. On the Carboniferous shark *Tristychius arcuatus* Agassiz from Scotland. *Transactions of the Royal Society of Edinburgh* 70 (4): 63–109.
- El-Toubi, M.R. 1949. The development of the chondrocranium of the spiny dogfish, *Acanthias vulgaris (Squalus acanthias)*. Part I. Neurocranium, mandibular and hyoid arches. *Journal of Morphology* 84: 227–280.
- Gardiner, B.G. 1984. The relationships of the palaeoniscid fishes, a review based on new specimens of *Mimia* and *Moythomasia* from the Upper Devonian of Western Australia. *Bulletin of the British Museum (Natural History)* 37 (4): 173–428.
- Gaudin, T.J. 1991. A re-examination of elasmobranch monophyly and chondrichthyan phylogeny. *Neues Jahrbuch für Geologie und Paläontologie Abhandlungen* 182: 133–160.
- Gegenbaur, C. 1872. Untersuchungen zur vergleichenden Anatomie der Wirbelthiere. III. Das Kopfskelet der Selachier, ein Beitrag zur Erkenntniss der Genese des Kopfskeletes der Wirbelthiere. Leipzig: Wilhelm Engelmann, 316 pp.
- Ginter, M. 2005. The euselachian type of tooth-bases in Palaeozoic chondrichthyans. In V. Hairapetian and M. Ginter (editors), *Devonian vertebrates of the continental margins*: 11–12, *Ichthyolith Issues Special Publication* 8, Yerevan, Armenia.
- Goodrich, E.S. 1930. *Studies on the structure and development of vertebrates*. London: MacMillan, xxx + 837 pp.
- Holmgren, N. 1940. *Studies on the head in fishes. Part I. Development of the skull in sharks and rays*. *Acta Zoologica (Stockholm)* 21: 51–267.
- Holmgren, N. 1941. *Studies on the head in fishes. Part II. Comparative anatomy of the adult selachian skull, with remarks on the dorsal fins in sharks*. *Acta Zoologica (Stockholm)* 22: 1–100.
- Holmgren, N. 1942. *Studies on the head in fishes. Part III. The phylogeny of elasmobranch fishes*. *Acta Zoologica (Stockholm)* 23: 129–261.
- Huxley, T.H. 1880. On the application of the laws of evolution to the arrangement of the Vertebrata and more particularly of the Mammalia. *Proceedings of the Zoological Society of London* 1880: 649–662.
- Jarvik, E. 1942. On the structure of the snout of crossopterygians and lower gnathostomes in general. *Zoologiska Bidrag från Uppsala* 21: 235–675.
- Jarvik, E. 1980. *Basic structure and evolution of vertebrates*. Vol. 1. London: Academic Press, 575 pp.
- Lane, J.A., and J.G. Maisey. 2009. Pectoral anatomy of *Tribodus limae* (Elasmobranchii: Hybodontiformes) from the Lower Cretaceous of northeastern Brazil. *Journal of Vertebrate Paleontology* 29 (1): 25–38.
- Liem, K.F., W.E. Bemis, W.F. Walker, Jr., and L. Grande (editors). 2001. *Functional anatomy of the vertebrates: an evolutionary perspective*. 3rd ed. New York: Harcourt College Publishers, 703 pp.
- Maisey, J.G. 1980. An evaluation of jaw suspension in sharks. *American Museum Novitates* 2706: 1–17.
- Maisey, J.G. 1982. The anatomy and interrelationships of Mesozoic hybodont sharks. *American Museum Novitates* 2724: 1–48.
- Maisey, J.G. 1983. Cranial anatomy of *Hybodus basanus* Egerton from the Lower Cretaceous of England. *American Museum Novitates* 2758: 1–64.
- Maisey, J.G. 1985. Cranial morphology of the fossil elasmobranch *Synechodus dubrisiensis*. *American Museum Novitates* 2804: 1–28.



- Maisey, J.G. 1986. Anatomical revision of the fossil shark *Hybodus fraasi* (Chondrichthyes: Elasmobranchii). *American Museum Novitates* 2857: 1–16.
- Maisey, J.G. 1987. Cranial anatomy of the Lower Jurassic shark *Hybodus reticulatus* (Chondrichthyes: Elasmobranchii), with comments on hybodontid systematics. *American Museum Novitates* 2878: 1–39.
- Maisey, J.G. 1989. *Hamiltonichthys mapei*, g. and sp. nov. (Chondrichthyes; Elasmobranchii), from the Upper Pennsylvanian of Kansas. *American Museum Novitates* 2931: 1–42.
- Maisey, J.G. 2000. Continental break-up and the distribution of fishes of Western Gondwana during the Early Cretaceous. *Cretaceous Research* 21: 281–314.
- Maisey, J.G. 2001a. Remarks on the inner ear of elasmobranchs and its interpretation from skeletal labyrinth morphology. *Journal of Morphology* 250: 236–264.
- Maisey, J.G. 2001b. A primitive chondrichthyan braincase from the Middle Devonian of Bolivia. In P.E. Ahlberg (editor), *Major events in early vertebrate evolution: palaeontology, phylogeny and development*. London: Taylor and Francis, 263–288.
- Maisey, J.G. 2004a. Endocranial morphology in fossil and recent chondrichthyans. In G. Arratia and R. Cloutier (editors), *Recent advances in the origin and early radiation of vertebrates*: 139–170. Munchen: Verlag Dr. Friedrich Pfeil.
- Maisey, J.G. 2004b. Morphology of the braincase in the broadnose sevengill shark *Notorynchus* (Elasmobranchii: Hexanchiformes) based on CT scanning. *American Museum Novitates* 3429: 1–52.
- Maisey, J.G. 2005. Braincase of the Upper Devonian shark *Cladodoides wildungensis* (Chondrichthyes, Elasmobranchii), with observations on the braincase in early chondrichthyans. *Bulletin of the American Museum of Natural History* 288: 1–103.
- Maisey, J.G. 2007. The braincase in Paleozoic symmoriiform and cladoselachian sharks. *Bulletin of the American Museum of Natural History* 307: 1–122.
- Maisey, J.G. 2008. The postorbital palatoquadrate articulation in elasmobranchs. *Journal of Morphology* 269: 1022–1040.
- Maisey, J.G., and M.E. Anderson. 2001. A primitive chondrichthyan braincase from the early Devonian of South Africa. *Journal of Vertebrate Paleontology* 21 (4): 702–713.
- Maisey, J.G., and M.R. de Carvalho. 1997. A new look at old sharks. *Nature* 385: 779–780.
- Maisey, J.G., G.J.P. Naylor, and D.J. Ward. 2004. Mesozoic elasmobranchs, neoselachian phylogeny and the rise of modern elasmobranch diversity. In G. Arratia and A. Tintori (editors), *Mesozoic fishes 3: systematics, paleoenvironments and biodiversity*: 17–56. Munchen: Verlag Dr. Friedrich Pfeil.
- Marinelli, W., and A. Strenger. 1959. *Vergleichende Anatomie und Morphologie der Wirbeltiere 3: Squalus acanthias*. Vienna: Franz Deuticke, 308 pp.
- Northcutt, R.G., and W.E. Bemis. 1993. Cranial nerves of the coelacanth *Latimeria chalumnae* (Osteichthyes: Sarcopterygii: Actinistia) and comparisons with other craniata. *Brain, Behavior and Evolution* 42 (suppl. 1): 1–76.
- Owen, R. 1846. *Lectures on the comparative anatomy and physiology of the vertebrate animals, delivered at the Royal College of Surgeons of England in 1844 and 1846. Part I: Fishes*. London: Longman, 8 vols. (308 pp.)
- Poplin, C., and A. de Ricqlès. 1970. A technique of serial sectioning for the study of undecalcified fossils. *Curator* 13: 7–20.
- Rage, J.-C., and H. Cappetta. 2002. Vertebrates from the Cenomanian, and the geological age of the Draa Ubari fauna (Libya). *Annales de Paléontologie* 88: 79–84.
- Schaeffer, B. 1981. The xenacanth shark neurocranium, with comments on elasmobranch monophyly. *Bulletin of the American Museum of Natural History* 169 (1): 1–66.
- Shirai, S. 1992. *Squalean phylogeny*. Sapporo: Hokkaido University Press, 151 pp.
- Stensiö, E.A. 1927. *The Devonian and Downtonian vertebrates of Spitsbergen. 1. Family Cephalaspidae*. *Skrifter om Svalbard og Ishavet* 12: 1–391.
- Vullo, R., D. Néraudeau, and B. Videt. 2003. Un faciès de type falun dans le Cénomannien basal de Charente-Maritime (France). *Annales de Paléontologie* 89: 171–189.
- Vullo, R., D. Néraudeau, R. Allain, and H. Cappetta. 2005. Un nouveau gisement à microrestes de vertébrés continentaux et littoraux dans le Cénomannien inférieur de Fouras (Charente-Maritime, Sud-Ouest de la France). *Comptes Rendus Palevol* 4: 95–107.
- Werner, C. 1989. Die elasmobranchier-fauna des Gebel Dist Member der Bahariya Formation (Obercenoman) der Oase Bahariya, Ägypten. *Palaeo Ichthyologica* 5: 5–112.
- Werner, C. 1994. Die kontinentale Wirbeltierfauna aus der unteren Oberkreide des Sudan (Wadi Milk Formation). *Berliner Geowissenschaftliche Abhandlungen E (B. Krebs-Festschrift)* 13: 221–249.
- Williams, M.E. 1998. A new specimen of *Tamiobatis vetustus* (Chondrichthyes, Ctenacanthoidea) from the late Devonian Cleveland Shale of

- Ohio. *Journal of Vertebrate Paleontology* 18 (2): 251–260.
- Wischnitzer, S. 1993. Atlas and dissection guide for comparative anatomy. 5th ed. New York: W. H. Freeman, 295 pp.
- Woodward, A.S. 1889. Catalogue of the fossil fishes in the British Museum (Natural History). Part I. London: British Museum (Natural History), xviii + 474 pp.
- Woodward, A.S. 1916. The fossil fishes of the English Wealden and Purbeck formations. Part 1. Palaeontographical Society Monograph (London) 1915: 1–48.
- Young, G.C. 1982. Devonian sharks from southeastern Australia and Antarctica. *Palaeontology* 25: 817–843.
- Young, G.C. 1986. The relationships of placoderm fishes. *Zoological Journal of the Linnean Society* 88: 1–57.
- Zhu, M., X. Yu, and P. Ahlberg. 2001. A primitive sarcopterygian fish with an eyestalk. *Nature* 410: 81–84.